



# Collection of evidence

## **RI.HIP NAVIGATION**

Total Hip Athroplasty

### **+ Evidence in focus**

Developed by Evidence Communications,  
Global Clinical & Medical Affairs

# **Smith+Nephew**

July 2021

# RI.HIP NAVIGATION collection of evidence

## Key studies

## Studies in brief

## Key outcomes

Acetabular  
component  
positioning

Leg length  
and offset

Range  
of motion

Surgical  
time

Survivorship

## Abbreviations

ADL:	Activities of daily living
CAOS:	Computer-assisted orthopaedic surgery
CT:	Computed tomography
DAA:	Direct anterior approach
HHS:	Harris Hip Score
KOOS:	Knee injury and osteoarthritis outcome score
LL:	Leg length
LOS:	Length of stay
NJR:	National Joint Registry
NS:	Not significant
OHS:	Oxford Hip Score
OS:	Offset
PROM:	Patient-reported outcome measure
PT:	Pelvic tilt
ROM:	Range of motion
THA:	Total hip arthroplasty

# The need for navigation-assisted THA

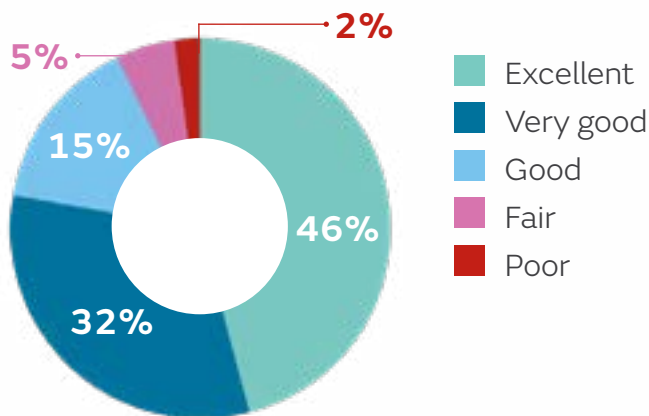
THA is recognised as a highly successful operation, with a high survivorship at 15 years. The world's largest registry - the National Joint Registry (NJR) of England, Wales and Northern Ireland - reports:<sup>1</sup>

**92.47%**  
15-year survivorship



However, with between 7 and 23% of THA patients reporting long-term pain<sup>2</sup> and fewer than 50% patients describing the results of their operations as excellent,<sup>3</sup> there is still room for improvement.

How would you describe the results of your operation?<sup>3</sup>



The most common technical complications associated with THA are:

1. Component malpositioning<sup>4</sup>
2. Postoperative limb length discrepancy<sup>4</sup>

## Up to 50% of acetabular cups may be incorrectly placed<sup>5-7</sup>

Complications of component malpositioning:<sup>8</sup>

- Dislocation
- Hip instability
- Excessive early liner wear
- Impingement
- Shell-liner dissociation
- Leg-length discrepancy
- Limited range of motion (ROM)
- Osteolysis
- Hardware squeaking in ceramic bearing hips

## Change in leg length and offset leads to functional deficiencies<sup>9-11</sup>

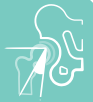- Leg length discrepancy after THA may lead to patient dissatisfaction resulting from back pain and gait disorders<sup>9,10</sup>
- Change in offset affects the biomechanical forces affecting the joint; leg length and offset differences >5mm after THA are associated with altered gait kinematics<sup>11</sup>

## Pelvic tilt (PT): an important consideration for successful component positioning

Lewinnek et al. defined a safe zone to minimise dislocation risk; operative cup inclination of  $40 \pm 10^\circ$  and operative cup anteversion of  $15 \pm 10^\circ$ .<sup>12</sup> Yet, most dislocations occur with an implant initially placed within the Lewinnek safe zone,<sup>13</sup> therefore the ideal cup position for some patients may lie outside this safe zone.<sup>14</sup> With pelvic tilt influencing cup positioning, the position of the pelvis is of high importance during THA surgery<sup>14</sup>

**95% of patients undergoing THA have some degree of anterior or posterior PT, with 16% having >10° tilt<sup>15</sup>**

# Why RI.HIP NAVIGATION?



## Acetabular component positioning

Using RI.HIP NAVIGATION in THA has been shown to reduce outliers and improve acetabular component positioning compared to conventional THA.<sup>16-18</sup>

Significantly improved precision for both inclination and anteversion compared to non-navigated hips<sup>16</sup>

Good correlation between intraoperative RI.HIP NAVIGATION and postoperative CT measurements<sup>17</sup>

Low number of outliers from safe zone target<sup>18</sup>



## Leg length and offset

RI.HIP NAVIGATION allows a more accurate measurement of leg length and offset change compared to the conventional THA<sup>5,19,20</sup>



## Range of motion

RI.HIP NAVIGATION delivers significantly improved impingement-related ROM outcomes compared to conventional THA:

Lower implant-to-implant impingement (p=0.01)<sup>21</sup>

Lower bone-to-bone impingement (p=0.05)<sup>21</sup>

More patients reached ROM boundaries for ADL<sup>22,23</sup>



## Surgical time

Surgical times with RI.HIP NAVIGATION are very similar to conventional THA performed through the posterior approach<sup>24</sup>



## Survivorship

Accurate component positioning using navigation-assisted surgery has been shown to correlate with improved long-term survivorship compared to conventional THA surgery.<sup>25</sup>

Use of navigation-assisted surgery with Smith+Nephew THA implants has been shown to result in:<sup>26</sup>

- Significantly lower 10-year revision rate with computer-guided THA than with conventional THA (1.06 vs 3.88%, p=0.005)
  - Revision risk was 55% lower with computer-guided vs conventional THA (p=0.038)

# POLAR3<sup>◇</sup> Total Hip Solution delivers excellent performance<sup>27</sup>

## POLARSTEM<sup>◇</sup>

cementless stem system

**19 years**

of clinical heritage

**10A\* ODEP rating<sup>28</sup>**



## OXINIUM<sup>◇</sup>

with XLPE

**19 years**

of clinical heritage

In 2005, OXINIUM Technology was the first and only medical device material to receive the prestigious Engineering Achievement Materials Award from ASTM International



## R3<sup>◇</sup>

Acetabular System

**13 years**

of clinical heritage

**10A\* ODEP rating<sup>28</sup>**



### 98% survivorship at 8 years<sup>27†</sup>

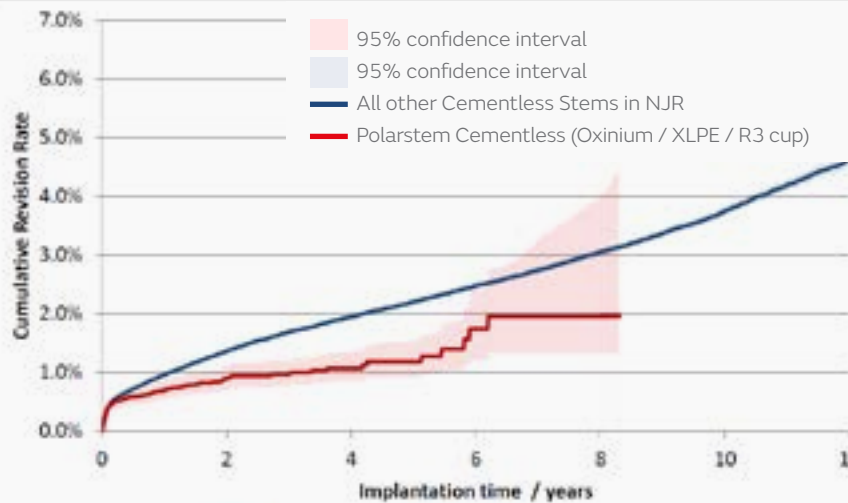


Figure. Incidence of cumulative revision rate of POLAR3 (POLARSTEM, OXINIUM/XLPE, R3) compared to all other cementless stems in NJR, with endpoint as any revision. All reasons for revision, excluding metal-on-metal

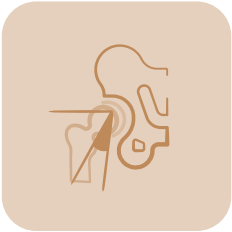
<sup>†</sup>The data used for this analysis was obtained from the NJR Supplier Feedback System. The Healthcare Quality Improvement Partnership ("HQIP") and/or the National Joint Registry ("NJR") take no responsibility for the accuracy, currency, reliability and correctness of any data used or referred to in this report, nor for the accuracy, currency, reliability and correctness of links or references to other information sources and disclaims all warranties in relation to such data, links and references to the maximum extent permitted by legislation.

**35%** ↓

significantly lower revision risk compared to all other cementless stems (p<0.001)<sup>27</sup>



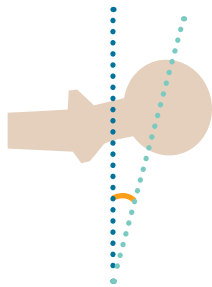
Significantly higher patient satisfaction and better PROMs compared to class average for cementless stems (p<0.001)<sup>27</sup>



## Key outcome

# Acetabular component positioning

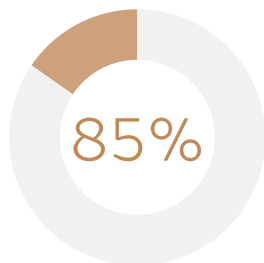
### Navigation versus conventional THA



#### Deviation from desired angle

Navigation has been shown to **significantly reduce the deviation from the planned acetabular anteversion** ( $p=0.0005$ ) and **inclination angle** ( $p<0.0001$ ) compared to conventional THA surgery<sup>27</sup>

---

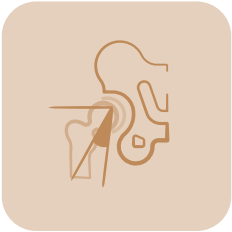


#### Safe/target zone placement

**85% reduction in the odds of outliers** with navigation-assisted THA when compared to conventional THA ( $p<0.0001$ )<sup>27</sup>

---





## Key outcome

### Acetabular component positioning

#### RI.HIP NAVIGATION

#### Using RI.HIP NAVIGATION in THA has been shown to reduce outliers and improve acetabular cup positioning compared to conventional THA

Davis et al. 2015, reported successful safe zone placement for 99.75% of inclination and 97.68% of anteversion angles.<sup>18</sup>

This study also demonstrated that RI.HIP NAVIGATION achieved lower mean error for inclination and anteversion when patients were placed in the lateral decubitus position compared to the more traditional anterior pelvic plane positioning.<sup>18</sup>

High acetabular component position accuracy with RI.HIP NAVIGATION seen in several studies:

**Improved precision for both inclination<sup>16,30</sup> and anteversion compared to non-navigated hips<sup>16</sup>**

Accuracy of RI.HIP NAVIGATION has been confirmed with postoperative CT measurements for both cup inclination and anteversion<sup>17</sup>

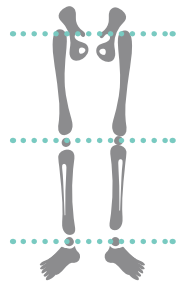




## Key outcome

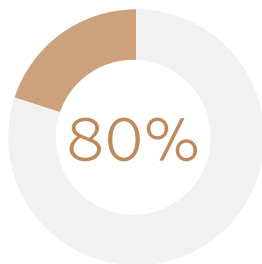
### Leg length and offset

#### Navigation versus conventional THA



Leg length discrepancy was **significantly reduced** with navigation-assisted THA (-1.24mm; p=0.0001)<sup>29</sup>

---

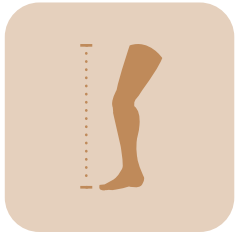


80% (8 out of 10 studies) of identified studies reported that **leg length discrepancies were reduced** with the use of a navigation system<sup>29</sup>

---







## Key outcome

### Leg length and offset

#### RI.HIP NAVIGATION

#### Using RI.HIP NAVIGATION in THA has been shown to achieve consistent leg length restoration

The validity and accuracy of RI.HIP NAVIGATION was confirmed in a comparison with X-ray based measurements:

- Mean difference between the navigation measurements and the expected values was  $0.00 \pm 1.16$ mm (leg length) and  $-0.20 \pm 1.21$ mm (femoral offset)<sup>4</sup>

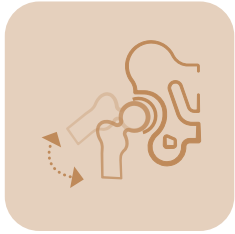
A further study compared accuracy of intraoperative leg length and offset measurements with RI.HIP NAVIGATION and pelvic radiographs:

- No significant differences were seen between mean measurements or both leg length ( $p=0.51$ ) and offset ( $p=0.072$ )<sup>20</sup>

In a comparison with other navigation systems, RI.HIP NAVIGATION was shown to be as accurate as THS\* ( $p=0.986$ ) and more accurate than Amplivision\* ( $p=0.044$ )<sup>19</sup>

\*THS™ (Praxim, Tronche, France); Amplivision® navigation system (Amplitude Surgical, Valence, France)





## Key outcome

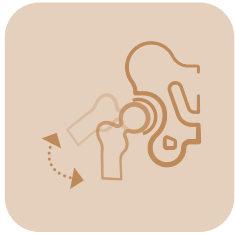### Range of motion

#### Navigation versus conventional THA

**Impingement-related ROM outcomes are significantly improved with navigation-assisted THA, compared to conventional THA:<sup>29</sup>**

- ↓ Less implant-to-implant impingement (p=0.01)
- ↓ Less bone-to-bone impingement (p=0.05)
- ↓ Fewer impingement related complications
- ↑ More patients reached ROM boundaries for ADL





## Key outcome

### Range of motion

#### RI.HIP NAVIGATION

#### **Impingement is associated with reduced ROM, higher risk of dislocation, component wear and patient dissatisfaction<sup>31</sup>**

Higher proportions of patients in the RI.HIP NAVIGATION treatment groups achieved impingement-free ROM within the boundaries for essential ADL than non-navigated patients<sup>22,23</sup>

Impingement severity for implant-to-implant ( $p=0.01$ ) and bone-to-bone impingement ( $p=0.05$ ) was reduced in patients who received surgery with RI.HIP NAVIGATION versus non-navigated surgeries<sup>21</sup>

Intraoperative estimation of ROM by eye may differ by up to  $30^\circ$  compared to measurements with RI.HIP NAVIGATION<sup>31</sup>



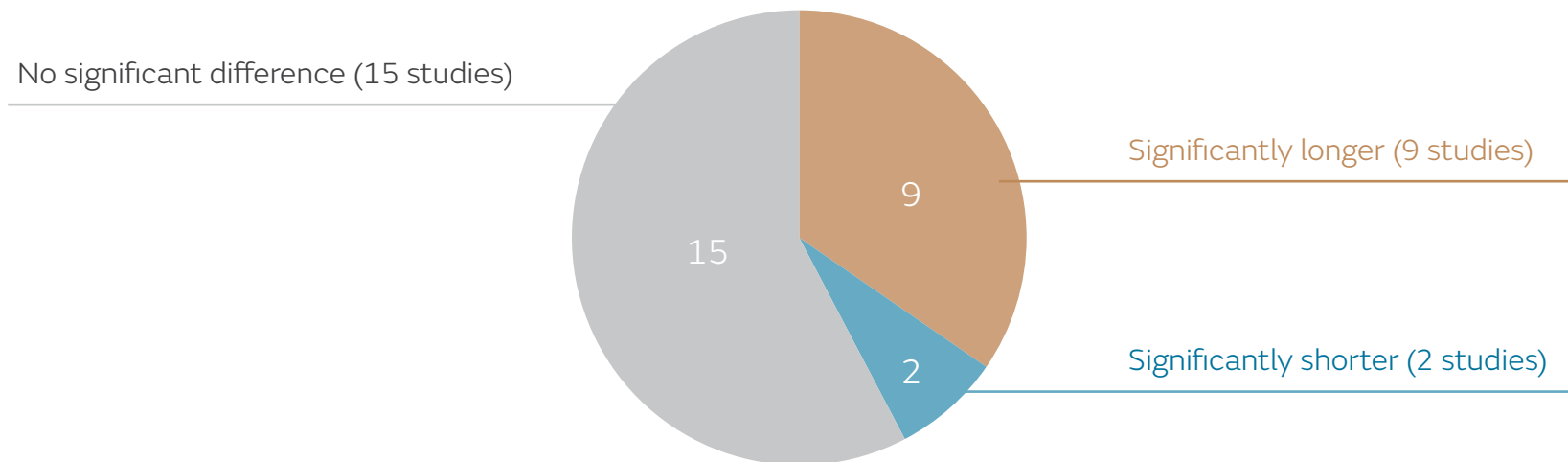


## Key outcome

### Surgical time

#### Navigation versus conventional THA

#### Surgical time for navigation-assisted THA compared to conventional THA<sup>29</sup>





## Key outcome

### Surgical time

#### RI.HIP NAVIGATION

**Simplified registration combined with no patient repositioning leads to reduced surgical time compared to previous models<sup>18,24</sup>**

Surgical times with RI.HIP NAVIGATION are very similar to cases performed through the posterior approach without navigation<sup>24</sup>





## Key outcome Survivorship

### Navigation versus conventional THA

#### Navigation-assisted THA results in high long-term survivorship<sup>25,26,32</sup>

Sugano et al. (2012) investigated whether the short-term achievement of more precise implant placement leads to long-term improvement in survivorship.<sup>25</sup> In their retrospective review of 180 THAs (navigation-assisted THA, n=60; conventional THA, n=120), they showed that navigation-assisted THA resulted in higher cup orientation placement precision (within a target zone) than conventional methods.

In a small study of 60 THAs, Parratte et al. (2016) also demonstrated high long-term survivorship with navigation-assisted THA.<sup>32</sup>

Davis et al. (2021) investigated the effect of computer guidance on the survival of THA implants and on patient satisfaction using the NJR dataset and linked PROMs.<sup>26</sup> All THA surgery was performed using Smith+Nephew implants.



Survivorship

**100%**

navigation-assisted THA  
vs 95.6% conventional THA (p=ns)<sup>25</sup>



Survivorship

**100%**

navigation-assisted THA  
vs 100% conventional THA (p=ns)<sup>32</sup>



Survivorship

**98.94%**

computer-guided THA vs 96.12%  
conventional THA (p=ns)<sup>26</sup>

**55%**

Revision risk



with computer-guided  
vs conventional THA (p=0.038)<sup>26</sup>





## Key study

### Intraoperative validation of navigated limb measurements in THA using a pinless femoral array<sup>4</sup>

Ulivi M, Orlandini L, Pascale W, Consonni O, Sansone V. *J Arthroplasty*. 2014;29:1026–1029

#### Prospective case series:

RI.HIP NAVIGATION (n=60)

#### Surgical approach:

Lateral decubitus position; postero-lateral approach

#### Aim:

Determine accuracy of an imageless navigation system with a minimally-invasive femoral reference array in recording differences in LL and offset compared to X-ray measurements

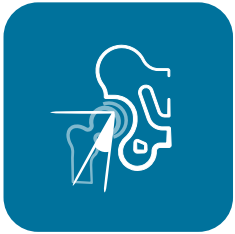#### Results

Mean difference between the intra-operative navigation measurements and the varus valgus corrected values:

- LL;  $0.00 \pm 1.16$ mm (95% CI: -2.27 to 2.28mm)
- Offset;  $-0.20 \pm 1.21$ mm (95% CI: -2.58 to 2.18mm)

#### Conclusion

RI.HIP NAVIGATION is a valid and accurate intraoperative tool for measuring LL and femoral offset



## Key study

A new method of registration in navigated hip arthroplasty without the need to register the anterior pelvic plane<sup>18</sup>

Davis ET, Schubert M, Wegner M, Haimerl M. *J Arthroplasty*. 2015;30:55–60

### Prospective case series:

RI.HIP NAVIGATION (n=48)

### Surgical approach:

Lateral decubitus position; femur first approach

### Aim:

Analyse the accuracy of the epicutaneous anterior pelvic plane (APP) registration technique to the supine and lateral registration technique

### Results

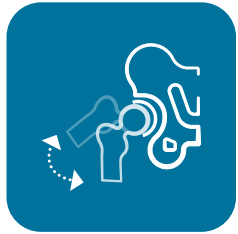	Inclination		Anteversion	
	Deviation to CT scan [°]	Percentage of outliers*	Deviation to CT scan [°]	Percentage of outliers*
Epicutaneous APP registration	-1.8±1.8 (CI: -5.3 to 1.8)	0.00%	-4.8±2.7 (CI: -10.2 to 0.5)	2.98%
New lateral registration	-1.1±3.1 (CI: -7.3 to 5.0)	0.25%	0.9±4.3 (CI: -7.5 to 9.3)	2.32%
Pubic-free supine registration	0.5±2.2 (CI: -3.8 to 4.7)	0.00%	0.9±3.9 (CI: -6.3 to 8.0)	1.20%

\*Outliers are defined in terms of cup orientation compared to conventional technique

### Conclusion

The new lateral registration technique does not require access to the APP and can be performed in a fully prepared patient in the lateral decubitus position, providing accurate and precise acetabular component orientation





## Key study

Impingement-free range of movement, acetabular component cover and early clinical results comparing 'femur-first' navigation and 'conventional' minimally invasive total hip arthroplasty: a randomised controlled trial<sup>23</sup>

Renkawitz T, Weber M, Springorum H, et al. *Bone Joint J.* 2015;97:890–898

### Randomised clinical trial:

RI.HIP NAVIGATION (n=66)

Conventional THA (n=69)

### Aim:

Assess whether RI.HIP NAVIGATION results in a potential increased ROM compared with conventional THA

### Surgical approach:

Lateral decubitus position; femur first approach

### Results

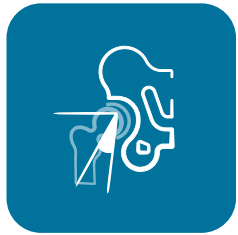Compared to conventional THA, patients in the RI.HIP NAVIGATION group:

- Achieved impingement-free ROM boundaries for essential ADL\*; 84 vs 65% (p=0.016)
- Achieved significantly higher HHS at 6 weeks postoperatively (p=0.01)
- Mean operating time; 71.8 vs 64.1 mins (p<0.001)

\*>110° of flexion, >30° of extension >45° of external rotation at 0° of hip flexion, >30° of internal rotation at 90° of hip flexion, >50° of abduction, >30° of adduction

### Conclusion

RI.HIP NAVIGATION improves the theoretical or potential ROM before potential prosthetic impingement



## Key study

Visual intraoperative estimation of range of motion is misleading in minimally invasive total hip arthroplasty<sup>31</sup>

Woerner M, Weber M, Sendtner E, et al. *Arch Orthop Trauma Surg.* 2016;136:1015–1020

### Retrospective case series:

RI.HIP NAVIGATION (n=60)

### Surgical approach:

Lateral decubitus position; minimally invasive anterolateral approach

### Aim:

Investigate intraoperative accuracy of visual estimation of ROM by eye compared to RI.HIP NAVIGATION

### Results

	Mean difference between RI.HIP NAVIGATION measurements and visual intraoperative estimations (SD)	Occurrence of a difference >10° between RI.HIP NAVIGATION and visual intraoperative estimations (%)
Flexion	5.6° (±10.9)	37%
Extension	-0.4° (±10.7)	35%
Abduction	8.7° (±9.0)	52%
External rotation	5.9° (±18.3)	43%
Internal rotation	-5.8° (±12.1)	43%

### Conclusion

Simple visual estimation of ROM during minimally invasive THA is susceptible to error and differs up to 30° compared to measurements with RI.HIP NAVIGATION



## Key study

A new system of computer-assisted navigation leading to reduction in operating time in uncemented total hip replacement in a matched population<sup>24</sup>

Chaudhry FA, Ismail SZ, Davis ET. *Eur J Orthop Surg Traumatol.* 2018;28:645–648

### Retrospective, observational study:

RI.HIP NAVIGATION (n=256\*)

### Surgical approach:

Lateral decubitus position; posterior approach

### Aim:

Determine whether there is a significant difference in operative time between the traditional anterior pelvic plane registration and the new lateral position registration

### Results

Mean operating time:

- Traditional APP registration (n=128): 65.79 minutes (range, 40–98)
- New lateral position registration (n=128): 50.87 minutes (range, 33–74)
- Operative time declines with lateral position registration (0.19min per month; p=0.019)

Cup positioning accuracy was comparable between groups

### Conclusion

The new lateral registration technique significantly reduces operative time compared to the traditional APP registration technique. A continued improvement in the operative time is seen with the lateral position registration as the surgeon becomes more proficient in the technique

\*Compared BrainLab versions 2.1–5.1 (APP registration; n=128) with BrainLab version 6.0 (lateral position registration; n=128)



## Key study

Computer guided total hip arthroplasty is associated with a reduced risk of revision and increased patient satisfaction. An analysis of a single manufacturer acetabular components from the National Joint Registry of England, Wales, Northern Ireland and the Isle of Man<sup>26</sup>

**Davis ET, McKinney KD, Kamali A, Kuljaca S, Pagkalos J. Poster presented at: World Arthroplasty Congress (WAC) Virtual Meeting; April 22–24, 2021**

### Registry data analysis:

Computer-guided THA (n=871)

Conventional THA (n=41,683)

### Surgical implants:

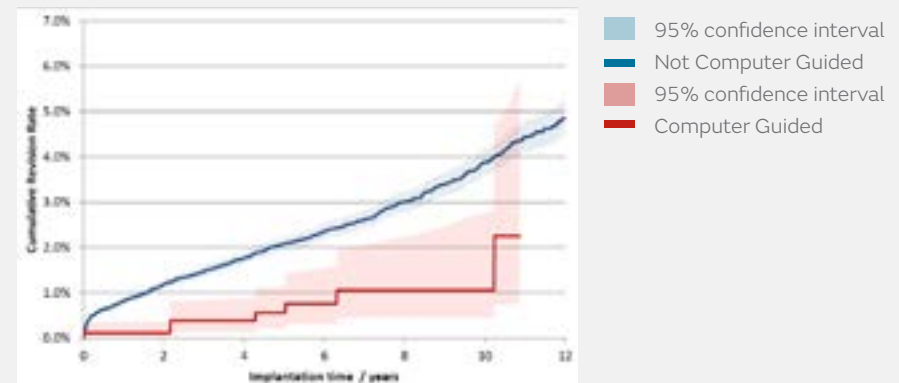
Smith+Nephew cementless acetabular components

### Results

- Significantly lower 10-year revision rate with computer-guided THA than with conventional THA (1.06 vs 3.88%, p=0.005)
- Revision risk was 55% lower with computer-guided versus conventional THA (p=0.038)
- Satisfaction rate was significantly higher in the computer-guided group compared to conventional THA (p=0.003)

### Aim:

Analyse the effect of computer guidance on the survival of THA implants and on patient satisfaction using the NJR<sup>†</sup> dataset and linked PROMs



### Conclusion

Use of computer-guided surgery with Smith+Nephew implants was associated with a significant reduction in the risk of long-term revision and significantly improved patient satisfaction compared to conventional THA surgery.

<sup>†</sup>The data used for this analysis was obtained from the NJR Supplier Feedback System. The Healthcare Quality Improvement Partnership ("HQIP") and/or the National Joint Registry ("NJR") take no responsibility for the accuracy, currency, reliability and correctness of any data used or referred to in this report, nor for the accuracy, currency, reliability and correctness of links or references to other information sources and disclaims all warranties in relation to such data, links and references to the maximum extent permitted by legislation.

## Studies in brief



Sendtner  
et al.  
2011<sup>20</sup>

Accuracy of acetabular cup placement in computer-assisted, minimally-invasive THR in a lateral decubitus position<sup>20</sup>  
Sendtner E, Schuster T, Wörner M, Kalteis T, Grifka J, Renkawitz T. *Int Orthop.* 2011;**35**:809–815

### Prospective, randomised clinical trial:

RI.HIP NAVIGATION (n=32)

Freehand (n=30)

### Surgical approach:

Lateral decubitus position; approach not specified

### Aim:

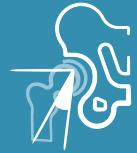Assess accuracy of acetabular component placement using RI.HIP NAVIGATION compared to freehand technique with a minimally invasive surgical approach

### Results

Parameter measured		Navigation	Freehand	p-value
Inclination	Mean	42.3°	37.9°	0.002
	Range	32.7–50.6°	25.6–50.2°	
	SD	3.8°	6.3°	0.007
Anteversion	Mean	24.5°	23.8°	0.739
	Range	12.0–33.3°	5.6–46.9°	
	SD	6.0°	10.1°	0.024

Target acetabular component position for all patients was 40–45° inclination and 15–20° anteversion (operative definition)

## Studies in brief



Rizzi  
et al.  
2012<sup>17</sup>

Acetabular cup positioning using computer navigation through direct anterior approach<sup>16</sup>  
Rizzi L, Gotti V, Castelli CC. *Hip Int.* 2012;22:431–432

### Retrospective, observational study:

Prospective case series (RI.HIP NAVIGATION, n=20); no comparator

### Surgical approach:

Supine position; DAA

### Aim:

Compare intraoperative RI.HIP NAVIGATION measurements with postoperative CT scan

### Results

Good correlation of the intraoperative RI.HIP NAVIGATION and postoperative CT measurements:

	Mean cup inclination (range)	Mean version (range)
RI.HIP NAVIGATION	44.4° (39–48°)	15.8° (10–21°)
CT scan	44.9° (39–53°)	15.6° (10–22°)

## Studies in brief



Renkawitz  
et al.  
2014<sup>20</sup>

Femoral pinless length and offset measurements during computer-assisted, minimally invasive total hip arthroplasty<sup>20</sup>  
Renkawitz T, Sendtner E, Schuster T, Weber M, Grifka J, Woerner M. *J Arthroplasty*. 2014;29:1021–1025

### Prospective case series:

RI.HIP NAVIGATION (n=50)

### Surgical approach:

Lateral decubitus position; minimally invasive modified Smith Petersen approach

### Aim:

Determine accuracy of measuring LL and OS change intraoperatively with a novel femoral pinless navigation system (RI.HIP NAVIGATION) by comparison with postoperative radiographs

### Results

There was substantial agreement between the postoperative radiographic results and the intraoperative results from the femoral pinless navigation system with mean differences  $\geq 1.0\text{mm}$ :

- Differences of the mean leg length changes: 0.35mm (p=0.51)
- Differences of the mean offset changes: -1.0mm (p=0.072)

## Studies in brief



Clavé  
et al.  
2015<sup>19</sup>

Comparison of the reliability of leg length and offset data generated by three hip replacement CAOS systems using EOS™ imaging<sup>19</sup>

Clavé A, Fazilleau F, Cheval D, Williams T, Lefèvre C, Stindel E. *Orthop Traumatol Surg Res.* 2015;101:647–653

### Retrospective observational study:

RI.HIP NAVIGATION (n=42)    Amplivision\* (n=23)    THS\* (n=41)

### Surgical approach:

Lateral decubitus position; posterolateral approach

### Aim:

Compare reliability of leg length (LL) and offset (OS) data generated by three navigation assisted THA systems

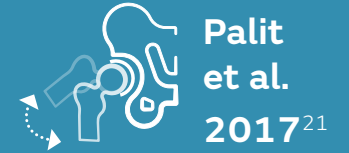### Results

- RI.HIP NAVIGATION demonstrated comparable accuracy to THS ( $p=0.986$ ) and higher accuracy than Amplivision ( $p=0.044$ ) for leg length
- Ability to achieve a maximum error of  $\pm 2\text{mm}$  was not significantly different between groups ( $p=0.61$ )
- All systems had error values  $< 1\text{mm}$

\*THS™ (Praxim, Tronche, France); Amplivision® navigation system (Amplitude Surgical, Valence, France)



## Studies in brief



Femur first navigation can reduce impingement severity compared to traditional free hand total hip arthroplasty<sup>21</sup>

Palit A, Williams MA, Turley GA, Renkawitz T, Weber M. *Sci Rep.* 2017;7:7238

### Retrospective, observational study:

RI.HIP NAVIGATION (n=65)

Conventional (n=56)

### Surgical approach:

Lateral decubitus position; femur first approach

### Aim:

Investigate if RI.HIP NAVIGATION is more effective than conventional THA at providing impingement-free ROM

### Results

- Implant-to-implant impingement severity significantly decreased with RI.HIP NAVIGATION compared to conventional THA: 1.6 vs 2.6% (p=0.01)
- Bone-to-bone impingement severity significantly decreased with RI.HIP NAVIGATION compared to conventional THA: 3.7 vs 5.0% (p=0.05)

## References

1. National Joint Registry for England, Wales and Northern Ireland: 17th Annual Report. Available at: <http://www.njrcentre.org.uk>. Accessed 15 February 2021.
2. Beswick AD, Wylde V, Gooberman-Hill R, Blom A, Dieppe P. What proportion of patients report long-term pain after total hip or knee replacement for osteoarthritis? A systematic review of prospective studies in unselected patients. *BMJ Open*. 2012;2(1):e000435.
3. NHS Digital. Finalised patient reported outcome measures (PROMs) in England for hip and knee replacement procedures (April 2019 to March 2020). Available at: <http://digital.nhs.uk/pubs/promsapr19mar20fin>. Accessed 18 May 2021.
4. Ulivi M, Orlandini L, Pascale W, Consonni O, Sansone V. Intraoperative validation of navigated limb measurements in THA using a pinless femoral array. *J Arthroplasty*. 2014;29:1026–1029.
5. Callanan MC, Jarrett B, Bragdon CR, et al. The John Charnley Award: risk factors for cup malpositioning: quality improvement through a joint registry at a tertiary hospital. *Clin Orthop Relat Res*. 2011;469:319–329.
6. Bosker BH, Verheyen CC, Horstmann WG, Tulp NJ. Poor accuracy of freehand cup positioning during total hip arthroplasty. *Arch Orthop Trauma Surg*. 2007;127:375–379.
7. Dorr LD, Malik A, Wan Z, Long WT, Harris M. Precision and bias of imageless computer navigation and surgeon estimates for acetabular component position. *Clin Orthop Relat Res*. 2007;465:92–99.
8. Feng JE, Anoushiravani AA, Eftekhary N, Wiznia D, Schwarzkopf R, Vigdorich JM. Techniques for optimizing acetabular component positioning in total hip arthroplasty: defining a patient-specific functional safe zone. *JBJS Rev*. 2019;7:e5.
9. Maloney WJ, Keeney JA. Leg length discrepancy after total hip arthroplasty. *J Arthroplasty*. 2004;19:108–110.
10. Parvizi J, Sharkey PF, Bissett GA, Rothman RH, Hozack WJ. Surgical treatment of limb-length discrepancy following total hip arthroplasty. *J Bone Joint Surg Am*. 2003;85:2310–2317.
11. Renkawitz T, Weber T, Dullien S, et al. Leg length and offset differences above 5mm after total hip arthroplasty are associated with altered gait kinematics. *Gait Posture*. 2016;49:196–201.
12. Lewinnek GE, Lewis JL, Tarr R, Compere CL, Zimmerman JR. Dislocations after total hip-replacement arthroplasties. *J Bone Joint Surg Am*. 1978;60:217–220.
13. Abdel MP, von Roth P, Jennings MT, Hanssen AD, Pagnano MW. What safe zone? The vast majority of dislocated THAs are within the lewinnek safe zone for acetabular component position. *Clin Orthop Relat Res*. 2016;474:386–391.
14. Schwarz T, Benditz A, Springorum HR, et al. Assessment of pelvic tilt in anteroposterior radiographs by means of tilt ratios. *Arch Orthop Trauma Surg*. 2018;138:1045–1052.
15. Zhu J, Wan Z, Dorr LD. Quantification of pelvic tilt in total hip arthroplasty. *Clin Orthop Relat Res*. 2010;468:571–575.
16. Sendtner E, Schuster T, Worner M, Kalteis T, Grifka J, Renkawitz T. Accuracy of acetabular cup placement in computer-assisted, minimally-invasive THR in a lateral decubitus position. *Int Orthop*. 2011;35:809–815.
17. Rizzi L, Gotti V, Castelli CC. Acetabular cup positioning using computer navigation through direct anterior approach. *Hip Int*. 2012;22:431–432.
18. Davis ET, Schubert M, Wegner M, Haimerl M. A new method of registration in navigated hip arthroplasty without the need to register the anterior pelvic plane. *J Arthroplasty*. 2015;30:55–60.
19. Clave A, Fazilleau F, Cheval D, Williams T, Lefevre C, Stindel E. Comparison of the reliability of leg length and offset data generated by three hip replacement CAOS systems using EOS™ imaging. *Orthop Traumatol Surg Res*. 2015;101:647–653.
20. Renkawitz T, Sendtner E, Schuster T, Weber M, Grifka J, Woerner M. Femoral pinless length and offset measurements during computer-assisted, minimally invasive total hip arthroplasty. *J Arthroplasty*. 2014;29:1021–1025.
21. Palit A, Williams MA, Turley GA, Renkawitz T, Weber M. Femur first navigation can reduce impingement severity compared to traditional free hand total hip arthroplasty. *Sci Rep*. 2017;7:7238.
22. Weber M, Woerner ML, Sendtner E, Vollner F, Grifka J, Renkawitz TF. Even the intraoperative knowledge of femoral stem anteversion cannot prevent impingement in total hip arthroplasty. *J Arthroplasty*. 2016;31(11):2514–2519.
23. Renkawitz T, Weber M, Springorum H, et al. Impingement-free range of movement, acetabular component cover and early clinical results comparing 'femur-first' navigation and 'conventional' minimally invasive total hip arthroplasty: a randomised controlled trial. *Bone Joint J*. 2015;97:890–898.
24. Chaudhry FA, Ismail SZ, Davis ET. A new system of computer-assisted navigation leading to reduction in operating time in uncemented total hip replacement in a matched population. *Eur J Orthop Surg Traumatol*. 2018;28:645–648.
25. Sugano N, Takao M, Sakai T, Nishii T, Miki H. Does CT-Based navigation improve the long-term survival in ceramic-on-ceramic THA? *Clinical Orthopaedics and Related Research*. 2012;470:3054–3059.
26. Davis ET, McKinney KD, Kamali A, Kuljaca S, Pagkalos J. Computer guided total hip arthroplasty is associated with a reduced risk of revision and increased patient satisfaction. An analysis of a single manufacturer acetabular components from the National Joint Registry of England, Wales, Northern Ireland and the Isle of Man. Poster presented at: World Arthroplasty Congress (WAC) Virtual Meeting: April 22–24, 2021.
27. National Joint Registry for England, Wales and Northern Ireland: POLARSTEM Cementless (Oxinium/XLPE/R3 cup) implant summary report. 14 August 2019. Data on file. [Link [http://bit.ly/POLAR3\\_Aug2019](http://bit.ly/POLAR3_Aug2019)]
28. Orthopaedic Data Evaluation Panel (ODEP). Available at <http://www.odep.org.uk>. Accessed 17 May 2021.
29. Smith+Nephew 2020. Navigation assisted THA vs conventional THA: frequently reported study outcomes and key differences in outcomes between the techniques – EA\_RECON\_NAVIO\_004\_v2.
30. Keshmiri A, Schroter C, Weber M, Craiovan B, Grifka J, Renkawitz T. No difference in clinical outcome, bone density and polyethylene wear 5–7 years after standard navigated vs conventional cement free total hip arthroplasty. *Arch Orthop Trauma Surg*. 2015;135(5):723–730.
31. Woerner M, Weber M, Sendtner E, et al. Visual intraoperative estimation of range of motion is misleading in minimally invasive total hip arthroplasty. *Arch Orthop Trauma Surg*. 2016;136:1015–1020.
32. Paratte S, Ollivier M, Lunebourg A, Flecher X, Argenson JN. No Benefit after THA performed with computer-assisted cup placement: 10-year results of a randomized controlled study. *Clin Orthop Relat Res*. 2016;474:2085–2093.

For detailed product information, including indications for use, contraindications, precautions and warnings, please consult the product's applicable Instructions for Use (IFU) prior to use.

Smith & Nephew Pty Ltd  
Australia  
T +61 2 9857 3999  
F +61 2 9857 3900

[smith-nephew.com/australia](http://smith-nephew.com/australia)

Smith & Nephew Ltd  
New Zealand  
T +64 9 820 2840  
F +64 9 820 2841

[smith-nephew.com/new-zealand](http://smith-nephew.com/new-zealand)

♦Trademark of Smith+Nephew  
All trademarks acknowledged  
©July 2021 Smith & Nephew  
29575-anz V2 0721

**Smith+Nephew**