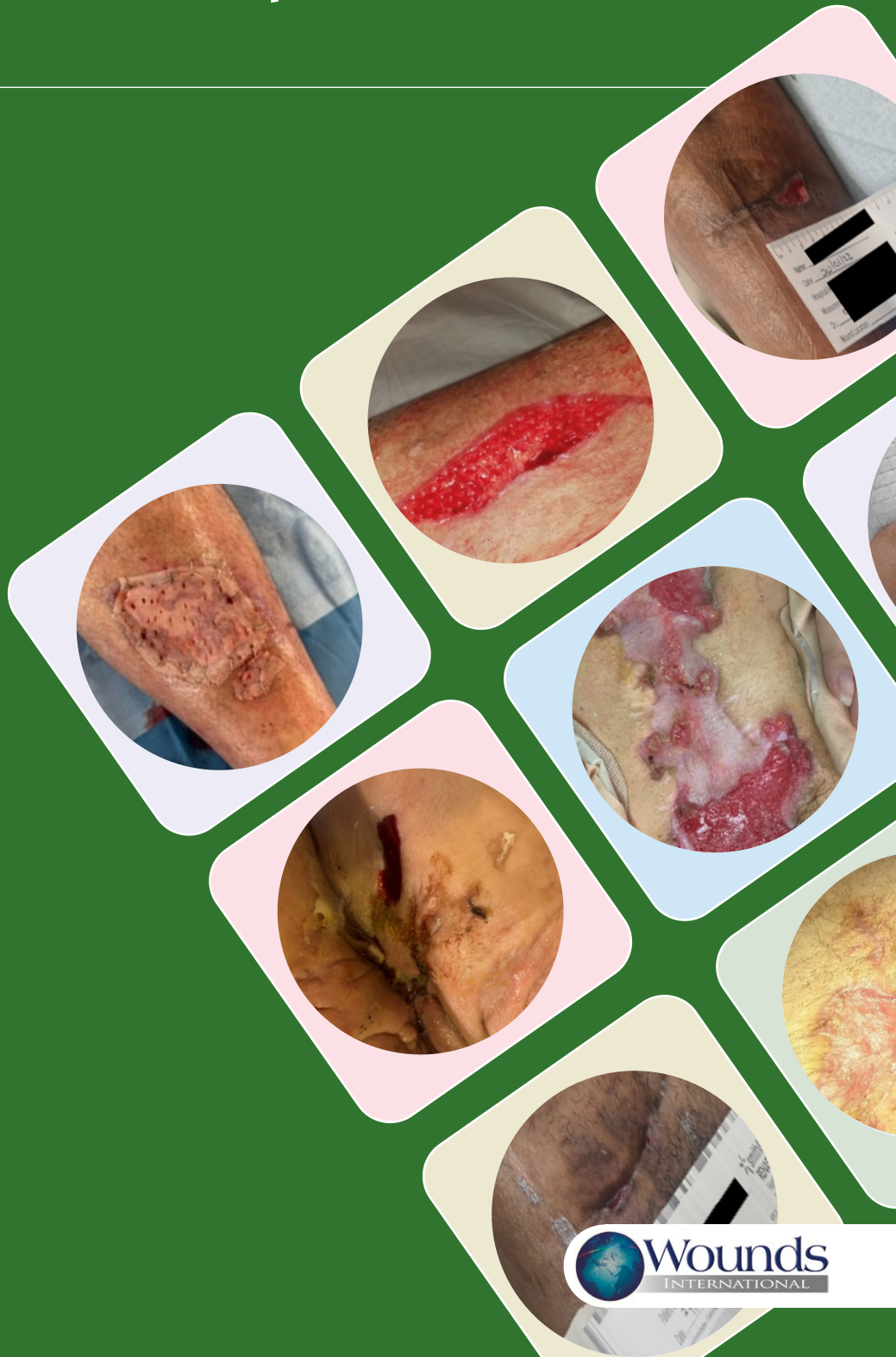

INTERNATIONAL  
**CASE REPORTS**

# Europe, the Middle East and Africa; The OneNPWT clinical decision tree for open wounds

CASE REPORT SERIES 2023



**Published by**

Wounds International  
A division of Omniamed Communications Ltd  
108 Cannon Street  
London EC4N 6EU, UK  
Tel: +44 (0)20 3735 8244  
Email: [info@omniamed.com](mailto:info@omniamed.com)  
[www.woundsinternational.com](http://www.woundsinternational.com)



© Wounds International, 2023

**Suggested citation**

Wounds International (2023) *Case series: Europe, the Middle East and Africa; the OneNPWT clinical decision tree for open wounds*. Wounds International, London, UK

Free download available from:  
[www.woundsinternational.com](http://www.woundsinternational.com)

All rights reserved ©2023. No reproduction, copy or transmission of this publication may be made without written permission.

No paragraph of this publication may be reproduced, copied or transmitted save with written permission or in accordance with the provisions of the Copyright, Designs and Patents Act 1988 or under the terms of any license permitting limited copying issued by the Copyright Licensing Agency, 90 Tottenham Court Road, London, W1P 0LP.

Supported by an educational grant from  
Smith+Nephew.

The views expressed in this publication are those of the authors and do not necessarily reflect those of Smith+Nephew.

**EXPERT PANEL**

**Tomasz Banasiewicz**, Professor and Head of Chair and Head of Department of General, Endocrine Surgery and Gastrointestinal Oncology, Poznan University of Medical Sciences, Poznan, Poland

**Kevin Adams**, Senior Specialist, Plastic, Reconstructive & Maxillo-Facial Surgery, University of Cape Town, Cape Town, South Africa

**Ethel Andrews**, South African Burn Society Past President, Wound Specialist, Witwatersrand Department of Nursing Education, Life Brenthurst Clinic, Netcare Mulbarton Hospital, Johannesburg, South Africa

**Ardian Karakushi**, Orthopaedic and Trauma Surgeon, Royal Medical Hospital, Pristina, Kosovo

**Angelos Karatzias**, Plastic Surgeon, Nicosia, Cyprus

**Caroline Payne**, Consultant, Plastic Surgery, Royal London Hospital, United Kingdom

## FOREWORD

Chronic non-healing wounds present a substantial economic and epidemiological burden on healthcare systems across Europe, the Middle East and Africa (Gupta et al, 2021). Evidence-based recommendations are required to guide clinical decisions regarding negative pressure wound therapy (NPWT) systems and to drive clinical, operational, and financial efficiencies for healthcare providers.

The OneNPWT clinical decision tree is a clinical decision-making tool to help simplify and optimise NPWT provision, and to help guide the selection of RENASYS™ Negative Pressure Wound Therapy System (RENASYS™ tNPWT) or PICO™ Single Use Negative Pressure Wound Therapy System (PICO™ sNPWT). Prompt selection of sNPWT has been shown to quicken patient discharge, improve patient satisfaction, alleviate workloads associated with system maintenance, and reduce healthcare costs (Hurd et al, 2021).

An international panel of clinicians from Cyprus, Kosovo, Poland, South Africa and the United Kingdom experienced in wound care and NPWT use was convened. Specialties of the panellists included nursing, dermatology, orthopaedic surgery, gastrointestinal surgical oncology, and aesthetic and reconstructive plastic surgery. The panel aimed to review the clinical, operational, and financial challenges of using either traditional NPWT (tNPWT) or single-use NPWT (sNPWT), and to validate the potential of the OneNPWT clinical decision tree as an evidence-based decision-making tool in their practice. During the discussion, a facilitator posed questions to the clinicians about the OneNPWT clinical decision tree, including its usefulness for clinical practice, barriers to its adoption, whether they would implement the decision tree in their practice, and suggestions for improvement.

This document provides an overview of the panel's feedback based on their clinical experience of using the OneNPWT decision tree in practice, with the cases summarised below.

## INTRODUCTION

Negative pressure wound therapy (NPWT) is considered a gold standard for the treatment of acute and chronic open wounds (Apelqvist et al, 2017). By creating mechanical forces, single-use NPWT (sNPWT) provides negative pressure to the surface of the wound and for treatment across a wider zone, including the periwound (Brownhill, 2019). NPWT has shown benefits in providing a physical barrier to external contamination (Smith+Nephew, 2020), facilitating moist wound healing (Hudson et al, 2015; Smith+Nephew, 2018; Kirsner et al, 2019; Smith+Nephew, 2019), and promoting angiogenesis (Lalezari et al, 2017). NPWT has also been shown to reduce excess wound exudate, tissue oedema, wound volume, and dressing change frequency while increasing granulation tissue formation, blood perfusion, wound edge contraction, and wound bed stimulation (Dowsett, 2017; Seidel et al, 2020).

The most common modalities of NPWT available worldwide are traditional NPWT (tNPWT) and sNPWT (Table 1). Both types are complementary, and patients can be moved from one type of NPWT device to another as their treatment progresses (WUWHS, 2019). The switch to sNPWT is often triggered when the wound size and exudate level decrease (Banasiewicz et al, 2019; WUWHS, 2019). If patients are being switched between NPWT devices, wound and patient factors, such as patient quality of life, should be considered (Banasiewicz et al, 2019).

Previously, advanced therapies including NPWT were viewed as expensive; however, there is emerging evidence to suggest that NPWT integration into existing care pathways enhances patient outcomes by improving wound healing rates, reducing clinical time, and preventing hospital admission/readmission (Hampton et al, 2015; Dowsett et al, 2017; Nherera et al, 2017; Tanaydin et al, 2018; Kirsner et al, 2019). Furthermore, newer sNPWT devices are more accessible in the community due to smaller, discrete, and more easy-to-use interfaces.

**Table 1. Traditional and single-use NPWT (Apelqvist et al, 2017; Banasiewicz et al, 2019; Hurd et al, 2021)**

| Traditional NPWT (tNPWT)   | Single use NPWT (sNPWT)   |
|--|---|
| Multi-patient use  | Single-patient use and disposed of following treatment                                |
| Fluid is drawn into a canister via tubing  | Fluid is handled through evaporation from the outer layer of the dressing             |
| Uses wound filler to distribute negative pressure (commonly gauze or foam, but others are available) | Wound filler is optional to distribute negative pressure*                             |
| Canister for fluid collection  | Some devices use a small canister and some use a dressing to manage fluid and exudate |
| Adjustable pressure with continuous and intermittent modes of operation                              | Pressure is applied continuously and is not usually adjustable                        |
| Often powered by a mains electricity source  | Often battery powered   |
| Tends to be used for inpatients  | Tends to be used for outpatients (and inpatients in the case of closed incisions)     |

\*Recommended for treating open wounds that are 0.5cm to 2cm in depth. Wounds greater than 0.5cm (1/4in) in depth are likely to require a foam or gauze NPWT filler to ensure adequate treatment of all the wound surfaces. Wounds greater than 2cm (3/4in) in depth must be treated with the use of a filler along with a single-use negative pressure wound therapy (sNPWT) to ensure adequate contact with the wound.

### CLINICAL, OPERATIONAL, AND FINANCIAL CHALLENGES OF TRADITIONAL NPWT

tNPWT can be both complex and time- and resource-intensive with clinical, operational, and financial obstacles limiting its use (Table 2).

**Table 2. Clinical, operational, and financial challenges hindering tNPWT uptake (Sen et al, 2009; Fracalvieri et al, 2012; Cray, 2017; Sen, 2019; Guest et al, 2020; Kirsner et al, 2020; Kirsner and Hurd, 2020; Janssen et al, 2021; Hurd et al, 2021)**

| Clinical   | Operational   | Financial   |
|--|---|---|
| Treatment-related pain and reduced quality of life   | Complex decision-making which impacts on clinicians' confidence in using NPWT                                 | Rising demand for NPWT as the incidence of chronic wounds is expected to rise       |
| Psychological implications (e.g. lower self-esteem, dependence on family/friends, treatment anxiety) | NPWT is time- and resource-intensive (fleet management of devices can add 5 hours of extra workload per week) | Hidden costs (e.g. lost NPWT systems, system maintenance, ad hoc rentals)           |
| Limited patient mobility due to variations in device size and electric requirements                  | Added paperwork complicates the discharge process   | Complex discharge process (e.g. paperwork, reimbursement, prolonged hospital stays) |
| Disparity in practice and knowledge of NPWT and wounds between clinicians                            | Ongoing training requirements of healthcare professionals using NPWT  | Not easily accessible in low-income countries                                       |

### ONENPWT CLINICAL DECISION TREE

The OneNPWT clinical decision tree (Figure 1) is a decision-making tool designed to support clinicians in choosing between RENASYS™ Traditional Negative Pressure Wound Therapy System (RENASYS™ tNPWT) and PICO™ Single Use Negative Pressure Wound Therapy System (PICO™ sNPWT) as a first-line delivery system (Figure 2). The decision tree provides guidance on when to use RENASYS™ tNPWT and PICO™ sNPWT to help manage acute and chronic open wounds based on wound size and depth, volume of exudate, and management capacity of the delivery system.

Despite international or standardised guidelines and recommendations, healthcare professionals choose NPWT treatment on a case-by-case basis driven by protocols which vary between hospitals and healthcare organisations (Hurd et al, 2021). This can lead to inconsistencies and variability in wound assessment, care and management, which can impact negatively on patient outcomes and quality of life (WUWHS, 2020).

Important parameters in clinical decision-making involving NPWT are wound size, volume of exudate in 24 hours, density of exudate, location of the wound, care setting, infection presence, condition of the surrounding skin, and patient preferences (WUWHS, 2019). Clinicians would benefit from clear recommendations on pressure settings for different wound sites, dressing change frequency, when to step across from RENASYS™

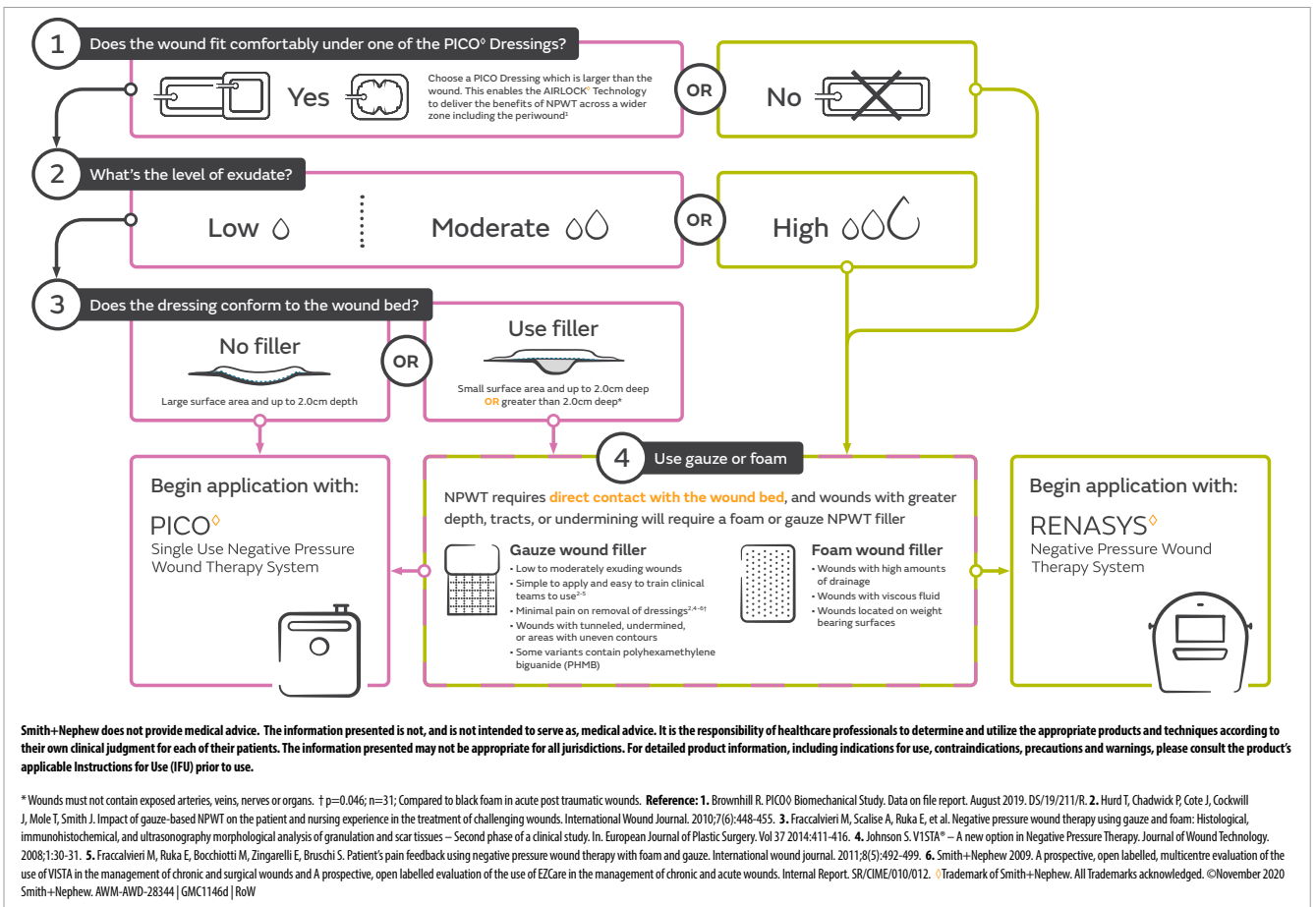


Figure 1. The OneNPWT clinical decision tree for open wounds. ©All rights reserved. Figure 1 belongs to Smith+Nephew.

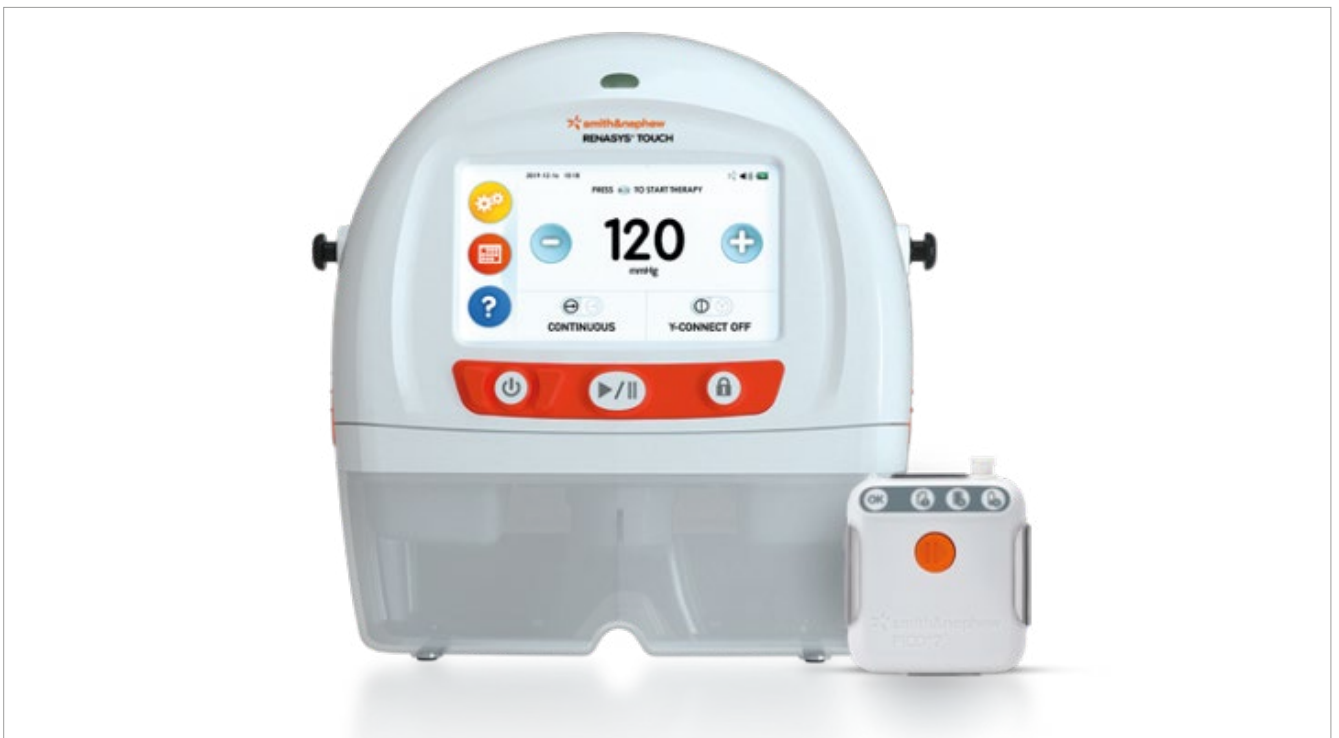

Figure 2. RENASYS™ Negative Pressure Wound Therapy System and PICO™ Single Use Negative Pressure Wound Therapy. ©All rights reserved. Figure 2 belongs to Smith+Nephew.

tNPWT to PICO™ sNPWT, and when to terminate the treatment (Banasiewicz, 2019). It should be stressed that NPWT is not the ideal solution for all wound healing issues and a holistic approach is needed, whereby choice of NPWT should be individualised to the patient. The OneNPWT clinical decision tree has potential to aid clinicians in choosing RENASYS™ tNPWT or PICO™ sNPWT for first-line use to manage wounds and provides a solution to address clinical, operational, and financial inefficiencies, including reductions in length of hospital stay and improvements to the patient discharge process.

### EXPERT PANEL FEEDBACK ON THE ONENPWT CLINICAL DECISION TREE

The decision tree was used within local protocol to prompt initiation of either RENASYS™ tNPWT or PICO™ sNPWT. Each patient was monitored and reviewed until NPWT was ceased or until full wound closure (Table 3). The characteristics of the wound, including wound size, condition of the wound bed, and wound progression were documented at the dressing change.

| Case study | Clinician            | Country      | Wound type                                  | Page |
|------------|----------------------|--------------|---|------|
| 1          | Ethel Andrews        | South Africa | Left popliteal fossa wound                  | 10   |
| 2          | Ethel Andrews        | South Africa | Infected myomectomy wound                   | 12   |
| 3          | Ardian Karakushi     | Kosovo       | Open left forearm fracture                  | 14   |
| 4          | Angelos Karatzias    | Cyprus       | Laceration of the tibia                     | 16   |
| 5          | Tomasz Banasiewicz   | Poland       | Lower abdomen wound                         | 18   |
| 6          | Tomasz Banasiewicz   | Poland       | Perianal fistula wound                      | 20   |
| 7          | Tomasz Banasiewicz   | Poland       | Hidradenitis suppurativa and septic lesions | 22   |
| 8          | Caroline Payne et al | UK           | Infected haematoma                          | 24   |
| 9          | Caroline Payne et al | UK           | Infected wound following a breast reduction | 26   |

### CLINICAL PERSPECTIVE

#### Experience of using the OneNPWT clinical decision tree in practice

Overall, clinicians reported that using the OneNPWT decision tree helped them in their decision-making regarding NPWT which they use for a number of clinical scenarios, including to reduce the risk of complications (e.g. infections and morbidity), prepare wounds for healing by secondary intention and facilitate wound closure. It was revealed during the discussion that PICO™ sNPWT may also help improve scar appearance as a secondary benefit. The clinicians expressed that the decision tree was useful in justifying their clinical decisions and that standardisation would lead to better patient compliance. It was revealed during the discussion that clinicians felt level of exudate (low, moderate and high) of the OneNPWT decision tree was a subjective measurement; however, the clinicians felt confident in their decision-making and no further concerns were raised. The OneNPWT decision tree was also useful to clinicians in deciding when to switch between delivery systems, particularly when stepping across from RENASYS™ tNPWT to PICO™ sNPWT.

It was reassuring to most that the OneNPWT decision tree closely reflected the assessments they were already conducting in practice, and incorporated the clinical indicators they felt were important, including level of exudate, to decide on which NPWT system to use. One of the most important reflections from the group was that evidence-based care relies on patient involvement, and that psychosocial factors and patient preferences should be included in the decision tree for improved patient compliance and satisfaction. The group noted that patients are more inclined to accept NPWT once they have been educated about their condition, coached on what to do and whom to contact if they encounter a problem, and involved in setting goals and expectations of treatment. The importance of gaining consent from patients before commencing treatment as well as sharing information to improve compliance was discussed. Clinicians stressed that disregarding patient preference can be a barrier to acceptability and compliance. The importance of choosing dressings and wound care products that are most appropriate for the individual patient and their wound was discussed. It was agreed that clinicians should explain to patients that a short round of RENASYS™ tNPWT treatment could then be stepped across to PICO™ sNPWT, which will reassure patients that they will not be 'stuck' on RENASYS™ tNPWT indefinitely. It was agreed that explaining to patients why a treatment option has been chosen based on standardised recommendations, such as the OneNPWT decision tree, helps patients to better understand their health conditions and treatment plans.

A further view raised was the possibility of additionally creating a simple prompt to determine whether PICO™ sNPWT would be an optimal first-line modality as a starting point e.g. 'can I use PICO™ sNPWT for this patient

or not?'. The use of clinical pathways with PICO™ sNPWT, providing guidance on whether PICO™ sNPWT would be optimal for first-line use, has shown reductions in wound size, time to heal, and complete wound closure (Hurd, 2013; Dowsett et al, 2017; Kirsner et al, 2019; Patel et al, 2019; Kirsner and Hurd, 2020; Hurd and Gilchrist, 2020); however, these pathways only focused on wound-related characteristics. The panel agreed that guidance on PICO™ sNPWT initiation as a starting point, as well as considering patient preference and convenience, would improve the OneNPWT clinical decision tree as an evidence-based tool in practice. Based on the feedback, a note will be added to the EMEA OneNPWT decision tree stating that 'patient factors should be considered in combination with the OneNPWT clinical decision tree, including pain, size of pump, convenience and likelihood of compliance'.

#### **Are clinicians aware that they can use PICO™ sNPWT with fillers?**

The disparity in practice and knowledge of NPWT and wounds between clinicians pose a significant clinical challenge that hinders uptake of the treatment (Kirsner and Hurd, 2020). It became apparent during the discussion that not all the clinicians were aware of the OneNPWT clinical decision tree before the case study evaluation and one clinician was unaware that it is possible to use a filler with PICO™ sNPWT. All the clinicians had experience of using fillers with tNPWT, especially in the case of deeper wounds; however, views were varied on whether the clinicians preferred to use foam- or gauze-based NPWT as a first-line modality. Consequently, the OneNPWT decision tree helped them decide between gauze and foam filler. It has been suggested that foam fillers are more absorbent while gauze is more malleable and conformable (Jeffery, 2014); however, foam- and gauze-based fillers deliver negative pressure to the wound bed in equal measure (Malmsjö et al, 2009; Tuncel et al, 2013).

### **OPERATIONAL PERSPECTIVE**

#### **How are decisions regarding wound care and NPWT made in clinical practice?**

An operational challenge of using NPWT is the complex decision-making involved in deciding which device to use and when, which affects clinicians' confidence in applying RENASYS™ tNPWT and/or PICO™ sNPWT (Cray, 2017; Kirsner and Hurd, 2020). While some of the clinicians reported that decisions in their practices are made independently by clinicians and informed by financial aspects, others stated that decisions on how to deal with a wound across their units are based on their clinical expertise only. As stated above, all agreed that patient preference should be considered, when clinically appropriate, as part of the decision-making process and that the inclusion of this aspect in the OneNPWT clinical decision tree may help reduce the complexity of decision-making. Using RENASYS™ tNPWT more judiciously and optimising the use of PICO™ sNPWT may also simplify some of the training and administration aspects associated with the operational challenges of NPWT.

#### **What are the main criteria for clinicians when transferring patients to using PICO™ sNPWT?**

A key consideration for switching between NPWT systems is based on the condition of the wound and need for NPWT. There were several reasons described when stepping across from RENASYS™ tNPWT to PICO™ sNPWT, including reduction in exudate volume and wound depth, facilitating discharge home, improving patient acceptance, providing patients with greater mobility, reducing pain and improving healing rates. A minority of the clinicians' first choice of NPWT is RENASYS™ tNPWT followed by conventional dressings, mentioning that they prefer to use PICO™ sNPWT as a last resort e.g. when fluid handling capacity exceeds standard dressing capability. Other clinicians reported the opposite and stated that they prefer to use PICO™ sNPWT as first-line treatment. Following recalculation of exudation after 24 hours, the patient can be moved to RENASYS™ tNPWT if the wound dressing is fully saturated.

Advantages of PICO™ sNPWT over RENASYS™ tNPWT that were stated included ease of use, patient acceptability, high availability, and low cost. It was agreed that PICO™ sNPWT dressings are gentler to the surrounding skin than RENASYS™ tNPWT, they enable patients to mobilise earlier following surgery, and many of the group had experience of patients using PICO™ sNPWT at home, under the guidance of a clinician.

### **FINANCIAL PERSPECTIVE**

#### **Are there any barriers to adopting the OneNPWT in clinical practice?**

Several clinicians spoke of financial challenges as a significant barrier to the uptake of NPWT and adoption of the OneNPWT clinical decision tree in practice. Other barriers discussed were large wounds, the time it takes to change dressings, and a lack of education/confidence. In countries where treatment is paid for by the patient, financial challenges threaten the delivery of high quality care. Treatment strategies could be denied due to issues with reimbursement or the patient's insurance plan. Since reimbursement protocols vary between countries, standardised and evidence-based tools, such as the OneNPWT clinical decision tree, could support and inform treatment decisions among healthcare providers.

## OPERATIONAL OUTCOMES

### Clinician-related factors

Five clinicians were asked to provide operational feedback on the OneNPWT decision tree in practice. Levels of satisfaction and ease of learning how to operate and troubleshoot devices were very high, with all clinicians scoring the OneNPWT decision tree as 'excellent' (Table 4).

When asked about time spent applying and changing dressings, clinicians reported that it took between 15 and 45 minutes to change NPWT dressings. Importantly, the amount of time varied depending on the condition of the wound. Clinicians reported spending a longer time changing RENASYS™ tNPWT dressings than PICO™ sNPWT dressings.

|                                 | Excellent   | Good | Fair | Poor | Very poor |
|---------------------------------|---|------|------|------|-----------|
| Satisfaction level              | 9   | 0    | 0    | 0    | 0         |
| Ease of learning how to operate | 9   | 0    | 0    | 0    | 0         |
| Comments                        | The decision tree assisted me in making the decision to implement sNPWT, which I would not have done in my clinic previously. |      |      |      |           |

### Patient-related factors

Patient-related outcomes including satisfaction, compliance and ability to resume activities of daily living were reported (Table 5). Patient satisfaction with NPWT and its treatment outcomes was reported by clinicians as 'excellent' (66.7%) and 'good' (33.3%). Compliance with treatment was 'excellent' or 'good' in most cases except in one case study where patient compliance with RENASYS™ tNPWT was reported as 'very poor'; however, when the patient was transitioned to PICO™ sNPWT, compliance was rated as 'excellent'. Additionally, according to the information included in the case studies, most patients found RENASYS™ tNPWT and PICO™ sNPWT to be comfortable.

|   | Excellent | Good | Fair | Poor | Very poor |
|---|-----------|------|------|------|-----------|
| Patient satisfaction  | 6         | 3    | 0    | 0    | 0         |
| Patient compliance  | 6*        | 3    | 0    | 0    | 1*        |
| Patient ability to resume activities of daily living  | 6*        | 3    | 0    | 1*   | 0         |
| *One clinician rated patient compliance as 'very poor' and 'excellent' for tNPWT™ and PICO™ sNPWT respectively, and patient ability to resume activities as 'poor' and 'excellent' for RENASYS™ tNPWT and PICO™ sNPWT respectively (see case study 1) |           |      |      |      |           |

Patients' ability to resume activities of daily living was mostly reported as 'excellent', especially in the case of PICO™ sNPWT. One clinician scored RENASYS™ tNPWT as 'poor' in this category due to the impact of the bulky system on the patient's mental health; however, after taking the patient's preferences into account and switching to PICO™ sNPWT, the patient's quality of life and wound healing improved. Overall, these results indicate that all patients experienced some level of improvement in their lives when stepping across from RENASYS™ tNPWT to PICO™ sNPWT, including increased mobility and ability to return to activities such as work, improved self-care and fewer contact sessions and clinic visits.

### Economic outcomes

Clinicians stated that the OneNPWT decision tree aided in their decision-making and had a positive impact on reducing prolonged hospital stays, encouraging patient discharge and facilitating review of patients in the community (Table 6). The majority of clinicians agreed that the OneNPWT decision tree provided effective guidance on appropriate treatment selection which had both clinical and cost-effective outcomes.

## CONCLUSION

Overall, clinicians reported that using a standardised approach through the OneNPWT clinical decision tree helped guide them on when to initiate NPWT for acute and chronic wounds, what type of NPWT system to use, and how to transition between RENASYS™ tNPWT and PICO™ sNPWT. Taking into consideration clinical, operational, and financial factors involved in NPWT decision-making, the group agreed that involving patients, by sharing information and setting goals with them is paramount to evidence-based care and should



**Table 6. Economic overview of the OneNPWT decision tree\***

| Economic outcomes   | Comments  |
|---|---|
| Do you have any comments on how the decision tree impacted on discharge and hospital length of stay (LOS) for patients?   | <ul style="list-style-type: none"> <li>Reduced inpatient stay, patient travel costs and facilitated ongoing review of patients as outpatients</li> <li>The decision tree and NPWT are probably the only tools to stimulate wound healing.</li> </ul>  |
| Do you have any comments on the economic impact of using the decision tree? (e.g. cost, LOS/bed days, nursing time)   | <ul style="list-style-type: none"> <li>Reduced overall economic cost to the hospital</li> <li>Reduced nurses' and doctors' time spent with the patient</li> <li>Seal system of the dressings was effective (for up to 7 days in the case of PICO™ sNPWT)</li> <li>Quickened healing with no abscess or infection.</li> </ul>  |
| How does using the decision tree and Smith+Nephew devices compare to alternative NPWT products used?  | <ul style="list-style-type: none"> <li>They are small and easy to manage in the community</li> <li>The decision tree was effective and helpful in guiding on when to transition from RENASYS™ tNPWT to PICO™ sNPWT</li> <li>Previously in my practice, PICO™ sNPWT was only used on suture lines after surgery. If the patient did not meet the criteria for RENASYS™ tNPWT the only option would have been to use conventional dressings.</li> </ul> |
| *The comments and opinions expressed by the clinicians are based on their own experiences, as compared to their previous treatment protocols. The actual economic impact and benefits will depend on several factors, including the patients' particular circumstances. |   |

be included in the OneNPWT decision tree going forward to optimise patient outcomes. As a result of the feedback, a note will be added to the EMEA OneNPWT decision tree to prompt clinicians to consider patient factors in combination with wound-related factors. The following case studies illustrate the experience of using the OneNPWT decision tree in clinical practice to guide decisions relating to NPWT.

**REFERENCES**

Apelqvist J, Willy C, Fagerdahl AM et al (2017) EWMA Document: Negative Pressure Wound Therapy. *J Wound Care* 26: S1-S154

Banasiewicz T, Banky B, Karsenti A et al (2019) Traditional and single-use NPWT: when to use and how to decide on the appropriate use? Recommendations of an expert panel. *Wounds International*

Brownhill R (2019) PICO™ Biomechanical Study. Data on file report. DS/19/211/R

Cray A (2017) Negative pressure wound therapy and nurse education. *Br J Nurs* 26(15): S6-S18

Dowsett C (2017) Breaking the cycle of hard-to-heal wounds: balancing cost and case. *Wounds International*

Dowsett C, Hampton K, Myers D, Styche T (2017) Use of PICO to improve clinical and economic outcomes in hard-to-heal wounds. *Wounds International* 8(2): 52-8

Fracalvieri M, Fierro MT, Salomone M et al (2012) Gauze-based negative pressure wound therapy: a valid method to manage pyoderma gangrenosum. *International Wound Journal* 11: 164-68

Guest JF, Fuller GW, Vowden P (2020) Cohort study evaluating the burden of wounds to the UK's National Health Service in 2017/2018: update from 2012/2013. *BMJ Open* 10(12): e045253

Gupta S, Sagar S, Maheshwari G et al (2021) Chronic wounds: magnitude, socioeconomic burden and consequences. *Wounds Asia*

Hampton J (2015) Providing cost-effective treatment of hard-to-heal wounds in the community through use of NPWT. *Community Wound Care* S14-S20

Hudson DA, Adams KG, Van Huyssteen A et al (2015) Simplified negative pressure wound therapy: clinical evaluation of an ultraportable, no-canister system. *Int Wound J* 12(2): 195-201

Hurd T (2013) Evaluating Cost and Benefits of Innovations in Chronic Wound Care Products and Practices. *Ostomy Wound Manage* S1-S13.

Hurd T, Gilchrist B (2020) Single use negative pressure wound therapy (sNPWT) in the community management of chronic open wounds deeper than 2cm. Paper presented at: Symposium on Advanced Wound Care/Wound Healing Society Meeting; 2020; Abu Dhabi

Hurd T, Kirsner RS, Sancho-Insenser JJ et al (2021) International Consensus Panel Recommendations for the Optimization of Traditional and Single-Use Negative Pressure Wound Therapy in the Treatment of Acute and Chronic Wounds. *Wounds* 33(2): S1-S11

Janssen AHJ, Wegdam JA, de Vries Reilingh TS et al (2021) Which determinants are considered to be important for adherence to Negative Pressure Wound Therapy: A multimethods study. *J Tissue Viability* 30(2): 250-255

Jeffery SL (2014) The use of an antimicrobial primary wound contact layer as liner and filler with NPWT. *J Wound Care* 23(8): S3-14

Kirsner R, Dove C, Reyzelman A, Vayser D, Jaimes H (2019) A Prospective, Randomised, Controlled Clinical Trial on the Efficacy of a single-use Negative Pressure Wound Therapy System, compared to Traditional Negative Pressure Wound Therapy in the Treatment of Chronic Ulcers of the Lower Extremities. *Wound Repair Regen* 27(5): 519-529

Kirsner RS, Delhougne G, Searle RJ (2020) A cost-effectiveness analysis comparing single-use and traditional negative pressure wound therapy to treat chronic venous and diabetic foot ulcers. *Wound Manag Prev* 66(3): 30-38

Kirsner RS, Hurd T (2020) Assessing the Need for Negative Pressure Wound Therapy Utilization Guidelines: An Overview of the Challenges With Providing Optimal Care. *Wounds* 32(12): 328-33

Lalezari S, Lee CJ, Borovikova AA et al (2017) Deconstructing negative pressure wound therapy. *Int Wound J* 14(4): 649-57

Malmström M, Ingemansson R, Martin R, Huddleston E (2009) Negative pressure wound therapy using gauze or open cell polyurethane foam: similar early effects on pressure transduction and tissue contraction in an experimental porcine wound model. *Wound Repair Regen* 17: 200-5

Nherera LM, Trueman P, Karlakki SL (2017) Cost-effectiveness analysis of single-use negative pressure wound therapy dressings (sNPWT) to reduce surgical site complications (SSC) in routine primary hip and knee replacements. *Wound Repair Regen* 25(3): 474-82

Patel A, Delhougne G, Nherera L (2019) Comparison of wound closure in chronic lower extremity ulcers between single use negative pressure wound therapy and traditional negative pressure wound therapy: a real world analysis. Paper presented at: National Wound Conference; 2019; Las Vegas, NV, USA

Seidel D, Diedrich S, Herrle F et al (2020) Negative Pressure Wound Therapy vs Conventional Wound Treatment in Subcutaneous Abdominal Wound Healing Impairment: The SAWHI Randomized Clinical Trial. *JAMA Surg* 155(6): 469-78

Sen CK (2019) Human Wounds and Its Burden: An Updated Compendium of Estimates. *Adv Wound Care (New Rochelle)* 8(2): 39-48

Sen CK, Gordillo GM, Roy S et al (2009) Human skin wounds: a major and snowballing threat to public health and the economy. *Wound Repair Regen* 17(6): 763-71

Smith+Nephew (2018) Summary of routine QA testing on MVP of PICO dressings. Internal Report. DS/18/153/R

Smith+Nephew (2019) Use of Moisture Vapour Permeability\* (MVP) and Moisture Vapour Transmission rate\*\* (MVTR) data to support product claims referring to moist wound healing. Internal Report

Smith+Nephew (2020) Bacterial barrier testing of the PICO Dressing. Internal Report. 2001002

Tanaydin V, Beugels J, Andriessen A et al (2018) Randomized Controlled Study Comparing Disposable Negative-Pressure Wound Therapy with Standard Care in Bilateral Breast Reduction Mammoplasty Evaluating Surgical Site Complications and Scar Quality. *Aesthetic Plast Surg* 42(4): 927-35

Tuncel U, Erkorkmaz Ü, Turan A (2013) Clinical evaluation of gauze-based negative pressure wound therapy in challenging wounds. *Int Wound J* 10(2): 152-8

World Union of Wound Healing Societies (2019) Wound exudate: effective assessment and management. *Wounds International*

World Union of Wound Healing Societies (2020) Optimising wound care through patient engagement. *Wounds International*

## CASE 1: LEFT POPLITEAL FOSSA WOUND

**Author:** Ethel Andrews, South African Burn Society Past President, Wound Specialist, Witwatersrand Department of Nursing Education, Life Brenthurst Clinic, Netcare Mulbarton Hospital, Johannesburg, South Africa

### PATIENT PRESENTATION AND HISTORY

- A 50-year-old female with a large lipoma (10cm x 15cm) on the left popliteal fossa and pyrexia
- History of obesity, diabetes, hypertension, bipolar disorder and heavy tobacco use
- Referred from psychiatric hospital for treatment of a surgical site infection.

### WOUND PRESENTATION

- **Wound size:** 15cm (length) x 2cm (width) x 6cm (depth)
- **Wound bed:** Dehisced areas with inflammation, erythema, oedema
- **Surrounding skin:** Inflamed
- **Consistency and exudate level:** Thick and at high level.

### MANAGEMENT PLAN AND CLINICAL OUTCOMES

**Goal:** Reduce oedema, wound exudate and bacterial load. Improve perfusion to accelerate wound healing.

- **NPWT:** RENASYS™ tNPWT
- **Filler:** Foam filler
- **Wound contact layer:** ACTICOAT™ FLEX 3 Antimicrobial Barrier Dressing
- **Pressure setting:** Continuous at -80mmHg
- **Planned dressing change frequency:** Every 3 days.

As per the OneNPWT decision tree, RENASYS™ tNPWT was introduced as the amount of purulent exudate drained was copious and the wound exceeded PICO™ sNPWT dressing capacity. During the first week of treatment, the negative pressure setting was increased from -80mmHg to -100mmHg on a trial basis, with the patient's agreement. After 7 days with RENASYS™ tNPWT, the patient requested that RENASYS™ tNPWT be discontinued because she felt uneasy and self-conscious carrying the 'bulky' device around the psychiatric hospital.

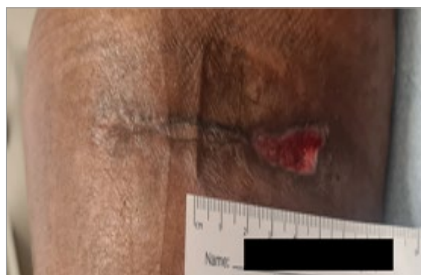As the patient refused further NPWT treatment of any description at this point, ACTICOAT™ FLEX 3 Dressing and compression hosiery was applied to manage infection and oedema, respectively.

After 1.5 weeks of using ACTICOAT™ FLEX 3 Dressings, the patient was urged to try PICO™ sNPWT as the wound had regressed and the surrounding skin had become inflamed. As soon as the patient was stepped across to PICO™ sNPWT, she felt more at ease as the device was smaller and more discrete than RENASYS™ tNPWT.

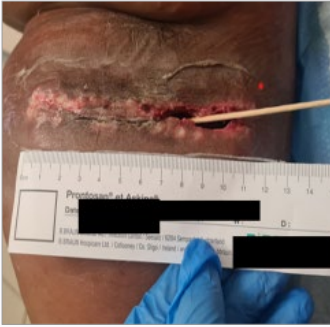Foam filler was discontinued after 2 weeks of PICO™ sNPWT, and as per the OneNPWT decision tree, PICO™ sNPWT was discontinued 4 days later since exudate levels were low and granulation tissue was visible.

### CONCLUSION

After 35 days of treatment, the wound was capable of being managed solely with ACTICOAT™ FLEX Dressings and ALLEVYN™ Wound Dressings.



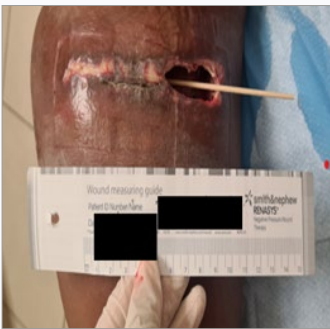**Figure 3.** End of evaluation (4.5 weeks since NPWT discontinuation)



**Week 1: 1 week of treatment with RENASYS™ tNPWT**

**Exudate level and consistency:** High and thin  
**Wound size (length x width x depth):** 13cm suture line; dehiscence opening 5cm x 1.4cm x 5cm  
**Tissue type:** Granulating  
**Surrounding skin:** Dry and flaking.

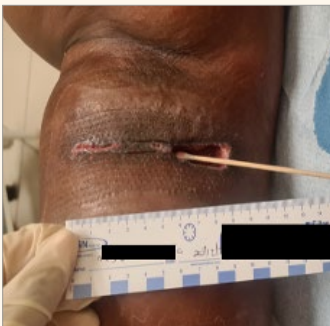**Filler:** Foam filler  
**Wound Contact layer:** ACTICOAT™ FLEX 3 Dressing  
**Pressure setting:** Continuous at -80mmHg and reduced to -100mmHg after a few days  
**Planned dressing change frequency:** Every 3 days  
**Treatment plan:** Discontinue RENASYS™ tNPWT, as requested by the patient, and switch to conventional dressings and compression hosiery.



**Week 2.5: 1.5 weeks of treatment with conventional dressing and compression hosiery**

**Exudate level and consistency:** High and thick  
**Wound size (length x width x depth):** 13cm suture line; dehiscence opening 5cm x 2.2cm x 8cm  
**Tissue type:** Slough and wound margins extending  
**Surrounding skin:** Inflamed and macerated.

**Filler:** Foam filler  
**Wound contact layer:** ACTICOAT™ FLEX 3 Dressing  
**Planned dressing change frequency:** Every 3 days  
**Treatment plan:** The patient was encouraged to switch to PICO™ sNPWT as the wound had regressed.



**Week 5: 2.5 weeks of treatment with PICO™ sNPWT**

**Exudate level and consistency:** Low and thin  
**Wound size (length x width x depth):** 3.5cm x 1cm x 1cm  
**Tissue type:** Viable granulation tissue  
**Surrounding skin:** Healthy.

**Filler:** No longer required  
**Wound contact layer:** No longer required  
**PICO™ sNPWT dressing size:** 15cm x 15cm  
**Planned dressing change frequency:** Every 3 days  
**Treatment plan:** Discontinue PICO™ sNPWT due to patient preference and manage the wound with conventional dressings instead.

## CASE 2: INFECTED MYOMECTOMY WOUND

**Author:** Ethel Andrews, South African Burn Society Past President, Wound Specialist, Witwatersrand Department of Nursing Education, Life Brenthurst Clinic, Netcare Mulbarton Hospital, Johannesburg, South Africa

### PATIENT PRESENTATION AND HISTORY

- A 35-year-old active female with no medical or surgical history and no known allergies
- After suffering from menorrhagia, the patient underwent a myomectomy
- Patient was experiencing severe abdominal pains and presented with two dehisced wounds that were draining copious purulent exudate; she was referred to the wound clinic for further management.

### WOUND PRESENTATION

- **Wound size (length x width x depth):** Wound A: 1cm (length) x 1cm (width) x 2cm (depth); wound B: 3.5cm (length) x 1.5cm (width) x 2cm (depth); 10cm undermining
- **Wound bed:** Inflamed
- **Surrounding skin:** Macerated
- **Consistency and exudate level:** Thick and at high level\*

\*exudate level was deemed suitable for PICO™ sNPWT based on the clinician's experience of treating similar wounds.

### MANAGEMENT PLAN AND CLINICAL OUTCOMES

**Goal:** Reduce oedema, wound exudate and bacterial load, and improve perfusion and ultimately accelerate wound healing.

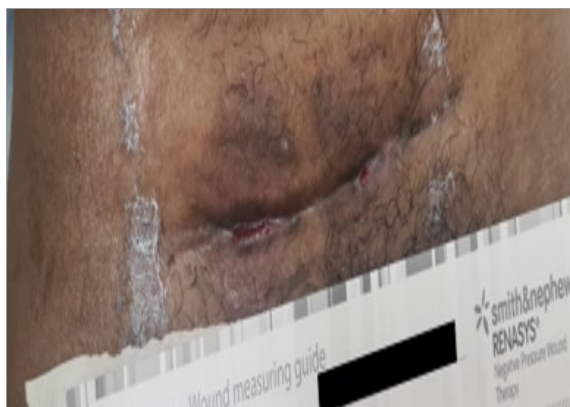
On examination, the wounds were highly exuding. The exudate level was deemed suitable for PICO™ sNPWT, so a PICO™ sNPWT 10cm x 20cm dressing was selected and the wounds were packed with foam filler and ACTICOAT™ FLEX 3 Dressing to address the 10cm undermining surface and the bioburden.

- **NPWT:** PICO™ sNPWT
- **Filler:** Foam filler
- **Wound contact layer:** ACTICOAT™ FLEX 3 Dressing
- **PICO dressing size:** 10cm x 20cm
- **Planned dressing change frequency:** 2-3 times per week.

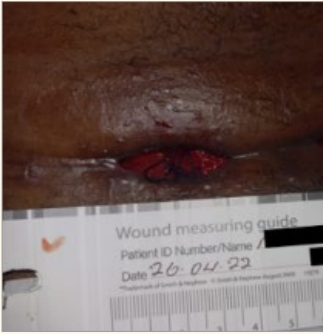Both the foam filler and the ACTICOAT™ FLEX 3 Dressing were discontinued after 1 week of PICO™ sNPWT because the wound was healing well and signs of bioburden had decreased. By the second week, consistency of the exudate had become thinner, thus the frequency of dressing changes was reduced to once per week. PICO™ sNPWT was continued for an additional week as the wound condition had improved and granulation tissue was visible.

### CONCLUSION

As a result of the successful treatment, the wound was dressed with PICO™ sNPWT for 23 days, which is less than the average time of 30-45 days that patients typically receive treatment for similar wounds at the clinician's clinic.



**Figure 4.** End of evaluation (2 weeks since NPWT discontinuation)



### Week 1: 1 week of treatment with PICO™ sNPWT

**Exudate level and consistency:** High and thick (exudate level was deemed suitable for PICO™ sNPWT based on the clinician's experience of treating similar wounds)

**Wound size (length x width x depth):** Wound A: 1cm x 1cm x 2cm; new satellite wound to the lateral side: 0.3cm x 0.3cm x 2cm; wound B: 3.5cm x 1.5cm x 2cm

**Tissue type:** Viable

**Surrounding skin:** Normal.

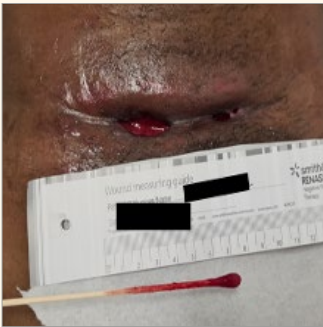**Filler:** Foam filler

**Wound contact layer:** ACTICOAT™ FLEX 3 Dressing

**PICO™ sNPWT dressing size:** 15cm x 15cm

**Planned dressing change frequency:** 2-3 times per week depending on exudate levels

**Treatment plan:** As per the OneNPWT decision tree, continue with PICO™ sNPWT and discontinue use of the ACTICOAT™ FLEX 3 Dressing and foam filler.



### Week 2: 2 weeks with PICO™ sNPWT

**Exudate level and consistency:** High and thin (exudate level was deemed suitable for PICO™ sNPWT based on the clinician's experience of treating similar wounds)

**Wound size (length x width x depth):** Wound A: 1.8cm x 1cm x 1cm; wound B: 3.5cm x 1cm x 1cm

**Tissue type:** Viable

**Surrounding skin:** Normal.

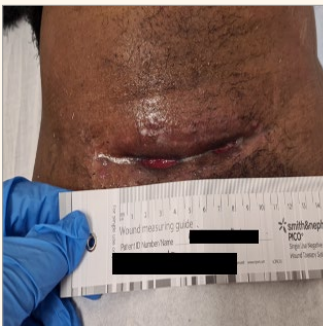**Filler:** Foam filler no longer required

**Wound contact layer:** ACTICOAT™ FLEX 3 Dressing no longer required

**PICO™ sNPWT dressing size:** 15cm x 15cm

**Planned dressing change frequency:** Once per week

**Treatment plan:** As per the OneNPWT decision tree, continue with PICO™ sNPWT.



### Week 3: 3 weeks with PICO™ sNPWT

**Exudate level and consistency:** Low and thin

**Wound size (length x width x depth):** Wound A: 1cm x 0.2cm x 0cm; wound B: 2.8cm x 0.5cm x 0cm

**Tissue type:** Viable

**Surrounding skin:** Healthy.

**Filler:** Foam filler no longer required

**Wound contact layer:** ACTICOAT™ FLEX 3 Dressing no longer required

**PICO™ sNPWT dressing size:** 15cm x 15cm

**Treatment plan:** As per the OneNPWT decision tree, discontinue PICO™ sNPWT as the wound has become granulated and treatment goals have been achieved. Manage wound with ALLEVYN™ Wound Dressings.

## CASE 3: OPEN LEFT FOREARM FRACTURE

*Author:* Ardian Karakushi, Orthopaedic and Trauma Surgeon, Royal Medical Hospital, Pristina, Kosovo

### PATIENT PRESENTATION AND HISTORY

- A 50-year-old male was involved in a motorcycle accident, experiencing multiple trauma and an open fracture in his left forearm and humerus
- The patient underwent an operation where extra focal lesions were removed from the left humerus, and a closed reduction-internal fixation occurred with an intramedullary pin
- Following surgery, he presented with a bacterial wound infection; the wound had become necrotic, more inflamed and more painful.

### WOUND PRESENTATION

- **Wound size:** 25cm (length) x 4cm (width) x 3cm (depth)
- **Wound bed:** Necrotic
- **Surrounding skin:** Inflamed and necrotic
- **Consistency and exudate level:** Thin and at moderate level.

### MANAGEMENT PLAN AND CLINICAL OUTCOMES

Prior to commencing NPWT, the forearm wound was cleaned, debrided and washed with chlorhexidine every day for a week.

Following the OneNPWT decision tree, RENASYS™ tNPWT was initiated under anaesthesia as the patient was experiencing pain. A gauze wound filler was added as the wound had low to moderate drainage.

- **NPWT:** RENASYS™ tNPWT
- **Filler:** Gauze filler
- **Pressure setting:** Continuous at -120mmHg
- **Planned dressing change frequency:** Every 3 days.

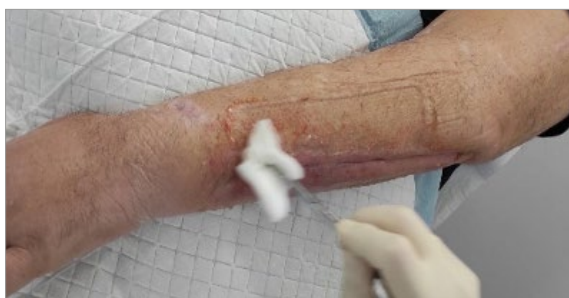The wound was sutured proximally each week in conjunction with NPWT to achieve complete wound closure. With each week of RENASYS™ tNPWT and gauze filler, the wound size was decreasing and progressing well.

After 4 weeks of RENASYS™ tNPWT the use of gauze wound filler was discontinued because the wound was shallow and healthy.

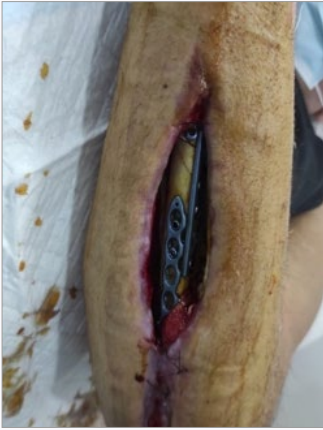Finally, the patient was stepped across to PICO™ 14 sNPWT (that lasts up to 14 days) for an additional 13 weeks until the wound was completely closed.

### CONCLUSION

The combination of RENASYS™ tNPWT, gauze wound filler and PICO™ sNPWT was considered a successful step-across approach in this patient.



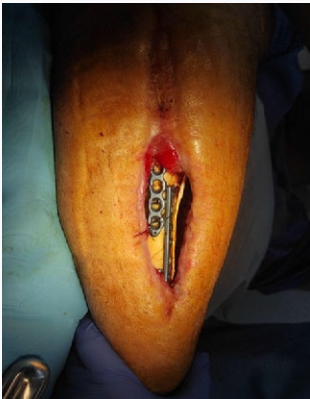**Figure 5.** End of evaluation (NPWT discontinuation) after 4 weeks of RENASYS™ tNPWT and 3 weeks of PICO™ sNPWT



#### Week 2: 2 weeks with RENASYS™ tNPWT

**Exudate level and consistency:** Low and thin  
**Wound size (length x width x depth):** 15cm x 2.5cm x 2cm  
**Tissue type:** Healthy, soft tissue  
**Surrounding skin:** Healthy.

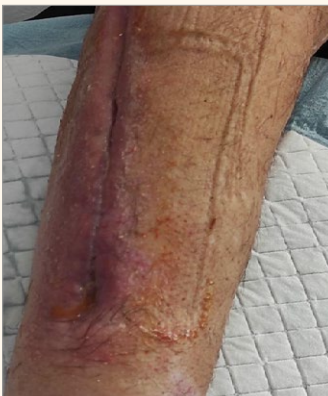**Filler:** Gauze filler  
**Pressure setting:** Continuous at -120mmHg  
**Planned dressing change frequency:** Every 3 days  
**Treatment plan:** As per the OneNPWT decision tree, continue with RENASYS™ tNPWT. The wound was sutured proximally each week to begin drawing the wound edges together.



#### Week 4: 4 weeks with RENASYS™ tNPWT

**Exudate level and consistency:** Low and thin  
**Wound size (length x width x depth):** 5cm x 3cm x 2cm  
**Tissue type:** Healthy  
**Surrounding skin:** Healthy.

**Filler:** Gauze filler  
**Pressure setting:** Continuous at -120mmHg  
**Planned dressing change frequency:** Every 3 days  
**Treatment plan:** As per the OneNPWT decision tree, discontinue RENASYS™ tNPWT and gauze filler, and step across to PICO™ 14 sNPWT (that lasts up to 14 days). Each week, an additional 3cm suturing was performed.



#### Week 13: 9 weeks with PICO™ sNPWT

**Exudate level and consistency:** Low and thin  
**Wound size (length x width x depth):** 0.5cm x 0.2cm x 0.2cm  
**Tissue type:** Healthy  
**Surrounding skin:** Healthy.

**Filler:** No longer required  
**PICO™ sNPWT dressing size:** PICO™ 14 sNPWT  
**Planned dressing change frequency:** Every 14 days  
**Treatment plan:** Suturing was continued to close the wound with the help of PICO™ 14 sNPWT (that lasts up to 14 days). As per the OneNPWT decision tree, PICO™ 14 sNPWT was continued for an additional 4 weeks.

## CASE 4: LACERATION OF THE TIBIA

**Author:** Angelos Karatzias, Plastic Surgeon, Nicosia, Cyprus

### PATIENT PRESENTATION AND HISTORY

- A 62-year-old female with rheumatoid arthritis, osteoporosis, renal failure, hypertension, hyperthyroidism, arrhythmia and hypercholesterolemia
- She presented with a large wound on the anterolateral aspect of her right leg resulting from a traumatic laceration of her tibia.

### WOUND PRESENTATION

- **Wound size:** 13cm (length) x 3.5cm (width) x 2cm (depth)
- **Wound bed:** Traumatic clean cut
- **Surrounding skin:** Thin sensitive skin with underlying large haematoma
- **Consistency and exudate level:** Thick with high levels of exudate and blood.

### MANAGEMENT PLAN AND CLINICAL OUTCOMES

**Goal:** Complete or partial closure of the defect and then to be managed with simple dressings.

As per the OneNPWT decision tree, RENASYS™ tNPWT was initiated at a continuous setting of -120mmHg. Gauze wound filler was used to fill the cavity created by the haematoma, which was resolved after a week of RENASYS™ tNPWT.

- **NPWT:** RENASYS™ tNPWT
- **Filler:** Gauze filler
- **Pressure setting:** Continuous at -120mmHg
- **Planned dressing change frequency:** Every 3 days.

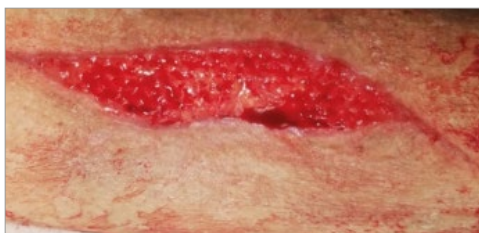Skin fragility persisted after a week of RENASYS™ tNPWT, but exudate consistency had decreased to a moderate level. After using RENASYS™ tNPWT for 2 weeks, the clinician changed from using gauze filler to using foam filler, switched from continuous to variable mode, and decreased the negative pressure setting to -80mmHg, in order to increase granulation of tissue and manage the patient's preferences.

Following the OneNPWT decision tree, RENASYS™ tNPWT and use of foam filler was discontinued after 4 weeks of treatment. To speed up wound healing, the patient was stepped across to PICO™ sNPWT.

After 2 weeks with PICO™ sNPWT, the wound cavity healed and the wound was capable of being managed with conventional dressings to promote epithelialisation tissue growth.

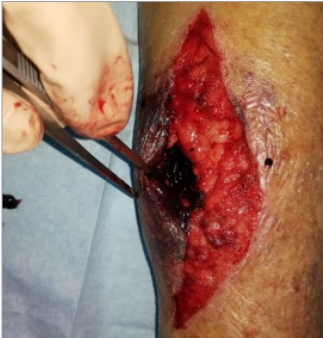### CONCLUSION

With each regular patient visit, the exudate level and wound cavity size decreased, indicating that the use of RENASYS™ tNPWT and PICO™ sNPWT had significantly accelerated the healing process. The patient had comorbidities and an initial poor general condition, but she felt no pain during her treatment with NPWT and was relieved that she didn't need surgery or any other alternative procedures e.g. skin grafts.



**Figure 6.** End of evaluation (NPWT discontinuation following 2 weeks of PICO™ sNPWT)





**Week 1: 1 week of treatment with RENASYS™ tNPWT**

**Exudate level and consistency:** Moderate and thick with blood

**Wound size (length x width x depth):** 11cm x 3cm x 2cm

**Tissue type:** Granulation with haematoma

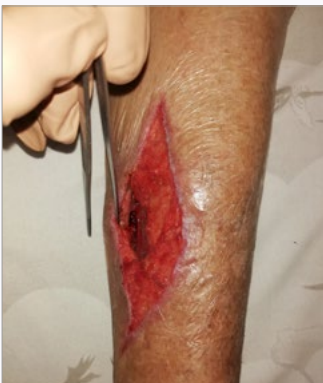**Surrounding skin:** Fragile.

**Filler:** Gauze filler

**Pressure setting:** Continuous at -120mmHg

**Planned dressing change frequency:** Every 3 days

**Treatment plan:** As per the OneNPWT decision tree, continue with RENASYS™ tNPWT but switch to variable setting and decrease negative pressure setting.



**Week 4: 4 weeks with RENASYS™ tNPWT**

**Exudate level and consistency:** Moderate and thin

**Wound size (length x width x depth):** 11cm x 4cm x 1.5cm

**Tissue type:** Granulation

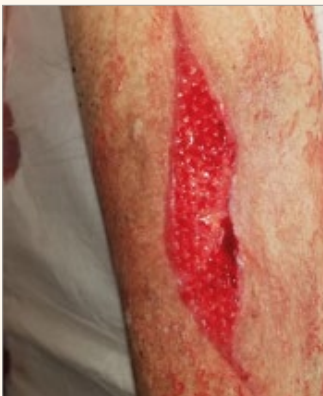**Surrounding skin:** Normal with no issues.

**Filler:** Foam filler

**Pressure setting:** Variable at -80mmHg

**Planned dressing change frequency:** Every 3 days

**Treatment plan:** As per the OneNPWT decision tree, step across to PICO™ sNPWT and discontinue the use of foam filler.



**Week 6: 2 weeks with PICO™ sNPWT**

**Exudate level and consistency:** Low and thin

**Wound size (length x width x depth):** 9cm x 2cm x 0cm

**Tissue type:** Granulation and epithelialisation

**Surrounding skin:** Normal.

**Filler:** Filler no longer required

**Planned dressing change frequency:** Every 3 days

**Treatment plan:** As per the OneNPWT decision tree, discontinue PICO™ sNPWT as the treatment objectives have been met.

## CASE 5: LOWER ABDOMEN WOUND

**Author:** Tomasz Banasiewicz, Professor and Head of Chair and Head of Department of General, Endocrine Surgery and Gastrointestinal Oncology, Poznan University of Medical Sciences, Poznan, Poland

### PATIENT PRESENTATION AND HISTORY

- A 24-year-old female with severe anaemia, malnutrition, cachexia and multiple autoimmune disorders
- Following multiple laparotomies and surgery to treat the appendicitis and ovarian torsion, the wound had dehisced, failed to heal and grown in size with an infection at the surgical site
- She presented with abdominal sepsis and was suspected of having an enteral fistula
- Patient had a high risk of mortality because she refused to have additional surgery, blood transfusions or skin grafts.

### WOUND PRESENTATION

- **Wound size:** 20cm (length) x 8cm (width) x 2cm (depth)
- **Wound bed:** Ischemic and anergic
- **Surrounding skin:** Healthy
- **Consistency and exudate level:** Thin and at low level.

### MANAGEMENT PLAN AND CLINICAL OUTCOMES

The presence of low levels of exudate resulted in the nurse selecting a 15cm x 20cm PICO™ sNPWT dressing with the intention of reducing inflammation and infection and promoting epithelialisation tissue growth.

- **NPWT:** PICO™ sNPWT
- **PICO dressing size:** 15cm x 30cm
- **Planned dressing change frequency:** Every 3 days.

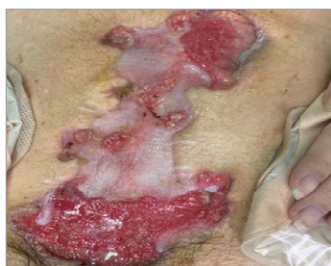After 3 weeks of PICO™ sNPWT, the patient's condition was deteriorating with severe anaemia, and treatment was switched to RENASYS™ tNPWT because the wound was infected, painful and deeper with purulent exudate and subcutaneous pockets. Foam filler and ACTICOAT™ FLEX Dressing were added to the treatment plan to address bioburden and infection-related complications.

The wound's depth and general condition had improved after 4 weeks of treatment with RENASYS™ tNPWT. A week later, it was decided to discontinue RENASYS™ tNPWT after a total of 5 weeks, as the patient's comfort level had increased and there had been no leaks, skin irritation or pain.

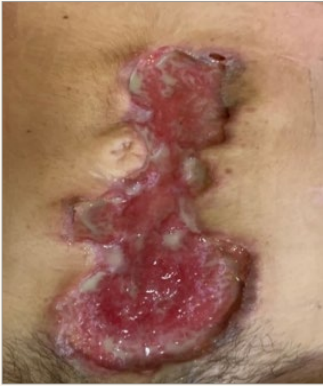It was then decided to initiate PICO™ sNPWT and this regimen was continued for 6 weeks and then discontinued, which was evidenced by an improvement in the patient's general health and wound condition. Exudate and infection had been resolved and there were signs of epithelialisation.

### CONCLUSION

After a total of 14 weeks of treatment with NPWT (3 weeks of PICO™ sNPWT, 5 weeks of RENASYS™ tNPWT, followed by an additional 6 weeks of PICO™ sNPWT), the patient's wound was capable of being managed with ACTICOAT™ FLEX Dressing. With good epithelialisation in progress, a healthy wound bed and no pain, the patient reported that she was very satisfied with the treatment.



**Figure 7.** End of evaluation (NPWT discontinuation following 6 weeks of PICO™ sNPWT)



### Week 3: 3 weeks with PICO™ sNPWT

**Exudate level and consistency:** High and thick (exudate level was deemed suitable for PICO™ sNPWT based on the clinician's experience of treating similar wounds)

**Wound size (length x width x depth):** 22cm x 9cm x 3cm

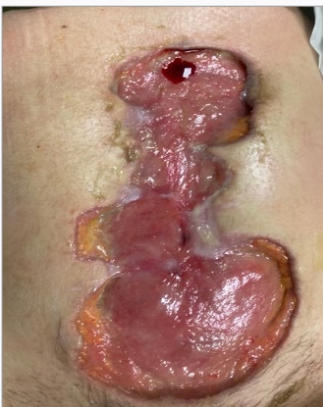**Exudate and tissue type:** Purulent exudation, deeper infection, subcutaneous pockets and fragile granulation tissue

**Surrounding skin:** Healthy.

**PICO™ sNPWT dressing size:** 15cm x 30cm

**Planned dressing change frequency:** Every 3 days

**Treatment plan:** As per the OneNPWT decision tree, switch to RENASYS™ tNPWT with foam filler and ACTICOAT™ FLEX 3 Dressing as a wound remains poor.



### Week 8: 5 weeks with RENASYS™ tNPWT

**Exudate level and consistency:** Low and thin

**Wound size (length x width x depth):** 22cm x 9cm x 2cm

**Tissue type:** Granulation and epithelialisation

**Surrounding skin:** Healthy.

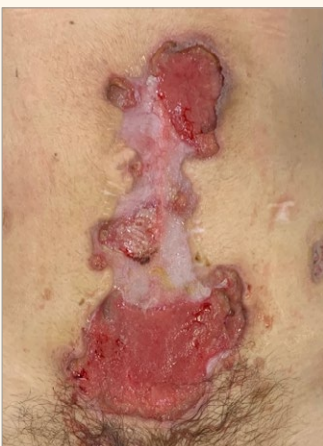**Filler:** Foam filler

**Wound contact layer:** ACTICOAT™ FLEX 3 Dressing

**Pressure setting:** Continuous at -120mmHg

**Planned dressing change frequency:** Every 3 days

**Treatment plan:** As per the OneNPWT decision tree, switch to PICO™ sNPWT as there is good progression of healing and exudate level is low and of thin consistency.



### Week 14: 6 weeks with PICO™ sNPWT

**Exudate level and consistency:** Very low and thin

**Wound size (length x width x depth):** 21cm x 11cm x 1cm

**Tissue type:** Epithelialisation and wound edges are in good condition compared to week 8

**Surrounding skin:** Healthy.

**Filler:** Filler no longer required

**Wound contact layer:** ACTICOAT™ FLEX 3 Dressing

**PICO™ sNPWT dressing size:** 10cm x 15cm

**Planned dressing change frequency:** Every 3 days

**Treatment plan:** As per the OneNPWT decision tree, discontinue PICO™ sNPWT as the wound is in better condition and can be managed using ACTICOAT™ FLEX 3 Dressing.

## CASE 6: PERIANAL FISTULA WOUND

**Author:** Tomasz Banasiewicz, Professor and Head of Chair and Head of Department of General, Endocrine Surgery and Gastrointestinal Oncology, Poznan University of Medical Sciences, Poznan, Poland

### PATIENT PRESENTATION AND HISTORY

- A 32-year-old female with a history of multiple surgical interventions
- Patient presented with complicated perianal fistulae due to Crohn's colitis and recurrent abscesses that required surgical treatment
- Patient refused stoma, steroid and biological therapy.

### WOUND PRESENTATION

- **Wound size:** 20cm (length) x 20cm (width) x 5-8cm (depth)
- **Wound bed:** Inflamed and partially infected
- **Surrounding skin:** Chronic inflammation
- **Consistency and exudate level:** Thick and at high level.

### MANAGEMENT PLAN AND CLINICAL OUTCOMES

**Goal:** To avoid complications (such as surgical site infection and deep gangrene), reduce wound size and dehiscence.

At the time of presentation, the patient avoided sexual activity due to active fistula inflammation and infection; therefore, as per the decision tree, RENASYS™ tNPWT, foam filler and ACTICOAT™ FLEX 3 dressings were initially used to protect the rectum and vaginal wall.

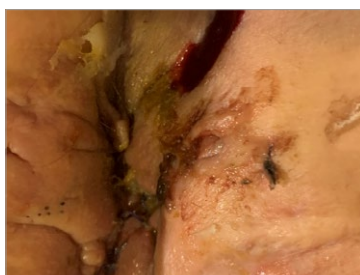- **NPWT:** RENASYS™ tNPWT
- **Filler:** Foam filler
- **Wound contact layer:** ACTICOAT™ FLEX 3 Dressing
- **Pressure setting:** Continuous at -120mmHg
- **Planned dressing change frequency:** Every 4-5 days.

After 14 days with RENASYS™ tNPWT, exudate level and consistency decreased to low and thin, respectively, and the condition of the local tissue quickly improved with the emergence of granulation tissue and a reduction in inflammation.

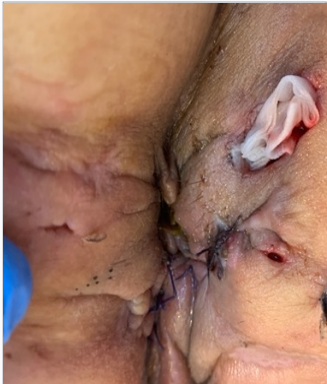The patient was transitioned to PICO™ 7 sNPWT (that lasts up to 7 days) for the final week of NPWT in accordance with the OneNPWT decision tree. The superficial skin cavity of the previously resected fistula tract was still being filled with ACTICOAT™ FLEX 3. Both the patient and the clinician reported that the wound was healing well after one week of PICO™ 7 sNPWT (that lasts up to 7 days), so PICO™ sNPWT was discontinued.

### CONCLUSION

Following 22 days of NPWT therapy (2 weeks of RENASYS™ tNPWT and 1 week of PICO™ sNPWT), surgical site infection was avoided, wound care was managed at home and conventional dressings were deemed sufficient. The patient reported regaining sexual function, less fibrosis, and an overall improvement in quality of life.



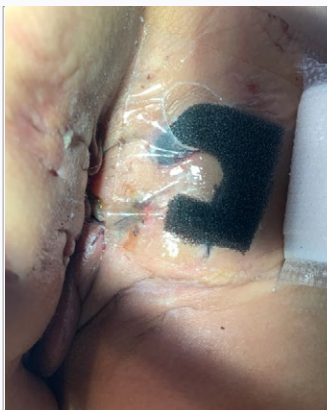**Figure 8.** End of evaluation (NPWT discontinuation after 1 week of PICO™ sNPWT)



**Week 1: 1 week with RENASYS™ tNPWT**

**Exudate level and consistency:** Moderate and thick  
**Wound size (length x width x depth):** 20cm x 15cm x 4cm  
**Tissue type:** Superficially infected, signs of mild inflammation  
**Surrounding skin:** Normal.

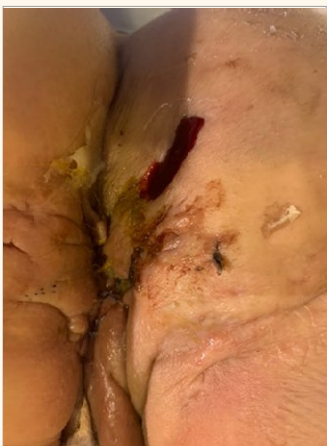**Filler:** Foam filler  
**Wound contact layer:** ACTICOAT™ FLEX 3 Dressing  
**Pressure setting:** Continuous at -120mmHg  
**Planned dressing change frequency:** Every 3 days  
**Treatment plan:** As per the OneNPWT decision tree, continue RENASYS™ tNPWT.



**Week 2: 2 weeks with RENASYS™ tNPWT**

**Exudate level and consistency:** Low and thin  
**Wound size (length x width x depth):** 10cm x 10cm x 2cm  
**Tissue type:** Healing but still inflamed  
**Surrounding skin:** Less inflamed.

**Filler:** Foam filler  
**Wound contact layer:** ACTICOAT™ FLEX 3 Dressing  
**Pressure setting:** Continuous at -120mmHg  
**Planned dressing change frequency:** Every 3 days  
**Treatment plan:** As per the OneNPWT decision tree, switch to PICO™ 7 sNPWT (that lasts up to 7 days).



**Week 3: 1 week with PICO™ sNPWT**

**Exudate level and consistency:** Low and thin  
**Wound size (length x width x depth):** 10cm x 8cm x 1.5-2cm  
**Tissue type:** Fragile but in much better condition  
**Surrounding skin:** Close to normal.

**Filler:** Filler no longer required  
**Wound contact layer:** ACTICOAT™ FLEX 3 Dressing  
**PICO™ sNPWT dressing size:** PICO™ 7 (that lasts up to 7 days); 10cm x 30cm  
**Planned dressing change frequency:** Every 3 days  
**Treatment plan:** As per the OneNPWT decision tree, discontinue PICO™ sNPWT as the wound is in better condition and home care is sufficient.

## CASE 7: HIDRADENITIS SUPPURATIVA AND SEPTIC LESIONS

**Author:** Tomasz Banasiewicz, Professor and Head of Chair and Head of Department of General, Endocrine Surgery and Gastrointestinal Oncology, Poznan University of Medical Sciences, Poznan, Poland

### PATIENT PRESENTATION AND HISTORY

- A 36-year-old male with hidradenitis suppurativa and multiple septic lesions on both buttocks
- Patient required surgical treatment and had a high risk for surgical site infection.

### WOUND PRESENTATION

- **Wound size:** 30cm (length) x 30cm (width) x 5cm (depth)
- **Wound bed:** Difficult to describe infected tissue
- **Surrounding skin:** Infected
- **Consistency and exudate level:** Thick and at high level.

### MANAGEMENT PLAN AND CLINICAL OUTCOMES

**Goal:** Promote wound healing, prevent complications, achieve better functional and aesthetic outcomes and prepare the wound bed for skin grafting.

8 days after the patient's surgery, when the bleeding had subsided and haemostasis had been attained, RENASYS™ tNPWT with foam filler was initiated to support the healing of a complicated septic wound with subcutaneous pockets, irregular wound shapes, and a high level of thick exudate.

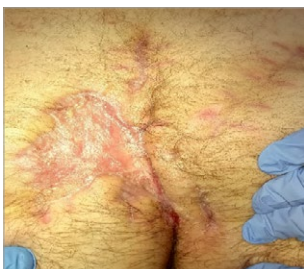- **NPWT:** RENASYS™ tNPWT
- **Filler:** Foam filler
- **Pressure setting:** Continuous at -120mmHg
- **Planned dressing change frequency:** Every 2-3 days.

After 3 weeks of RENASYS™ tNPWT, the condition of the wound bed had sufficiently improved, enabling a skin graft to be performed.

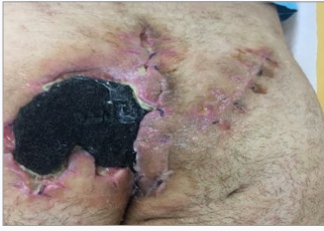The patient was stepped across to PICO™ sNPWT for the final 4 weeks of treatment and following the skin graft, as there was granulating tissue. The wound was smaller and more superficial, and there were no indicators of infection. At this time, because the wound was superficial (less than 2 cm deep), the use of foam filler was discontinued.

### CONCLUSION

After 54 days of treatment (3 weeks of RENASYS™ tNPWT and 4 weeks of PICO™ sNPWT), treatment goals were met: healthy granulation tissue was present, the surrounding area of the wound was healing, and no further dressing changes were necessary. Skin graft healing was supported by PICO™ sNPWT, which was introduced while the patient was still in hospital and continued in the patient's home after discharge.



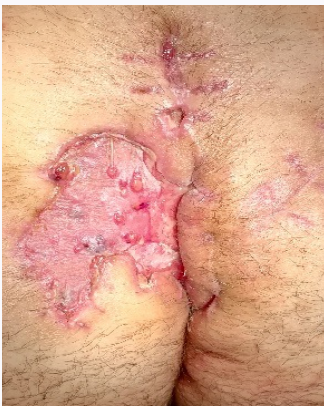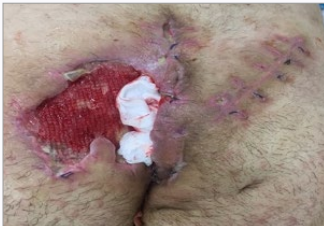**Figure 9.** End of evaluation  
(4 weeks since NPWT  
discontinuation)



**Week 1: 1 week with RENASYS™ tNPWT**

**Exudate level and consistency:** Moderate and thick  
**Wound size (length x width x depth):** 20cm x 15cm x 4cm  
**Tissue type:** Superficially infected, signs of mild inflammation  
**Surrounding skin:** Normal.

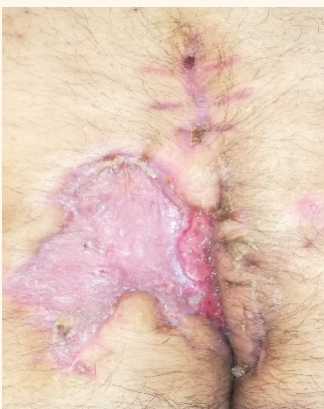**Filler:** Foam filler  
**Pressure setting:** Continuous at -120mmHg  
**Planned dressing change frequency:** Every 3 days  
**Treatment plan:** As per the OneNPWT decision tree, continue RENASYS™ tNPWT.



**Week 3: 3 weeks with RENASYS™ tNPWT and skin graft**

**Exudate level and consistency:** Low and thin  
**Wound size (length x width x depth):** 25cm x 25cm x 2cm  
**Tissue type:** Granulating and healing  
**Surrounding skin:** Healthy.

**Filler:** Foam filler  
**Pressure setting:** Continuous at -120mmHg  
**Planned dressing change frequency:** Every 7 days  
**Treatment plan:** As per the OneNPWT decision tree, switch to PICO™ 7 sNPWT (that lasts up to 7 days).



**Week 7: 4 weeks with PICO™ sNPWT**

**Exudate level and consistency:** Very low and very thin  
**Wound size (length x width x depth):** 25cm x 25cm x 2cm  
**Tissue type:** Granulating and healing  
**Surrounding skin:** Healthy.

**Filler:** No longer required  
**PICO™ sNPWT dressing size:** 15cm x 15cm  
**Planned dressing change frequency:** Every 7 days  
**Treatment plan:** As per the OneNPWT decision tree, discontinue PICO™ sNPWT as treatment objectives have been achieved, and advise the patient to keep conditioning their skin.

## CASE 8: INFECTED HAEMATOMA

**Authors:** Caroline Payne, Consultant, Plastic Surgery, Royal London Hospital, United Kingdom; Maged Gamal Abdelazim Salem Elsafti, Registrar, Plastic Surgery, Royal London Hospital, United Kingdom; Jamie Banks, Plastic Surgery CT2, Plastic Surgery, Royal London Hospital, United Kingdom

### PATIENT PRESENTATION AND HISTORY

- A 43-year-old male with a past history of depression
- After hitting his leg on a bike pedal, the patient developed a blunt trauma and an infected haematoma in the left pretibial region
- After a week following injury, the patient had severe cellulitis bordering on necrotising fasciitis, with swelling and erythema extending from his left ankle to just below the knee, along with a blistering pretibial area and an underlying dermal haemorrhage requiring hospital admission and IV antibiotics
- The blister became a wet eschar and the patient's quality of life was impacted by the wound, which resulted in reduced mobility due to pain, frequent dressing changes, and the need for antibiotics
- Debridement led to a skin defect that needed to be treated by the plastic surgery team for the purposes of managing the infection and subsequent grafting.

### WOUND PRESENTATION

- **Wound size:** 8cm (length) x 12cm (width) x 1cm (depth)
- **Wound bed:** After sharp debridement carried out at the bedside, a clean healthy wound bed was observed
- **Surrounding skin:** Healthy
- **Consistency and exudate level:** Thin and at low level.

### MANAGEMENT PLAN AND CLINICAL OUTCOMES

**Goal:** Easy and user-friendly application of dressings, and decrease infection risk.

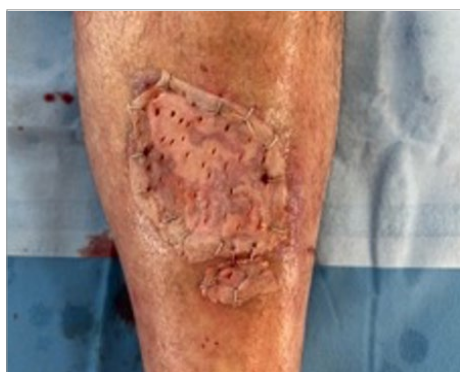The wound was not ready for skin grafting, so PICO™ sNPWT was introduced in accordance with the OneNPWT decision tree after the patient was discharged from hospital. ACTICOAT™ FLEX Dressing was not necessary because the wound was not clinically infected.

- **NPWT:** PICO™ sNPWT
- **PICO dressing size:** 15cm x 20cm
- **Planned dressing change frequency:** Weekly

After 2 weeks of PICO™ sNPWT, the wound size and exudate volume had decreased to the point where a skin graft was suitable and performed.

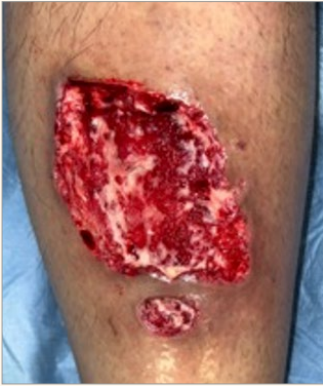### CONCLUSION

The patient did not experience any discomfort during the 18 days of PICO™ sNPWT, the treatment goals were achieved and the skin was ready for grafting.



**Figure 10.** Post skin-graft (NPWT discontinuation after 18 days of PICO™ sNPWT)

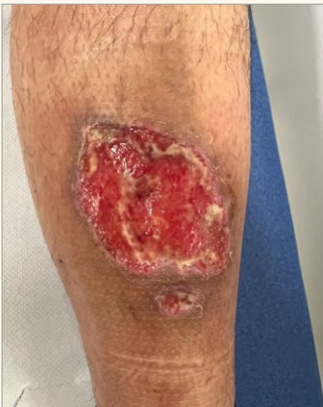



**Week 0: Start of treatment with PICO™ sNPWT**

**Exudate level and consistency:** Low and thin  
**Wound size (length x width x depth):** 8cm x 12cm x 1cm  
**Tissue type:** Healthy  
**Surrounding skin:** Healthy.

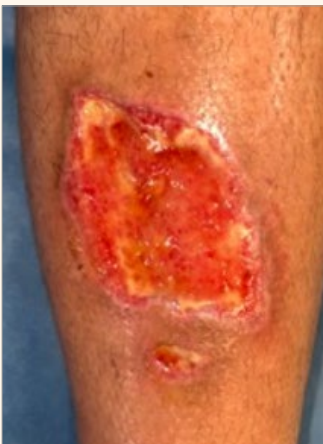**PICO™ sNPWT dressing size:** 15cm x 20cm  
**Planned dressing change frequency:** Weekly  
**Treatment plan:** As per the OneNPWT decision tree, continue PICO™ sNPWT.



**Week 1: 1 week of treatment with PICO™ sNPWT**

**Exudate level and consistency:** Low and thin  
**Wound size (length x width x depth):** 7.5cm x 11cm x 0.7cm  
**Tissue type:** Healthy  
**Surrounding skin:** Healthy.

**PICO™ sNPWT dressing size:** 15cm x 20cm  
**Planned dressing change frequency:** Weekly  
**Treatment plan:** Continue PICO™ sNPWT as the wound is not yet ready for skin grafting.



**Week 2: 2 weeks of treatment with PICO™ sNPWT**

**Exudate level and consistency:** Low and thin  
**Wound size (length x width x depth):** 7cm x 10.5cm x 0.5cm  
**Tissue type:** Clean wound base  
**Surrounding skin:** Healthy.

**PICO™ sNPWT dressing size:** 15cm x 20cm  
**Planned dressing change frequency:** Weekly  
**Treatment plan:** As per the OneNPWT decision tree, discontinue PICO™ sNPWT as treatment objectives have been met and the skin is ready for grafting.

## CASE 9: INFECTED WOUND FOLLOWING A BREAST REDUCTION

**Authors:** Caroline Payne, Consultant, Plastic Surgery, Royal London Hospital, United Kingdom; Maged Gamal Abdelazim Salem Elsafti, Registrar, Plastic Surgery, Royal London Hospital, United Kingdom; Jamie Banks, Plastic Surgery CT2, Plastic Surgery, Royal London Hospital, United Kingdom

### PATIENT PRESENTATION AND HISTORY

- A 26-year-old female who underwent a breast reduction abroad resulting in a wound with necrosis and dehiscence
- The wound was taking a long time to heal in an area that limits mobility and quality of life.

### WOUND PRESENTATION

- **Wound size:** 8.5cm (length) x 5cm (width) x 0.5cm (depth)
- **Wound bed:** After sharp debridement carried out at the bedside, a clean healthy wound bed was observed
- **Surrounding skin:** Viable and healthy
- **Consistency and exudate level:** Thin and at low level.

### MANAGEMENT PLAN AND CLINICAL OUTCOMES

**Goal:** Easy, secure and user-friendly dressing application and reduced infection risk.

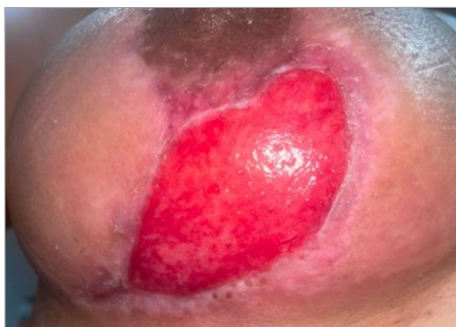As the wound initially appeared as a patch of necrotic tissue running along the vertical scar between the areola and the inframammary fold, the patient underwent sharp debridement by tissue viability nurses. A skin graft was offered to the patient, but she declined in favour of conservative management to see how well the wound would heal. As a result, PICO™ sNPWT was initiated in accordance with the OneNPWT decision tree.

- **NPWT:** PICO™ sNPWT
- **PICO dressing size:** 15cm x 15cm
- **Planned dressing change frequency:** Weekly.

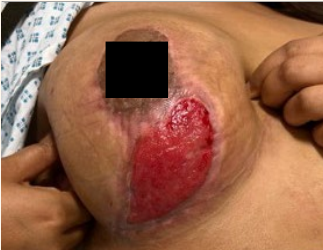PICO™ sNPWT was continued for 3 weeks. Granulation tissue could be seen and the wound was shrinking with each dressing change, indicating that wound healing was progressing each week.

### CONCLUSION

After 3 weeks of PICO™ sNPWT, the wound was ready for skin grafting; however, the patient preferred not to have any further surgery. Consequently, PICO™ sNPWT was continued.



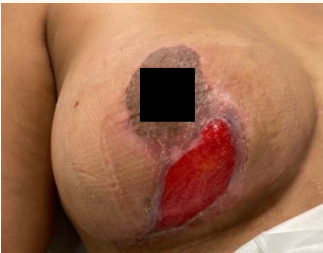**Figure 11.** End of evaluation (21 days of PICO™ sNPWT)



**Week 0: Start of treatment with PICO™ sNPWT**

**Exudate level and consistency:** Low and thin  
**Wound size (length x width x depth):** 8.5cm x 5cm x 0.5cm  
**Tissue type:** Healthy and clean  
**Surrounding skin:** Healthy and viable.

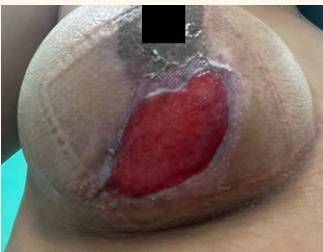**Filler:** No filler was required, as the wound was shallow  
**PICO™ sNPWT dressing size:** 15cm x 15cm  
**Planned dressing change frequency:** Weekly  
**Treatment plan:** As per the OneNPWT decision tree, continue PICO™ sNPWT.



**Week 1: 1 week of treatment with PICO™ sNPWT**

**Exudate level and consistency:** Low and thin  
**Wound size (length x width x depth):** 8cm x 4.5cm x 0cm  
**Tissue type:** Healthy and clean  
**Surrounding skin:** Healthy and granulating with no signs of active infection.

**Filler:** No filler was required, as the wound was shallow  
**PICO™ sNPWT dressing size:** 15cm x 15cm  
**Planned dressing change frequency:** Weekly  
**Treatment plan:** As per the OneNPWT decision tree, continue PICO™ sNPWT to encourage further granulation.



**Week 3: 3 weeks of treatment with PICO™ sNPWT**

**Exudate level and consistency:** Low and thin  
**Wound size (length x width x depth):** 7.5cm x 3.5cm x 0cm  
**Tissue type:** Healthy and clean  
**Surrounding skin:** Healthy and granulating with no signs of active infection.

**Filler:** No filler was required, as the wound was shallow  
**PICO™ sNPWT dressing size:** 15cm x 15cm  
**Planned dressing change frequency:** Weekly  
**Treatment plan:** As the wound is still healing, continue PICO™ sNPWT.



A Wounds International publication

[www.woundsinternational.com](http://www.woundsinternational.com)