



+ Purification to procedure

An integral part of
Advanced Healing Solutions

Smith+Nephew

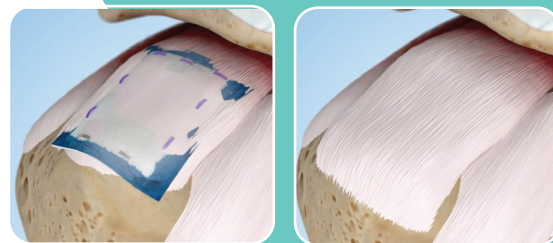


REGENETEN 
Bioinductive Implant

Supports the body's natural healing response¹⁻⁵

The REGENETEN[®] Bioinductive Implant is placed on the bursal surface of the rotator cuff, creating a favorable biomechanical healing environment for new tendon growth. The implant completely resorbs within 6 months* inducing on average 2mm of tendon-like tissue.^{1-2,6}

The REGENETEN Bioinductive Implant is **not a patch or graft**.



Characteristics which induce native tissue generation.⁷

Fiber Alignment/ Orientation⁷

During processing the material is reconstituted resulting in an aligned fiber orientation.

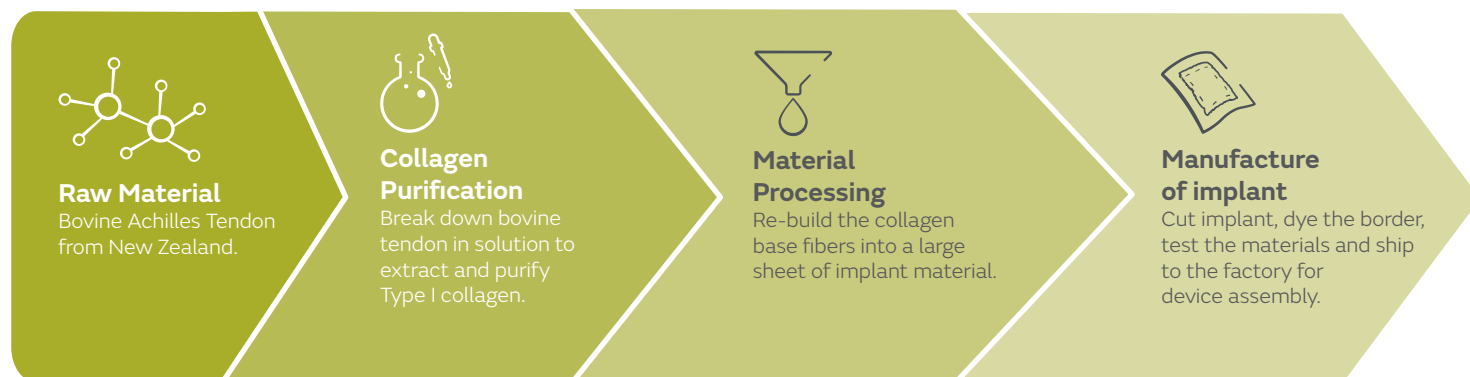
Low Residual DNA⁷

As a result of the purification process, the implant has minimal residual DNA content.

High Porosity

While in the hydrated state, the porous implant swells in size allowing for blood vessel integration, fibroblast ingrowth and new collagen formation.^{3,8}

Manufacturing process of the REGENETEN Bioinductive Implant



* On human biopsy (n=1) and *in-vivo* sampling

Learn more at smith-nephew.com

Sports Medicine
Smith & Nephew, Inc.
150 Minuteman Road
Andover, MA 01810

www.smith-nephew.com
T +978 749 1000
US Customer Service:
+1 800 343 5717

[®]Trademark of Smith+Nephew.
©2020 Smith+Nephew. All rights reserved. All trademarks acknowledged.
Printed in USA. 25350 V1 07/20



References

1. Bokor DJ, Sonnabend D, Deady L, et al. Evidence of healing of partial-thickness rotator cuff tears following arthroscopic augmentation with a collagen implant: a 2-year MRI follow-up. *Muscles, Ligaments Tendons J* 2016;6(1):16-25.
2. Schlegel TF, Abrams JS, Bushnell BD, Brock JL, Ho CP. Radiologic and clinical evaluation of a bioabsorbable collagen implant to treat partial-thickness tears: a prospective multicenter study. *J Shoulder Elbow Surg.* 2018 27(2):242-251.
3. Van Kampen C, Arnoczky S, Parks P, et al. Tissue-engineered augmentation of a rotator cuff tendon using a reconstituted collagen scaffold: a histological evaluation in sheep. *Muscles Ligaments Tendons J.* 2013;3(3):229-235.
4. Bokor DJ, Sonnabend DH, Deady L, et al. Healing of partial-thickness rotator cuff tears following arthroscopic augmentation with a highly porous collagen implant: a 5-year clinical and MRI follow-up. *Muscles, Ligaments Tendons J* 2019;9(3):338-347.
5. McElvany MD, McGoldrick E, Gee AO, Neradilek MB, Matsen FA, 3rd. Rotator cuff repair: published evidence on factors associated with repair integrity and clinical outcome. *Am J Sports Med.* 2015;43(2):491-500.
6. Bokor DJ, Sonnabend D, Deady L, et al. Preliminary investigation of a biological augmentation of rotator cuff repairs using a collagen implant: a 2-year MRI follow-up. *Muscles, Ligaments Tendons J* 2015;5(3):144-150.
7. Smith + Nephew 2020 REGENETEN Collagen Implant Physical Characteristics. Internal Report
8. Arnoczky SP, Bishai SK, Schofield B, et al. Histologic Evaluation of Biopsy Specimens Obtained After Rotator Cuff Repair Augmented With a Highly Porous Collagen Implant. *Arthroscopy.* 2017;33(2):278-283.