

ATLAS
FOR THE INSERTION
OF TRANSOSSEOUS WIRES
AND HALF-PINS
ILIZAROV METHOD



M. A. CATAGNI

ATLAS
FOR THE INSERTION
OF TRANSOSSEOUS WIRES
AND HALF-PINS
ILIZAROV METHOD

EDITOR
A. BIANCHI MAIOCCHI

AUTHOR

Maurizio A. Catagni, M.D., Orthopaedic Surgeon
Professor at the Milano University, Medical School
Founding Member and President of A.S.A.M.I. Italy
Chief of the Orthopaedic Department and Ilizarov Unit
“Alessandro Manzoni” Hospital - Lecco
E-mail: maurizio@catagni.it
<http://www.asami.org/>

EDITOR

Antonio Bianchi Maiocchi, M.D.
Emeritus Head Department of Orthopaedics-Traumatology
“Ospedale Maggiore” Novara, Italy
Associate Professor Department of Orthopaedics
University of Turin
Founding Member of A.S.A.M.I. Italy

CONTRIBUTORS

John Joseph Maguire, M.D.
North Queensland Orthopaedics, Townsville, Queensland, Australia

Richard S. Page, BMedSci, MB, BS, FRACS (Orth)
The Geelong Hospital, Geelong, Victoria, Australia

Doron Sher, MBBS MBiomedE FRACS
Vaucluse, Australia

J. Pous i Barral M.D.
Jefe de Servicio Mutua Universal – Barcelona
(Author of the book: “Atlas anatomotopográfico
de las extremidades y fijación externa anular”, Barcelona, 1988)

REVIEWERS

Dr. Kevin Coupe (USA) - Dr. Mark Dahl (USA) - Dr. Kevin Louie (USA)
Dr. David Lowenberg (USA) - Dr. Kevin Pugh (USA) - Dr. Vladimir Schwartzman (USA)



**Medi
Surgical
Video**

Copyright 2003 Medi Surgical Video, Department of Medicalplastic srl,
Via Mercadante, 15 - 20124 Milan - Italy

ISBN N. 88-900250-2-6

First edition 2002 - Second revised edition 2003

Typesetting, lithos and printing: il quadratino, Milan, Italy
Design: Antonella Corti, Architect, Politecnico of Milan, Italy
Graphic Designer: Camillo Sassi
General revision and proof reading: Marinella Combi

All right reserved. This book is protected by copyright. No part of this book may be reproduced in any form or by any means, including photocopying, or utilized by any information storage and retrieval system without written permission from the copyright owner.

Printed in Italy

Contents

	pag.
Introduction	IV
Foreword	V
Basic principles of operative technique	VIII
Levels of the anatomical cuts of the upper extremity	1
- Humerus right	1
- Humerus left.	3
- Radius and ulna right	11
- Radius and ulna left	13
Levels of the anatomical cuts of the lower extremity	21
- Femur right	21
- Femur left	23
- Tibia and Fibula right	31
- Tibia and Fibula left	33
Appendix	41
- Pelvis left	41
- Hand left – Metacarpal	43
- Ankle Joint left	45-46
- Foot left	47
- Foot left – Hindfoot	48
- Foot left – Midfoot, Forefoot	49
- Foot left – clinical examples	50

References

- A.S.A.M.I. Group: Editors A. Bianchi Maiocchi and J. Aronson *Operative Principles of Ilizarov Medi Surgical Video*, Milano, 1991
- Boileau Grant J.C. *An Atlas of Anatomy* Baillière, Tindall & Cox, London, 1947
- Catagni M.A., Malzev V., and Kirienko A., *Advances in Ilizarov Apparatus Assembly* Medicalplastic, Milano, 1994
- Catagni M.A. *Treatment of fractures, nonunions, and bone loss of the tibia with the Ilizarov method* Medicalplastic, Milano, 1998
- Faure C., Merloz Ph. *Transfixion des membres* Springer-Verlag, Berlin-Heidelberg-New York, 1987
- Green S.A. *Complications of External Skeletal Fixation* Charles C Thomas, Springfield, IL, 1981
- Ilizarov G.A., *Transosseous Osteosynthesis* Springer-Verlag, Berlin, 1992
- Lehman W.B., Paley D., and Atar D. *Operating Room Guide to Cross Sectional Anatomy of the Extremities and Pelvis* Raven Press, New York, 1989
- Popkov A.V., Shevtsov V.I. *Akhondroplasiya*, Moskva, 2001
- Shevtsov V.I., Makushin V.D., Kufyrev L.M., Soldatov Ju. P., *Psevdootrozy, defekty dlinnykh kostej verkhnej konechnosti i kontraktury loktevegogo sustava*, Kurgan, 2001

Introduction

A. BIANCHI MAIOCCHI

The use of transosseous wires and half pins for Ilizarov's method necessitates intimate awareness of anatomic topography to avoid injury to nerves and vessels.

After the world-wide diffusion of the hybrid wire – half pin methodology a great number of surgeons have requested a more updated Anatomical-Topographical Atlas with detailed anatomical cuts of the extremities.

On the basis of the above-mentioned request, we have illustrated the present text using diagrams in which the names of vessels, nerves, muscles, etc are indicated.

We have divided both upper and lower limbs into 6 levels.

We have added in metacarpal site two cuts (in the Appendix). It is often necessary to have a greater stability at the level of the wrist in certain forearm pathological conditions.

We have also introduced one standard cut of the pelvis and two cuts of the foot in order to reach a greater stability of the femur and tibia respectively.

The references have been made according to the illustrated levels by means of direct palpation of the limb considering the osseous landmarks, such as the lateral malleolus and the head of the fibula for the tibia, the radial styloid and head of radius for the forearm, the lateral epicondyle and the greater tuberosity for the humerus.

Other reference parts are those presented by palpation

of the muscular interstices.

To better understand the technique of introduction of the wires and half pins it is advisable to consult the book "Advances in Ilizarov Apparatus Assembly".

We indicate more usual sites of insertion (in our diagrams), but the surgeon can use more suitable variants considering the location of the vessels and nerves.

For each of the transverse sections shown we have given its corresponding surface anatomical site that can be found by clinical examination.

The surgeon can thus be more certain about the configuration of the underlying skeleton.

A x-ray correspondance of the sections is useful for preassembly of the apparatus prior to operative application.

It is necessary to carefully read the author's Foreword which details the technique, derived from a twenty-year experience.

The innovation of the hybrid "wires-half pins" assembly has decreased complications and has increased the tolerance of the apparatus for the patients.

The "Atlas" is an indispensable guide for all surgeons who begin to use this exacting technique.

The surgeons must always keep in mind that the anatomical segment may be pathological and therefore the anatomy can be abnormal.

Correct pin insertion technique will reduce the risk of unnecessary tissue damage.

Note: the diameters of wires and half pins in the diagrams do not correspond to the reality.

It is necessary to use them as follows:

- wires Ø 1.5 or 1.8 mm and half pins Ø 4 or 5 mm for the forearm or in paediatric surgery;
- wires Ø 1.8 mm and half pins Ø 5 mm for humerus;
- wires Ø 1.8 mm and half pins Ø 5 or 6 mm for the femur and tibia.

The choice of the diameters depends especially on the weight of the patient and on the pathology to treat.

The titanium pins are wicker and it is necessary to improve the diameter or the number of insertions.

It is necessary to have no more than two threads protruding through the bone on the distal side of the half pin and no more than two threads on the near side.

In some anatomic positions (diaphysis of the tibia) the thread protrude through the skin, but this has not any clinic importance as it does not affect the stability and does not produce infections.

Foreword

Upgrade of the Ilizarov Method – wires and pins, changes through the years

M.A. CATAGNI AND D. SHER*

After many years of using the original Ilizarov technique several problems were noticed. These can be grouped into: patient pain or inconvenience, soft tissue problems and loss of joint range of motion. Degree of surgical difficulty also needs to be considered since some wires passed very close to neurovascular structures. Several modifications of the original Ilizarov technique have been utilised in what we now call the Ilizarov Method. These changes can be grouped both chronologically and by body region. The changes have led to a decrease in pin tract infection rate from 20% to approximately 10% and significant improvements in patient comfort.

The original Ilizarov technique used multiple tensioned wires in order to reduce soft tissue trauma. When 2 wires are crossed at 90 degrees within the bone, fixation stiffness in all directions is equal to the stiffness that a single wire exhibits with respect to the force acting upon the wire perpendicular to its axis, but initial wire tension diminishes with time. Although tension is maintained during distraction, once the desired length is achieved and the frame locked for the consolidation phase, the tension diminishes. This causes problems with the wires due to deficiency of stability of the frame construct which in turn leads to soft tissue problems. The frames can be modified and stability increased by adding more wires but this needs to be done under anaesthesia.

In an attempt to avoid this problem and increase the stability of our frames we started using two levels of fixation per segment and abandoned the method of a third wire on a post (the 'drop wire'). The wire on the post was unstable because it could not be tensioned appropriately without deforming the ring and therefore less tension was applied to this wire. This caused more osteolysis and a higher infection rate due to the increased movement of the wire which resulted. In the proximal tibia, in case of lengthening, to avoid this problem we changed from a

single ring at the proximal tibia to a double ring construct. This was achieved by adding an anterior half ring proximally which was connected to the original proximal ring. This meant that the original complete ring was used slightly more distally, allowing greater knee flexion. The whole construct was more rigid and used a minimum of four wires per segment (2 wires per ring) rather than the 3 previously used. This began what was the first step in the evolution of the Ilizarov frame in the west.

In our subsequent courses and meetings, we began teaching the method of fixation at two levels and emphasizing the importance of stable fixation. With other modifications of the frame that reduced or eliminated instability, we decreased our complications and increased the chance of successful treatment.

The problems noticed with the shoulder and proximal femur were similar. The patients complained that they were unable to lie supine and had great difficulty sleeping. In the hip this caused adduction and flexion contractures or subluxation of the femoral head since the patients were unable to sit and spent considerable periods of time lying in the lateral position with the affected side uppermost. Their only alternative was to cut a hole in their bed but this was very expensive and still limited the positions they could adopt.

We attempted to modify the original femoral frame by moving the proximal arch distally, but by so doing we had to transfix a larger muscle mass, further limiting knee motion and producing quadriceps inhibition. This method was abandoned.

Following an incident where it was necessary to remove the proximal femoral wires (during an acute rotational correction 2 wires compressed the sciatic nerve between them and needed to be removed) and replace them with a half pin construct, we noticed that this patient had fewer problems sleeping and was generally more comfortable with his frame. The healing rate

*Doron Sher, MBBS MBiomedE FRACS - Vaucluse - Australia

was acceptable and a new technique had been born.

Since that time the half pin construct has been used on all proximal femora with excellent results (see 'Delta' configuration below). The pin tract infection rates and hip pathology rates are significantly lower and the patients are more comfortable. Slightly slower healing rates have been noted than were present with all wire constructs. This is not significant however and the increase in patient comfort far outweighs the slowing of the healing rate.

The 'delta' configuration describes the 'triangle' shape created when 2 half pins are inserted into the proximal femur at an angle of approximately 60 degrees to each other (they are perpendicular to the bone) but in the same coronal plane. The base of the triangle is created by a half ring and a stable construct is created. As the technique has evolved we have found it best to place the half pins as posterolateral as possible. The quadriceps mechanism is avoided which allows knee movement. At least two linked half rings and at least 4 half pins are used, which again gives greater stability. The same technique is applied to the proximal humerus but fewer rings and pins can be used since the loads applied to this bone are significantly lower.

As with other areas, 3 wires were used to transfix the proximal tibia by Ilizarov. In 1986 it was noticed that one wire in particular caused considerable pain for the patient. This wire passed from anterolateral to posteromedial and into the pes anserinus. The pes and its' overlying skin were irritated with any attempted knee movement. This caused pain for the patient, a high skin infection rate and significant knee stiffness from the patient's unwillingness to flex their knee. The infections were always superficial and responded to oral antibiotics and wound care but were present in up to 20% of patients.

The wire that passed through the fibula head initially had few problems but after a few weeks osteolysis of the fibula head was noticed and then the skin infection rate in this region increased. The transverse wire caused little morbidity and was therefore not changed. The 2 oblique wires were replaced with 2 half pins into the subcutaneous border of the tibia (1 medial and 1 lateral). This did not detract from the stability of the construct and significantly reduced patient pain, increased the knee range of motion and effectively halved the pin tract infection rate.

The wires through the ankle have generally been well tolerated. There has been little need to change these, although if extra stability is needed, we will add a half pin rather than placing another wire close to the posterior neurovascular bundle.

As with other parts of the body Ilizarov originally used three wires in the distal femur. The transverse wire, if inserted correctly, caused few problems (this will be discussed further below). The 2 oblique wires transfixed the quadriceps mechanism and created knee extension

contractures. This caused loss more than 60 degrees of knee motion which took several years to return to normal or near normal. The anterior wires transfixed mobile skin and caused significant pain and the posterior wires were prone to contamination and subsequent infection. These 2 wires have been replaced by half pins. The pins are placed in the same line as the wires were but in a posterior to anterior direction (prior to half pin insertion it is important to bluntly dissect the soft tissues in a longitudinal direction). Since there is less movement of the skin posteriorly then anteriorly these pins are well tolerated. In addition the patients are able to maintain knee movement because the quadriceps mechanism is not transfixed.

Insertion of the transverse distal femoral wire is a three stage process. With the knee in extension to judge the alignment of the leg, the wire is inserted through the distal femur (wires should be perpendicular to the surface of tubular bones where possible). When the surgeon is satisfied with the position of the wire, it is withdrawn below the soft tissues on the medial side but left in bone to maintain its general alignment. The knee is then flexed to thirty degrees and the wire is passed back through the soft tissues on the medial side while maintaining the same bony alignment. Following this the wire driver is changed to the medial side and the wire is withdrawn below the soft tissues on the lateral side. The knee is flexed to approximately 90 degrees and the wire is passed through the soft tissues in a medial to lateral direction. If possible the wire should emerge posterior to the tensor fascia latae. The knee is put through a range of motion and the protruding ends of the wire observed. If the wire does not bend with knee movement then its position is acceptable. If it bends on both the medial and lateral sides it must be withdrawn completely and replaced. If it bends on the lateral side only, the tensor fascia latae must be progressively divided until the wire no longer bends with knee movement.

The 2 constructs have similar initial rigidity. After about 3 weeks the wires then progressively loosen (particularly during consolidation). This is not the case with the half pins and so, long term, the single transverse wire with 2 half pins is more rigid than the three wire construct.

The next modification made was to calcaneal fixation. The two oblique wires originally used were replaced with one transverse wire and one half pin placed posteriorly in the sagittal plane. This reduced pin tract problems but the patients complained of heel pain where the pin entered the achilles tendon insertion. This was subsequently modified to the current technique which is to use two oblique half pins and no wires. These are placed away from the achilles tendon and follow the longitudinal axis of the calcaneum as much as possible. Two cortex fixation is achieved and the patients have minimal discomfort from these pins.

The next modification was to the distal humerus. Originally there were 2 wires at about 30 degrees to each other at the level of the epicondyles. The posteromedial wire passed very close to the ulnar nerve. A third wire on a post passed transversely through the humerus more proximally with the ring placed at the level of the crossed wires. There were problems with lack of stability due to the third wire and also soft tissue problems from skin movement, particularly anteromedially. The current technique is to pass a transverse wire at the level of the epicondyles in a medial to lateral direction. This avoids the ulnar nerve and is in an area which has relatively little skin movement. The fixation is augmented with two half pins. One passes from posterior to anterior through the distal triceps into the distal humerus just above the olecranon fossa and the second passes from posterolateral to anteromedial into the lateral epicondyle of the humerus. Frame rigidity is maintained and few skin problems are noticed.

The next technique change was at the mid tibial level. When 2 oblique wires were used at this level at least one of these had to pass through a muscle belly. This caused pain and muscle scarring with a higher infection rate. When the oblique wire was replaced by half pins into the subcutaneous border of the tibia, the pain and infection rates dropped and the ankle range of motion improved. We now use 2 half pins only, or pins with 1 wire (which passes obliquely but always exits anterior to the posteromedial border of tibia).

The most recent change has been to the method of tibiofibular fixation when lengthening the tibia. Following the change to anterior half pins at the proximal tibial level it was noticed that the patients lost knee range of motion due to the fibula being pulled distally (along with the lateral collateral ligament and associated structures). We did not wish to return to using the posterolateral wire since the complication rate without it was so much lower. The solution was to pass a K wire using the old technique but use this as a guide to drill from anteromedially through the tibia and into the fibula. A half pin was then used which prevented the fibula migrating distally and could also be attached to the frame for additional fixation. While it worked well this method was very time consuming. We now use a more simple method which has achieved the same results. A 3mm K wire is drilled percutaneously through the fibula and tibia in the original Ilizarov fashion. The wire driver is then moved to the anteromedial aspect of the tibia and the wire is withdrawn to be within the fibula. The tibia and fibula are thus transfixed in a one step process and the wire is then attached to the ring. It is important that the wire go from superior to inferior as well as from posterolateral to anteromedial. In this way it has greater resistance to the line of pull of the fibula. Using this technique there is no longer any loss of knee movement.

In many deformities, including malunion, stiff non-

union, and congenital deformities, the corrective forces have to work against soft tissue fibrosis and muscle contracture. This requires frames of significant stability. In some cases, even very stable frames can encounter difficulties with correction. The resistance of the osseous and non-osseous tissue can cause the wires to cut through the bone. The frame position can be corrected, but the bone does not follow the frame segment. The K-wires can slide or even cut through the bone. For this reason Ilizarov devised the olive wire which improved initial fixation of the wire to the bone. Beaded wires were designed to prevent a bone fragment from sliding along a wire. Ideally they would be too big to cut through the bone but not big enough to cause extra soft tissue trauma. They have 100x more resistance to fragment displacement than a wire alone. Unfortunately our experience showed that after 2 to 3 weeks in situ the olive wires caused osteolysis of the bone against which they were placed.

This led to a loss of frame stability, and decreased the frame's ability to yield correction. This was also associated with infection and formation of a ring sequestrum. After introduction of the half pins inserted perpendicular to the plane of correction, we were able to decrease the use of olive wires. This was associated with a decrease in osteolysis and ring sequestrae.

Another use for the olive wire is the closed reduction of fracture fragments. This has the advantage of being a closed technique. We like to use the olives as a closed reduction device. When the reduction has been obtained and the frame applied, we replace the olive wire with a standard smooth wire and half pin.

In retrospect, we now realize that the initial problems with the use of the Ilizarov method were related to principal errors in surgical technique. These errors included the incorrect placement of the wires, inappropriate wire tension, insufficient number of rings, inadequate levels of fixation, and poor frame design. All of these factors contributed to instability, pain, osteoporosis, and poor patient tolerance of the frame.

Many surgeons mistakenly equate the Ilizarov method with the Ilizarov frame. One can use the Ilizarov method even with a monolateral frame if he respects the biological parameters taught by Ilizarov.

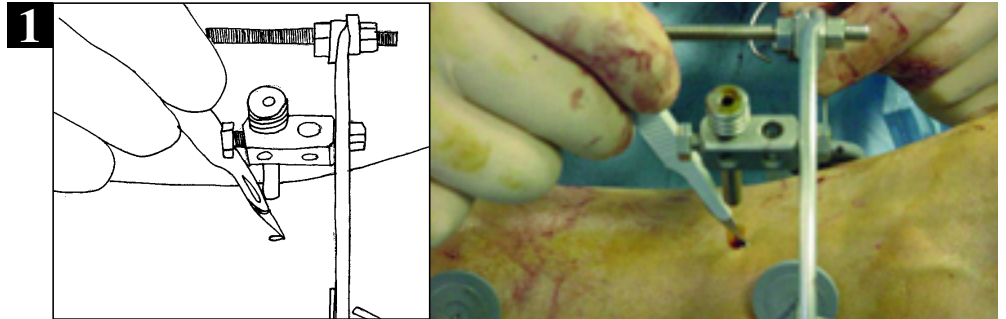
In my personal practice, I tend to simplify my frames, especially in the humerus and femur, toward a monolateral frame while maintaining the mechanics of the circular fixator. In regard to the application of the frame on the tibia, I see no advantage of a monolateral frame over the circular frame.

If it is applied correctly, the circular frame is tolerated just as well as a monolateral frame. I am able to apply a circular frame as quickly, it is just as easy to care for post-operatively, and it allows for easier correction of angular deformities.

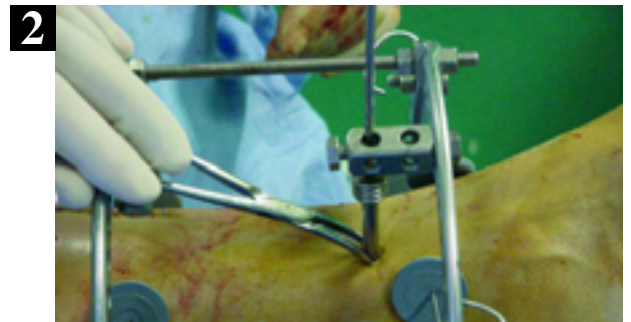Basic principles of operative technique

To prevent transfixing nerves, vessels and tendons, during the insertion of half pins the following technique is recommended.

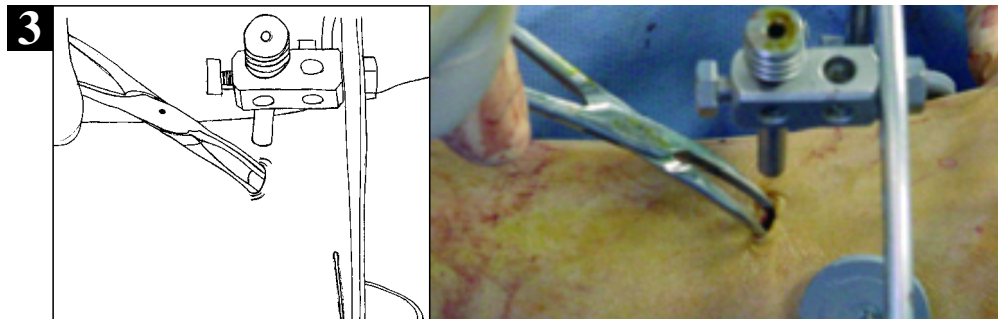
HALF PINS: a small skin incision is made with a scalpel at the appropriate position for pin insertion (1).



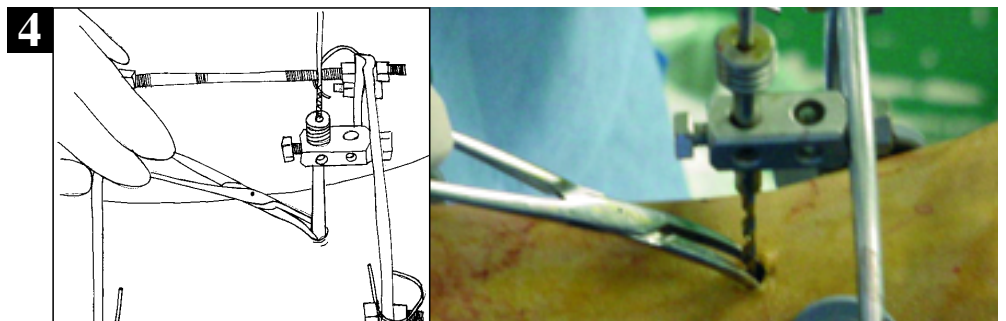
Blunt dissection with a small clamp (i.e. mosquito) is then used to separate the soft tissues down to bone (2).



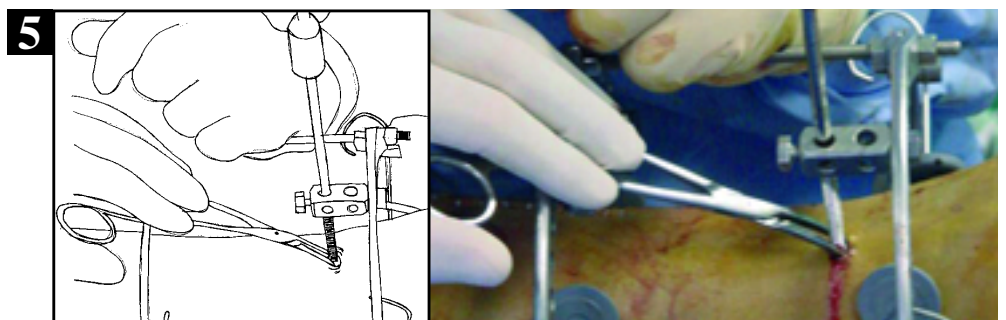
The clamp is then opened to further separate the soft tissues (3).



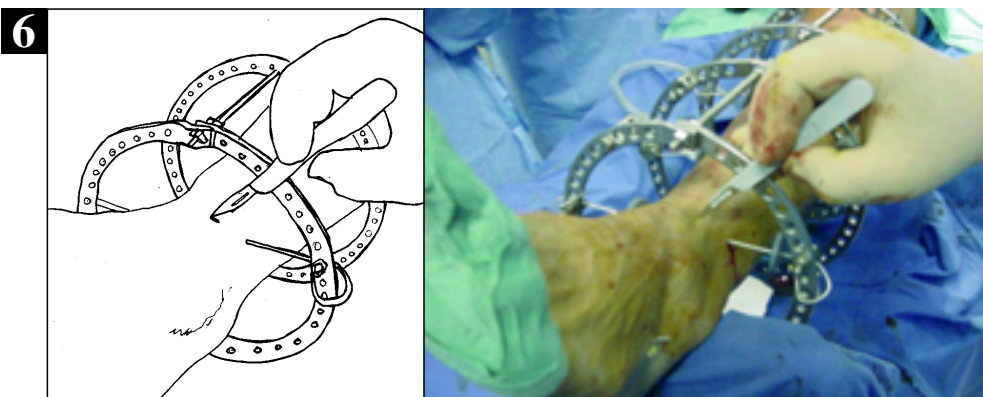
A tissue-protecting guide is then inserted along the tract and placed against the bone. Drilling is then performed with the appropriate sized drill (4). Occasionally irrigate with cold saline solution to prevent heat build up.



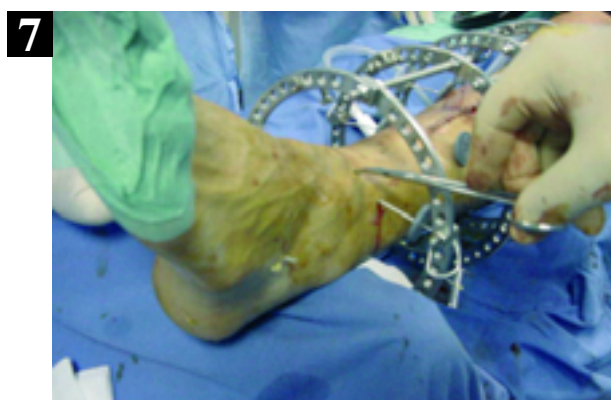Half pins or half wires are then inserted in similar fashion via a soft tissue-protecting sleeve. When drilling or inserting half pins the application of gentle pressure to the skin and soft tissues, with the hand, can tension the tissues and further reduce the chance of inadvertent damage. (5)



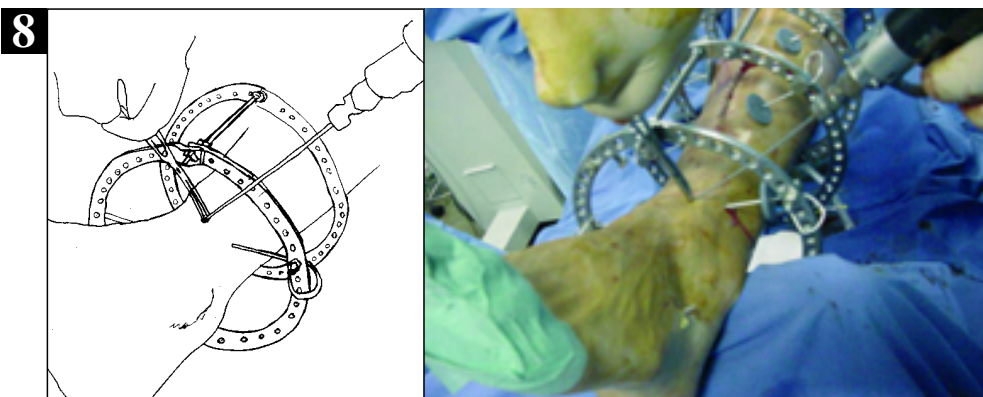
WIRES: During the insertion of wires at potentially dangerous sites, a similar technique may be used. A skin incision is made at the appropriate point for insertion of the wire (6).



Blunt dissection is then performed with the use of the clamp (mosquito) (7).



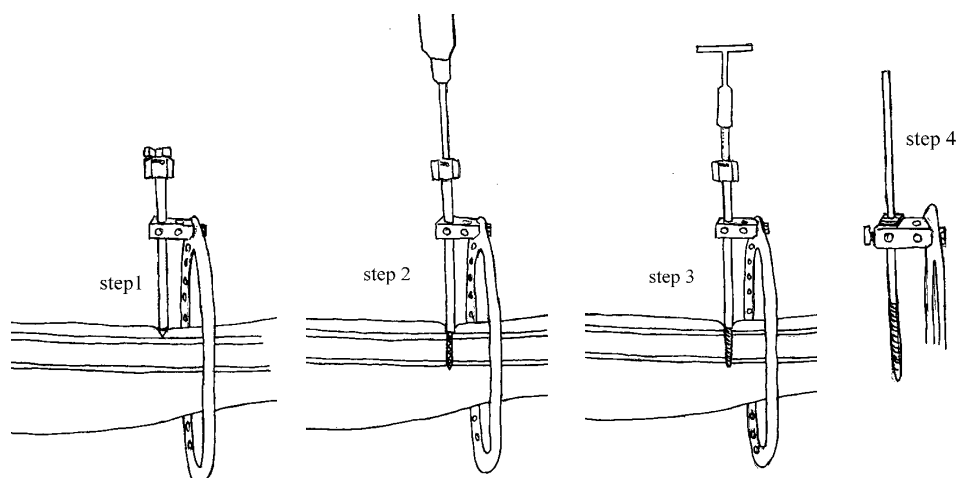
The wire is then introduced via the safe tract created by the clamp. The wire is then inserted in routine fashion. (8)



Note: The surgeon must always keep in mind that the anatomical segment may be pathological and therefore the anatomy can be abnormal. Correct pin insertional technique will reduce the risk of unnecessary tissue damage.

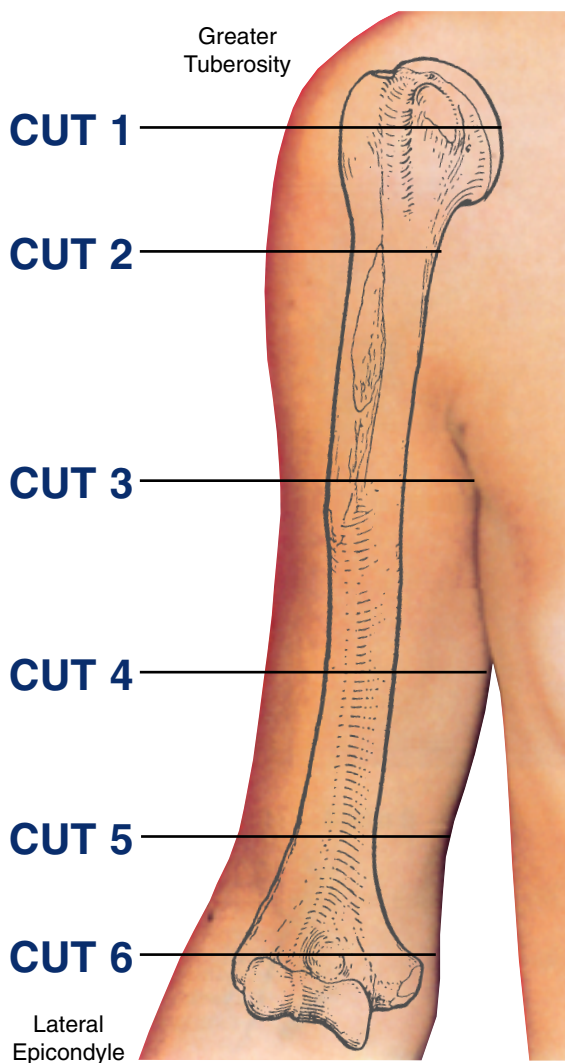
RANCHO SYSTEM

For details on the “Rancho System” technique, reference to the original article of the author Stuart A. Green is recommended: “The Rancho Mounting Technique for Circular External Fixation”, *Advances in Orthopaedic Surgery* No.-Dic. 1992 Vol. 16 No. 3.



Levels of the anatomical cuts of the upper extremity

HUMERUS* right

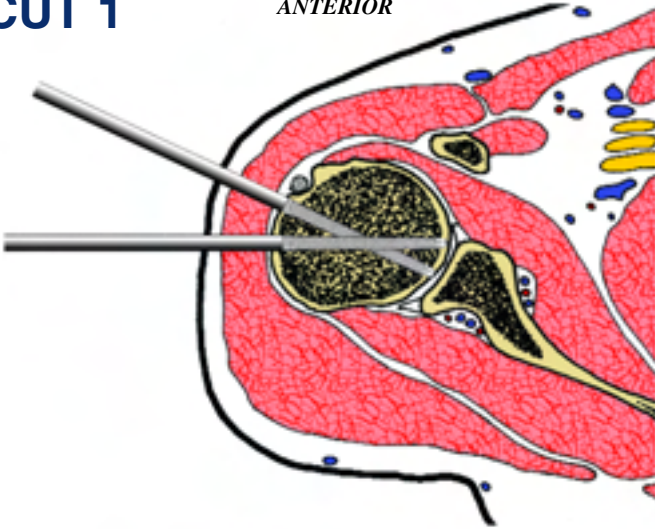


- 1** Placement of two half pins in the humeral head, is performed at the anterolateral site. The first runs transversely and the second from antero lateral to postero medial, posterior to the intertubercular groove.
- 2** The placement of half pins at the upper one third of the humeral diaphysis is carried out on the anterolateral side. At this application site, one or two pins may be used according to the needs of the individual case. When inserting the anterior half pin, care must be taken to avoid the radial N.
- 3** A fixation wire can be placed from anterolateral to postero-medial traversing both the biceps and triceps M. A half pin is inserted anterior to the radial N from anterolateral to postero-medial.
- 4** A fixation wire can be placed in an oblique direction from anterolateral to posteromedial. This traverses both the biceps and triceps M. A fixation half pin is placed medial to the radial N from posterior to anterior.
- 5** A fixation wire can be placed in a medial-oblique direction from anterolateral to posteromedial. This wire traverse both the biceps and triceps M. Extreme care must be taken with insertion of this wire. A fixation half pin is placed posteriorly, behind the radial N from posterolateral to anteromedial at an angle of forty degrees to the sagittal plane. A second half pin can be placed from posterior to anterior.
- 6** Wire placement at this level is best achieved in the coronal plane. The reasons for this are that the bone is oriented in this axis, and this plane avoids the dorsal and ventral neurovascular structures. Two wires may be inserted at this point. The first wire is inserted via the medial epicondyle. During this insertion, the ulnar N. must be palpated and pushed laterally out of harm's way. This wire should exit as anterior as is possible on the lateral condyle. The second wire is inserted more anteriorly on the medial epicondyle and directed further posteriorly. The crossing angle between these two wires should be between 20° and 30°. For additional fixation, one or two half pins may be placed adjacent to the lateral epicondyle, from posterolateral to anteromedial.

INSERTION WIRES AND HALF-PINS - RIGHT

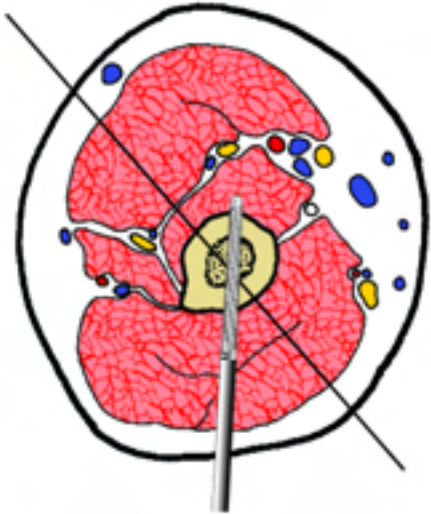
CUT 1

ANTERIOR



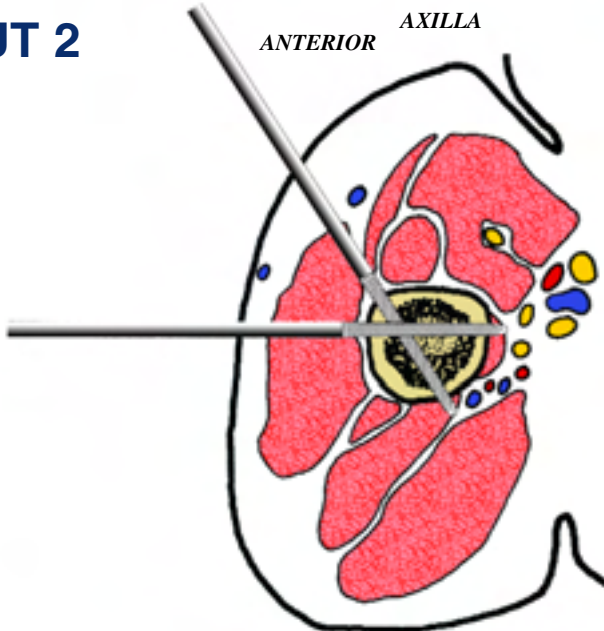
CUT 4

ANTERIOR



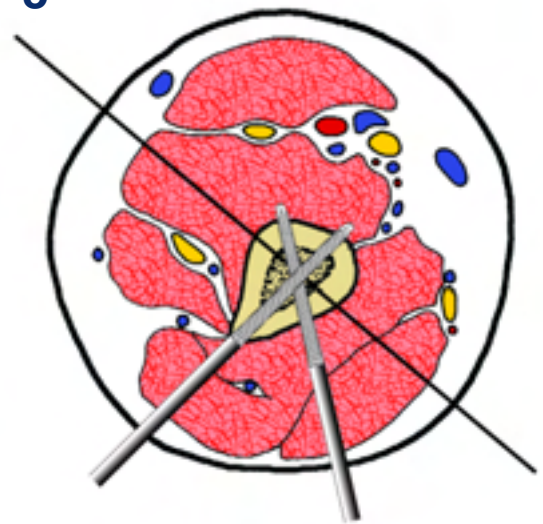CUT 2

ANTERIOR *AXILLA*



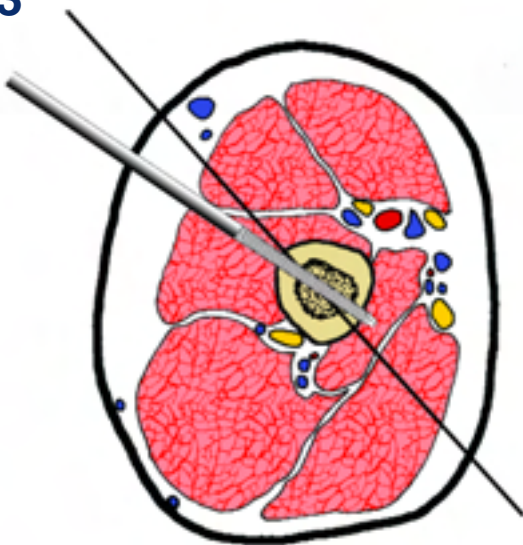
CUT 5

ANTERIOR



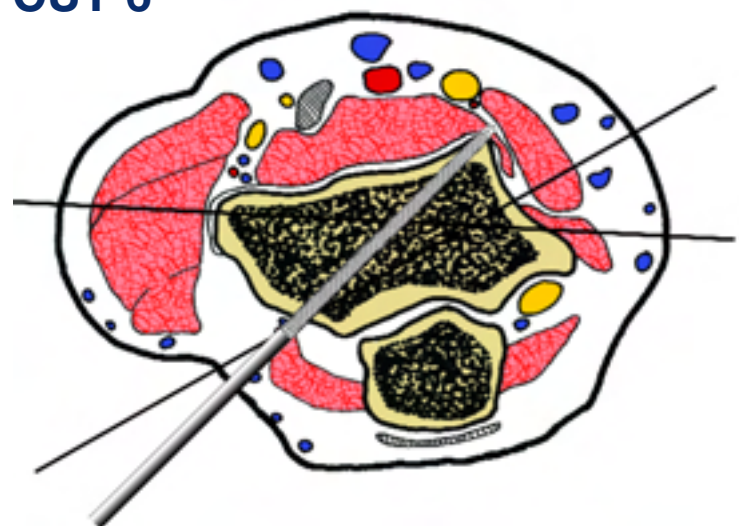
CUT 3

ANTERIOR



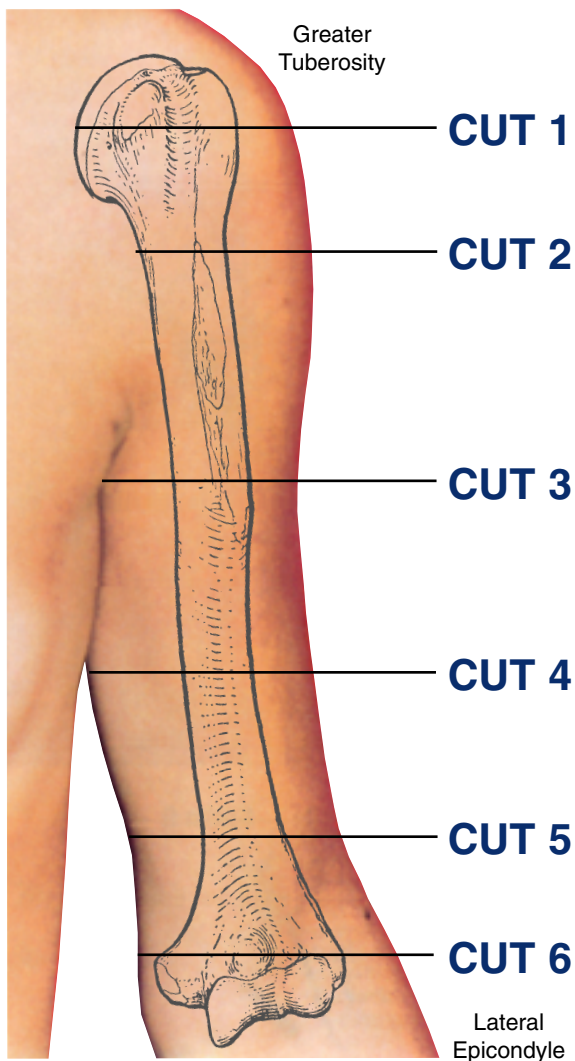
CUT 6

ANTERIOR



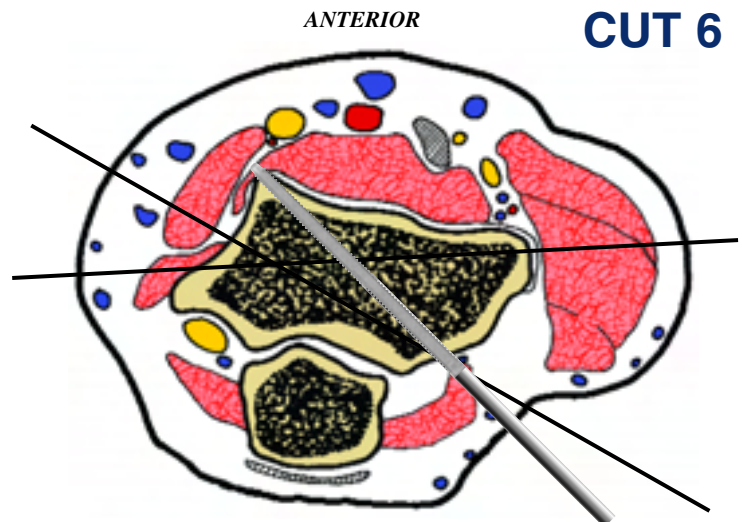
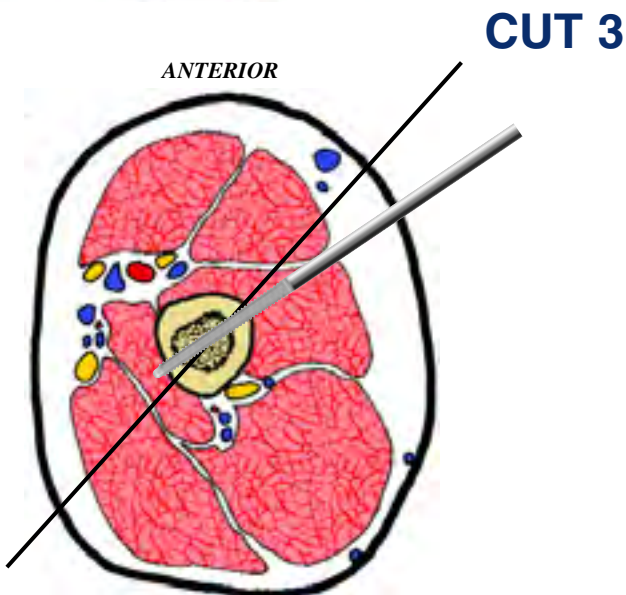
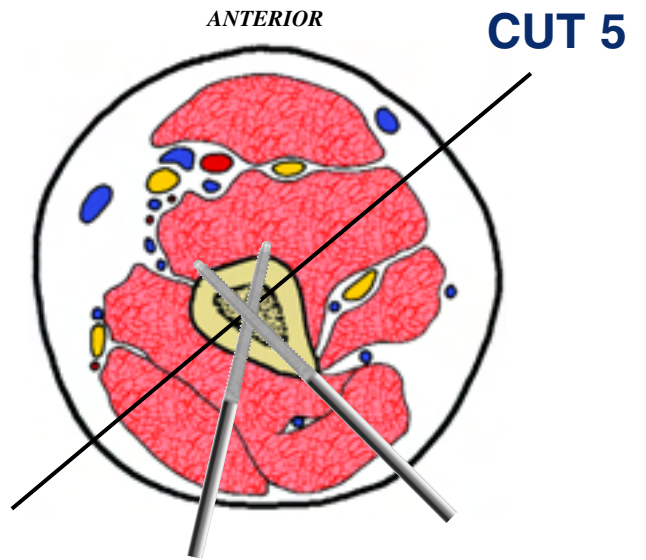
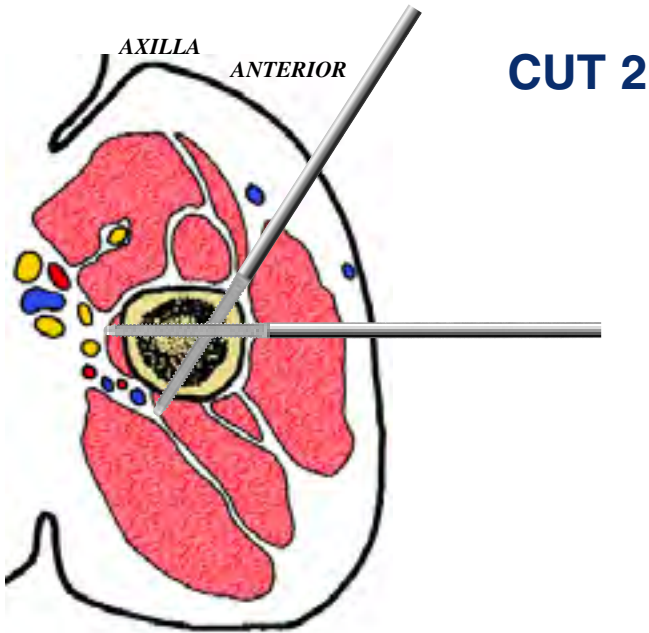
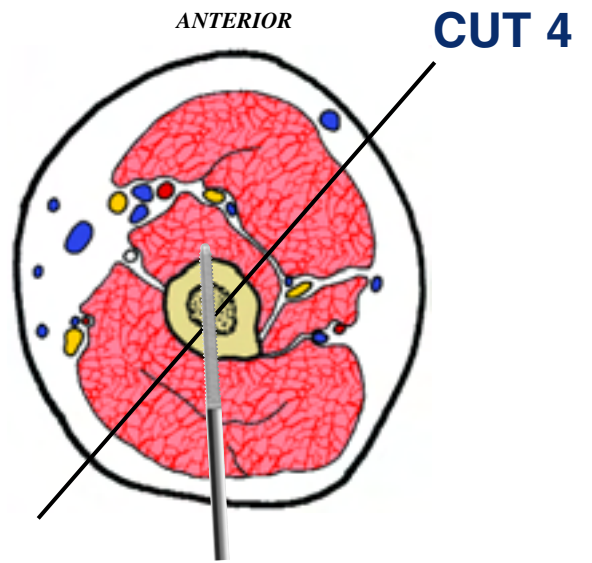
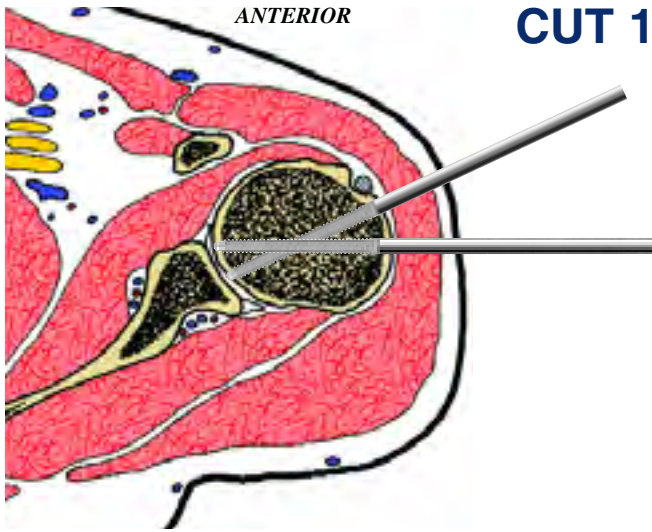
Levels of the anatomical cuts of the upper extremity

HUMERUS left



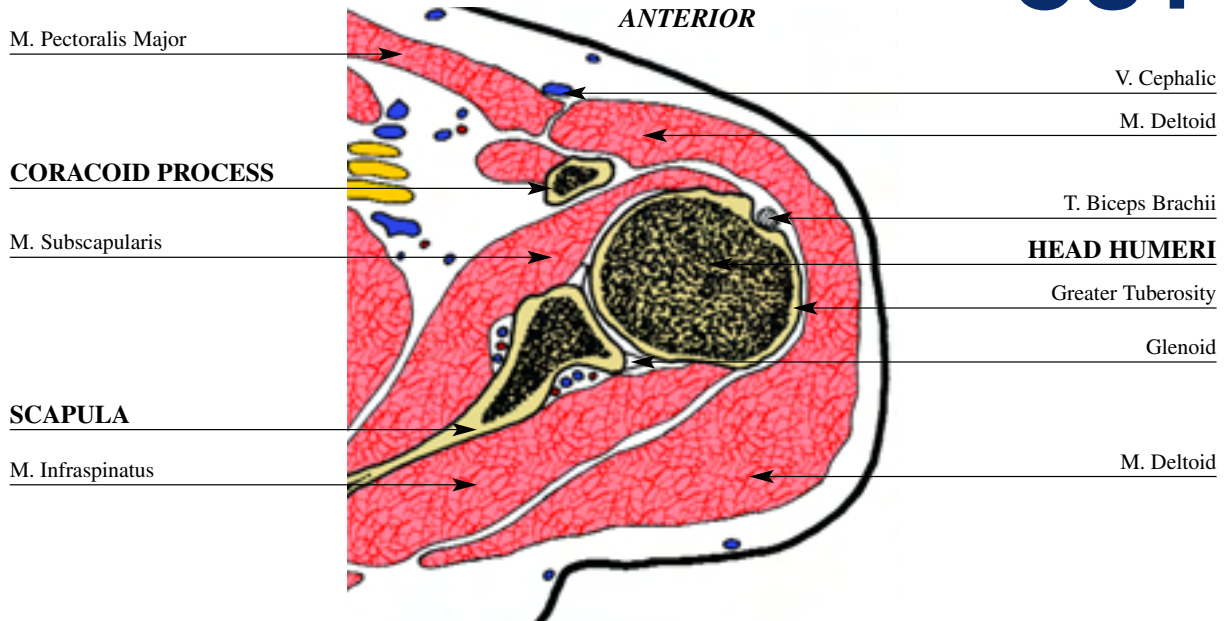
- 1** Placement of two half pins in the humeral head, is performed at the anterolateral site. The first runs transversely and the second from antero lateral to postero medial, posterior to the intertubercular groove.
- 2** The placement of half pins at the upper one third of the humeral diaphysis is carried out on the anterolateral side. At this application site, one or two pins may be used according to the needs of the individual case. When inserting the anterior half pin, care must be taken to avoid the radial N.
- 3** A fixation wire can be placed from anterolateral to posteromedial traversing both the biceps and triceps M. A half pin is inserted anterior to the radial N from anterolateral to posteromedial.
- 4** A fixation wire can be placed in an oblique direction from anterolateral to posteromedial. This traverses both the biceps and triceps M. A fixation half pin is placed medial to the radial N from posterior to anterior.
- 5** A fixation wire can be placed in a medial-oblique direction from anterolateral to posteromedial. This wire traverse both the biceps and triceps M. Extreme care must be taken with insertion of this wire. A fixation half pin is placed posteriorly, behind the radial N from posterolateral to anteromedial at an angle of forty degrees to the sagittal plane. A second half pin can be placed from posterior to anterior.
- 6** Wire placement at this level is best achieved in the coronal plane. The reasons for this are that the bone is oriented in this axis, and this plane avoids the dorsal and ventral neurovascular structures. Two wires may be inserted at this point. The first wire is inserted via the medial epicondyle. During this insertion, the ulnar N. must be palpated and pushed laterally out of harm's way. This wire should exit as anterior as is possible on the lateral condyle. The second wire is inserted more anteriorly on the medial epicondyle and directed further posteriorly. The crossing angle between these two wires should be between 20° and 30° . For additional fixation, one or two half pins may be placed adjacent to the lateral epicondyle, from posterolateral to anteromedial

INSERTION WIRES AND HALF-PINS - LEFT



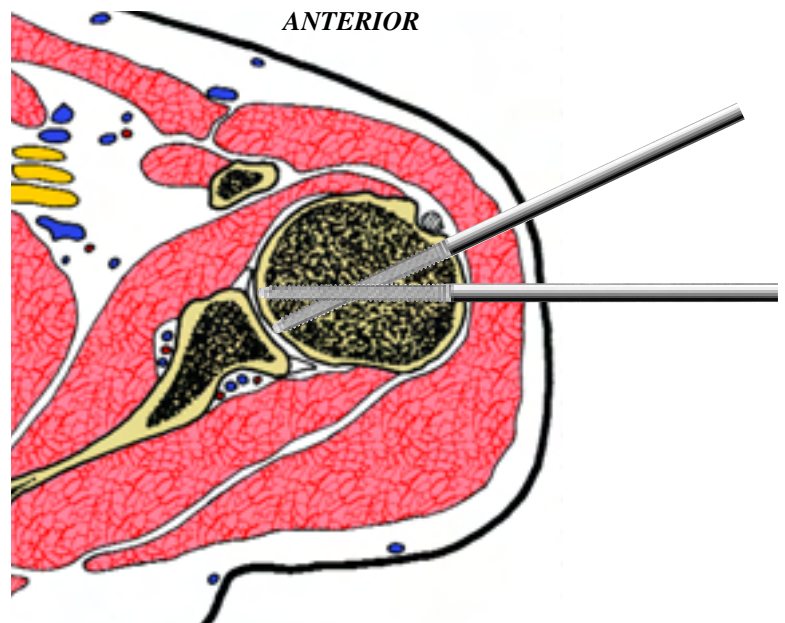
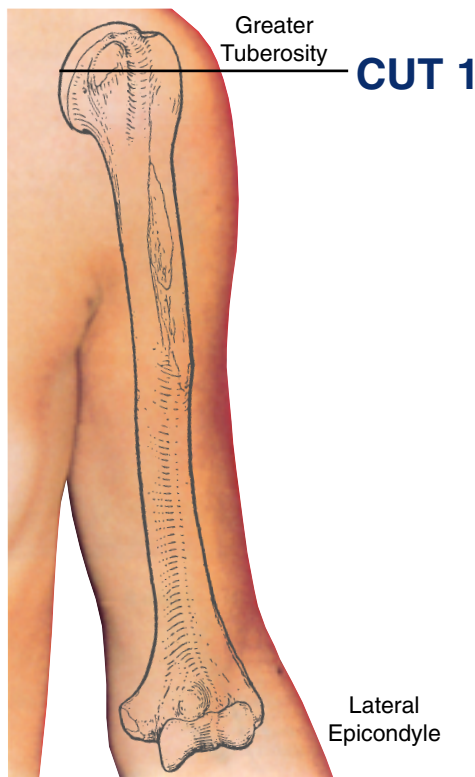
HUMERUS left

CUT 1



This cross sectional cut is taken at the level of the lesser tuberosity. The humerus is 90% cancellous at this point and presents tuberosities anteriorly and laterally. The tuberosities are separated anteriorly by a well-defined intertubercular groove, which transmits the long head of biceps. On the lateral surface of the humerus, underneath the cover of the deltoid, lies the

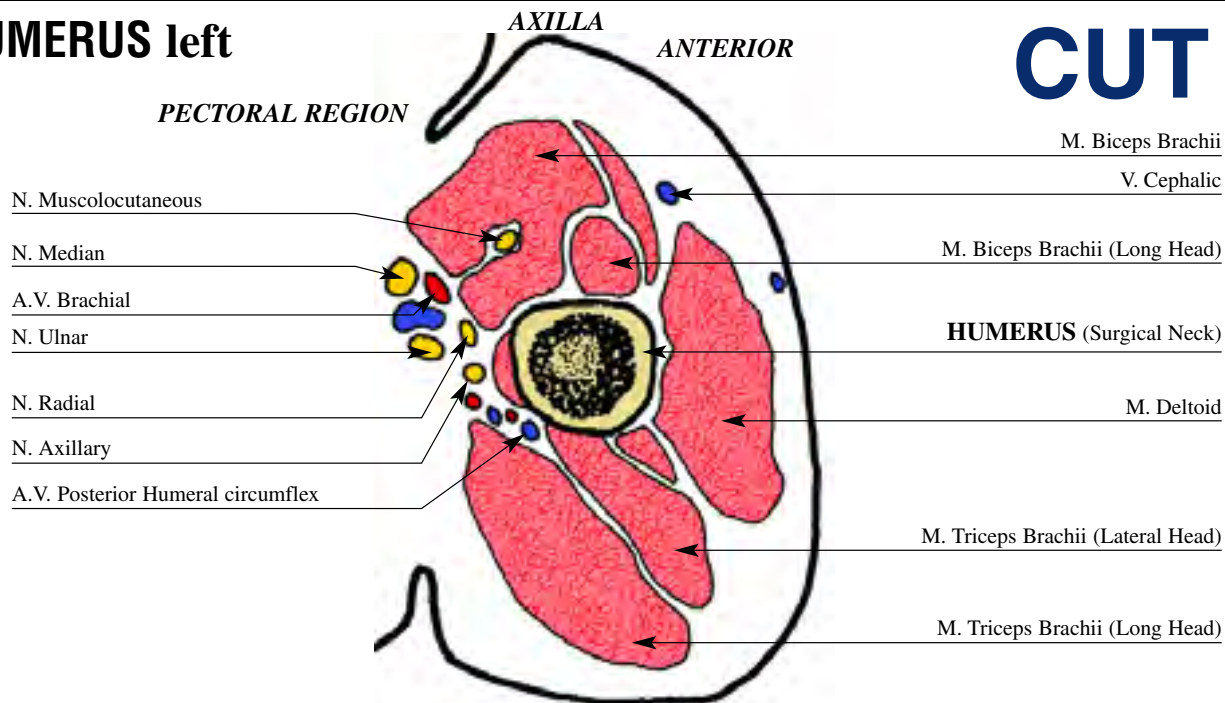
posterior humeral circumflex A, and the axillary N. Posteriorly, teres minor and infraspinatus cover the humerus. The postero medial half of this humeral section is covered by articular cartilage. The deltoid M. envelops the portion of the humerus not covered with articular cartilage. All of the critical neurovascular elements are now inferior and medial.



Placement of two half pins in the humeral head, is performed at the anterolateral site. The first runs transversely and the second from antero lateral to postero medial, posterior to the intertubercular groove.
 Note: be careful not to penetrate the articular surface.

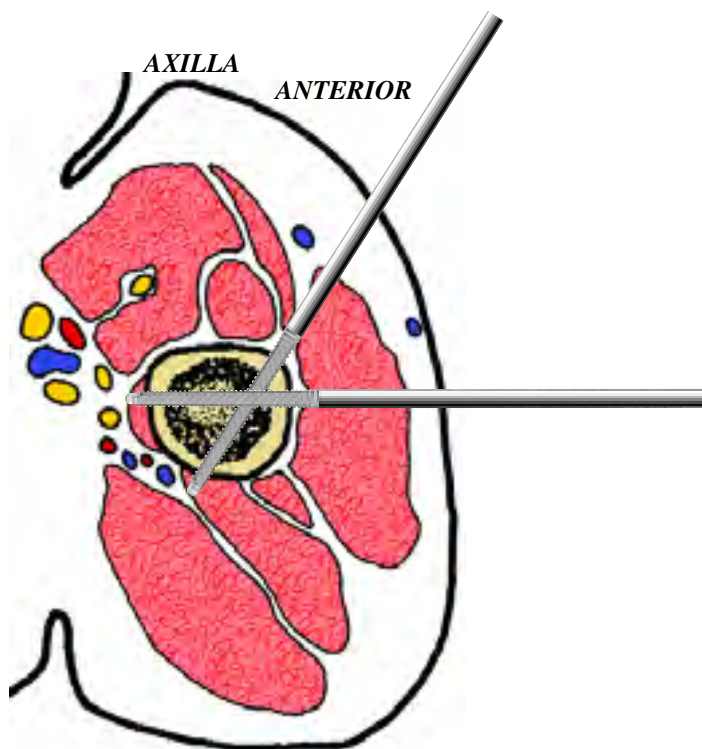
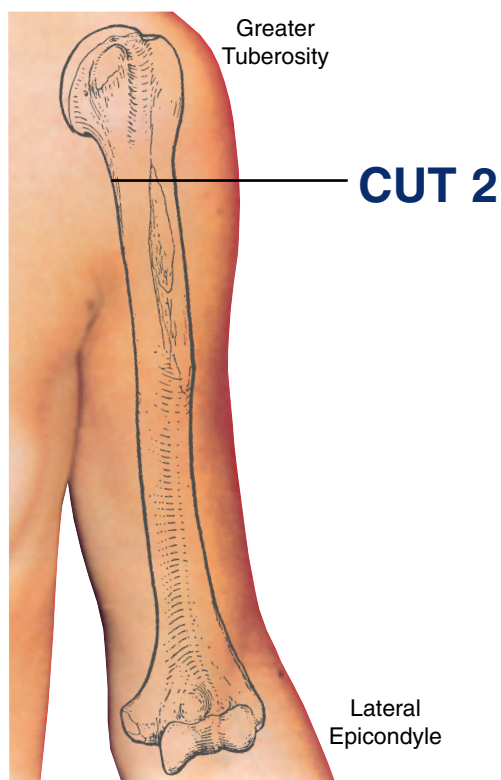
HUMERUS left

CUT 2



This cross section is at the midpoint between the axillary fold and the head of the humerus. It is a more commonly used site than the first cross section. The humerus is beginning to expand into the proximal metaphysis and is covered laterally by the deltoid. The pectoralis major lies anteromedial and the long head

of the triceps, posteriorly. The majority of the neurovascular structures are located medial to the humerus. Those not in this position include the posterior humeral circumflex A.V. and the axillary N. accompanying the bundle. These structures are located posterior and lateral to the humerus.

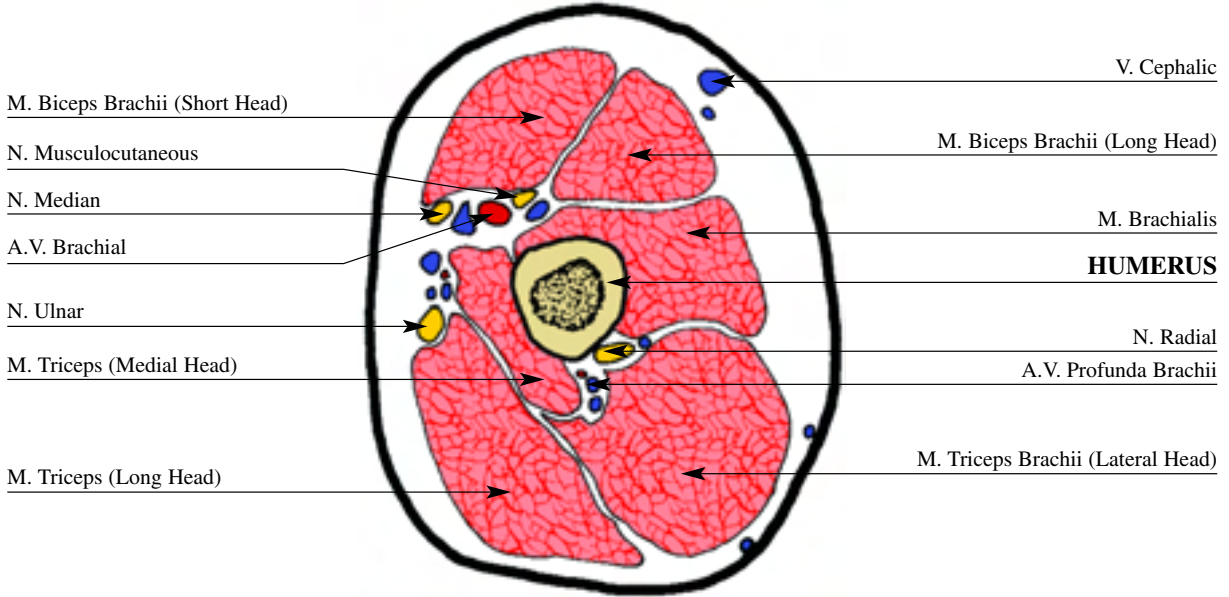


The placement of half pins at the upper one third of the humeral diaphysis is carried out on the anterolateral side. At this application site, one or two pins may be used according to the needs of the individual case. When inserting the anterior half pin, care must be taken to avoid the radial N.

HUMERUS left

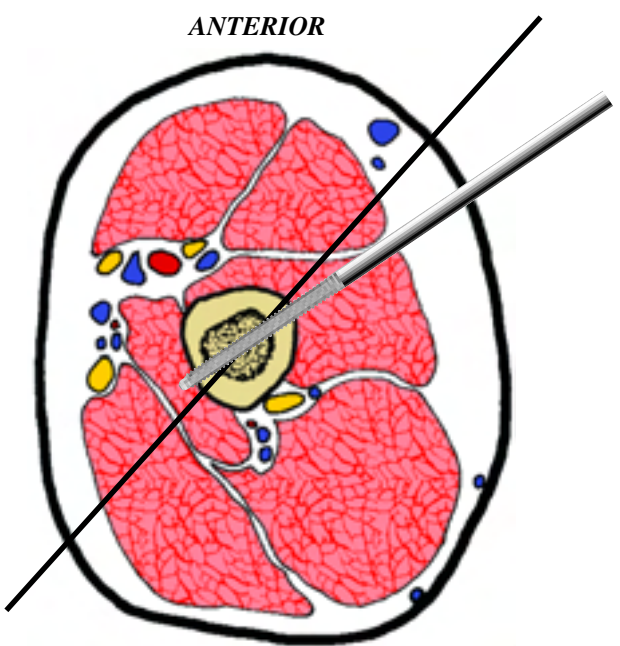
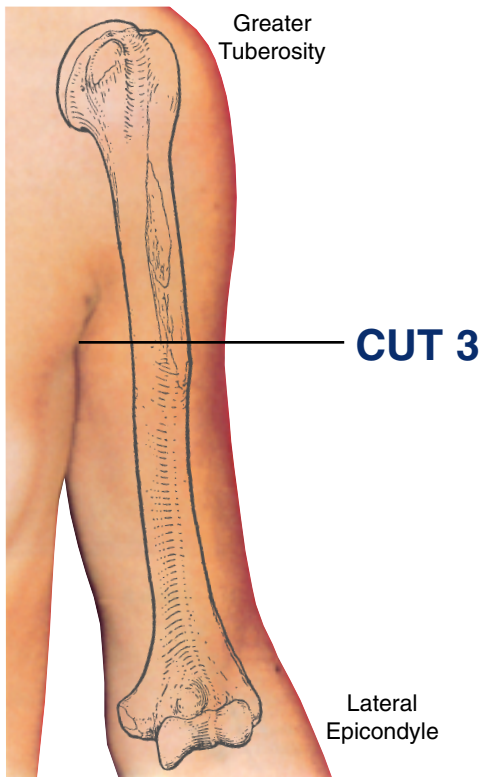
CUT 3

ANTERIOR



This cross sectional cut is just distal to the axillary fold. The brachial A. can be readily palpated medially. Anteriorly in the deltopectoral groove lies the cephalic vein, which may be visible. The humerus is centralized within the extremity and surrounded by muscle.

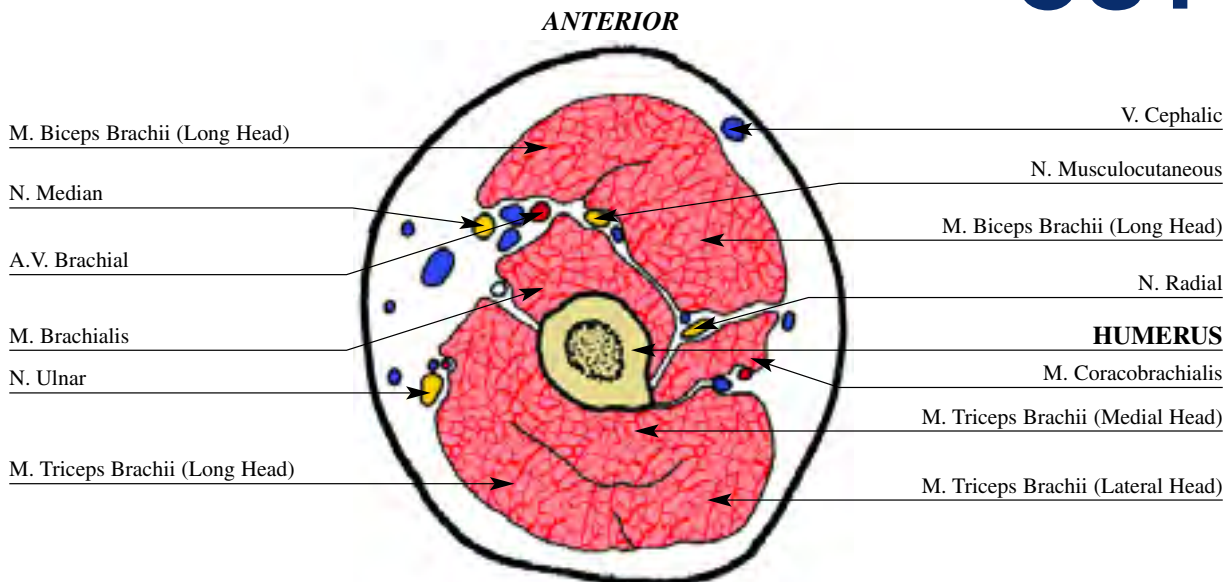
With the exception of the radial N., all of the neurovascular elements are medial. The musculocutaneous N. is most anterior structure between the coracobrachialis and the biceps. The ulnar N. is the most posterior structure as it sits on the medial head of the triceps. The radial N. is directly posterior.



A fixation wire can be placed from anterolateral to posteromedial traversing both the biceps and triceps M. A half pin is inserted anterior to the radial N from anterolateral to posteromedial.

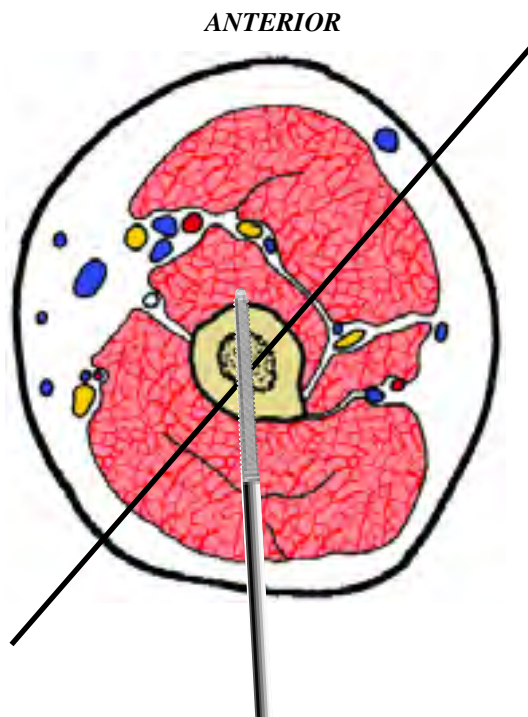
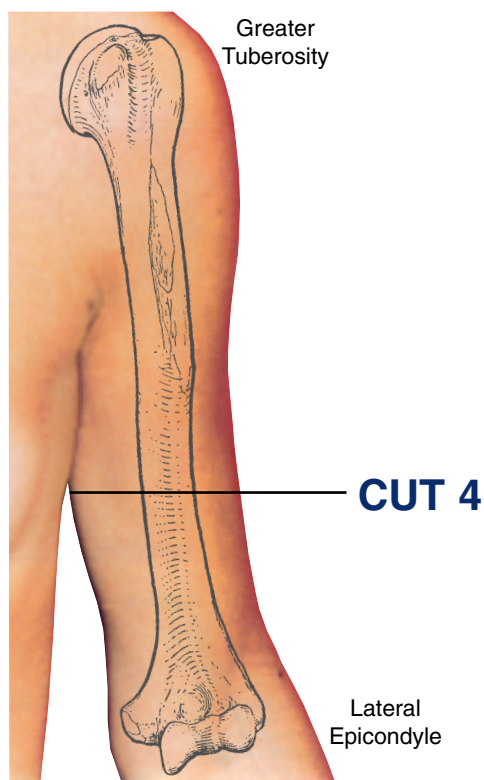
HUMERUS left

CUT 4



This cross section is at the level of the distal third of the humerus. The neurovascular structures lie in the same position as in cut #3 i.e. (medial). There is a moderate amount of dis-

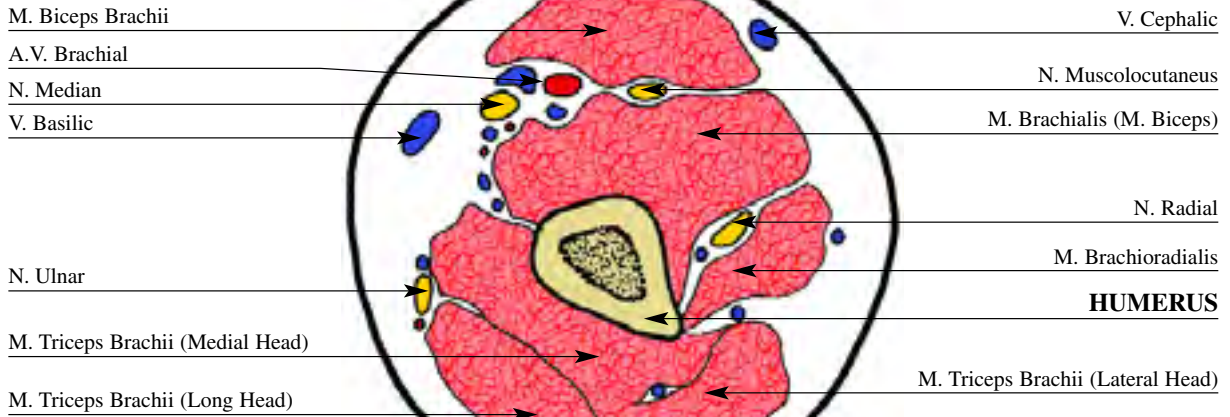person between them, with the exceptions of the radial N., which are more anterolateral and the musculocutaneous N. that is more anterior.



A fixation wire can be placed in an oblique direction from anterolateral to posteromedial. This traverses both the biceps and triceps M. A fixation half pin is placed medial to the radial N. from posterior to anterior.

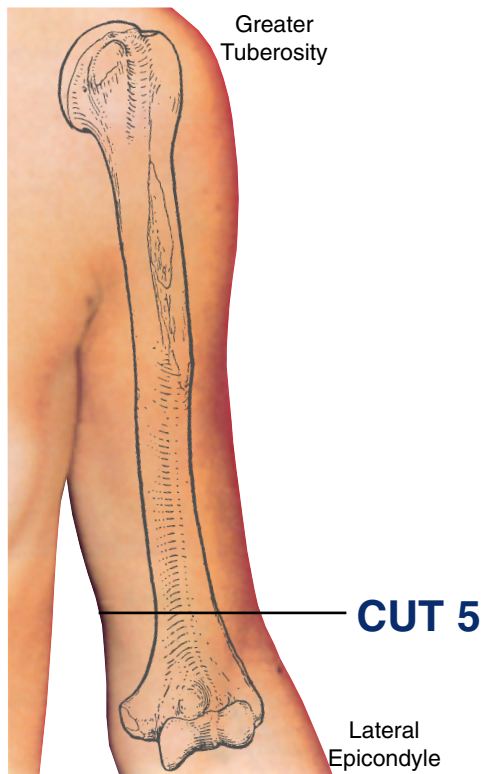
HUMERUS left

ANTERIOR

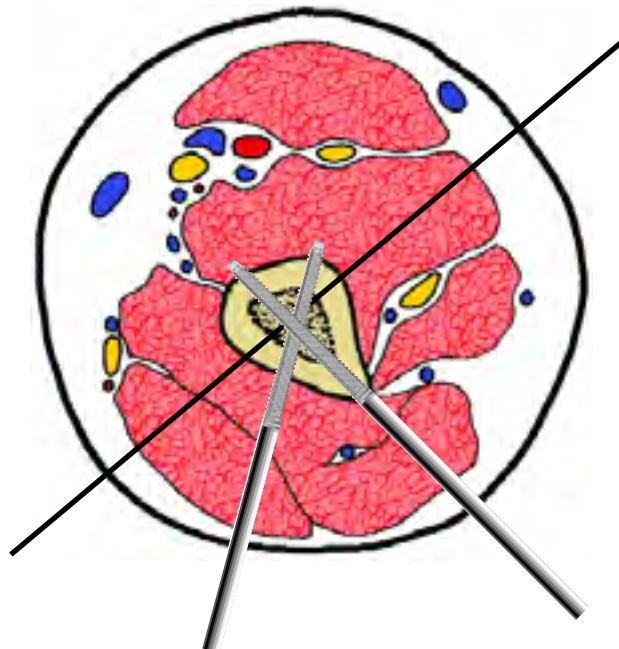


This cross section is taken proximal to the elbow flexion crease. The humerus is triangular in shape and cortical through 50% of its diameter. Palpable structures include the biceps anteriorly and the triceps posteriorly. On the medial side, these two muscles converge to form a deep sulcus. This sulcus contains the

brachial A. V., the median N. and the medial cutaneous N. of the forearm. The ulnar N. is located slightly more medial outside this sulcus. On the lateral side there is only the radial N. which is situated on top of the brachialis and underneath the brachioradialis.



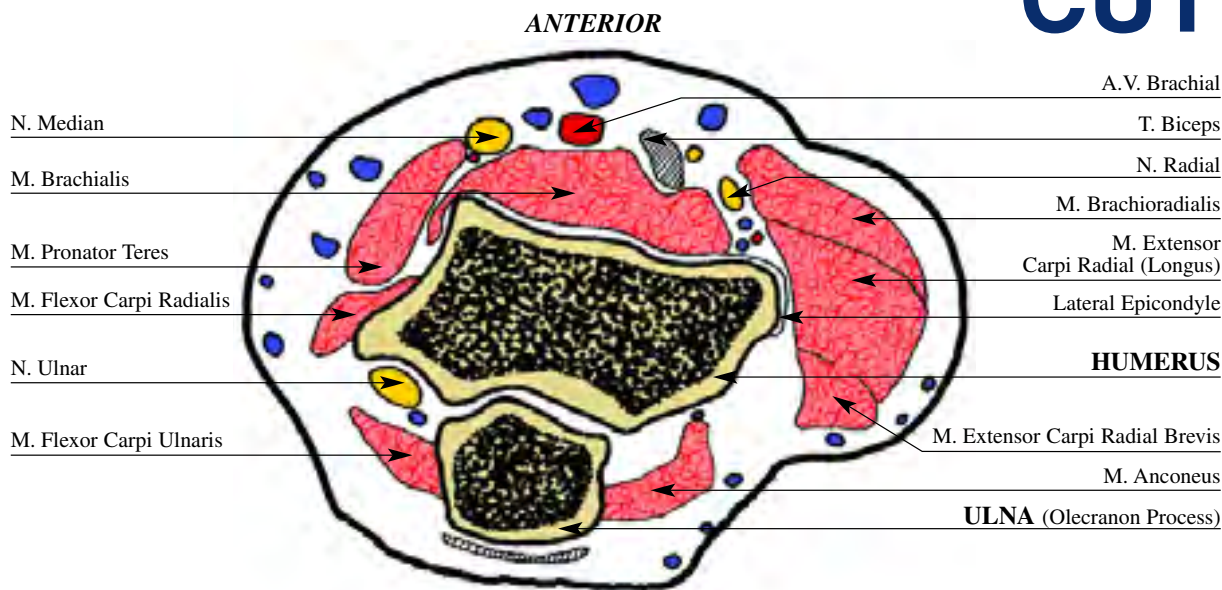
ANTERIOR



A fixation wire can be placed in a medial-oblique direction from anterolateral to posteromedial. This wire traverse both the biceps and triceps M. Extreme care must be taken with insertion of this wire. A fixation half pin is placed posteriorly, behind the radial N from posterolateral to anteromedial at an angle of forty degrees to the sagittal plane. A second half pin can be placed from posterior to anterior.

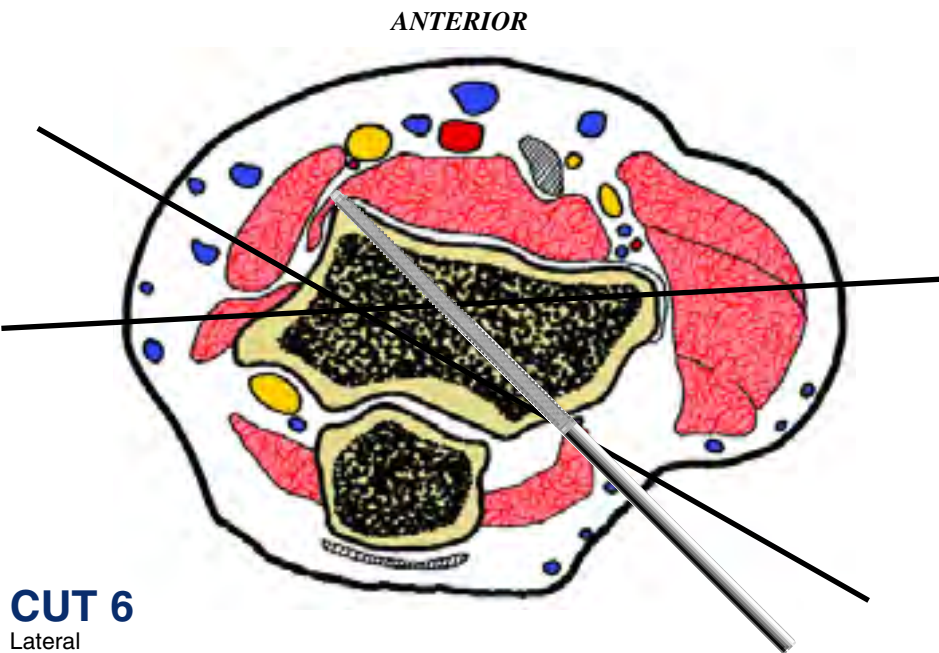
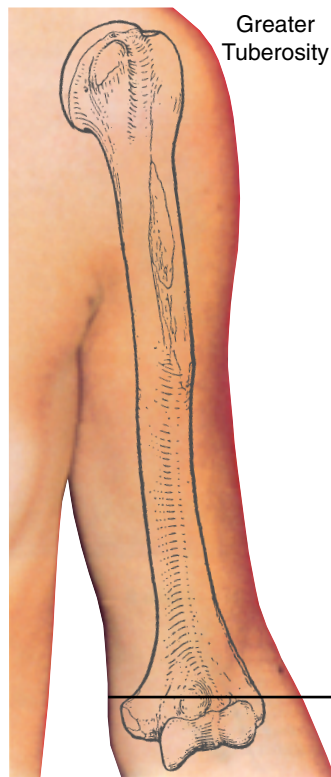
HUMERUS left

CUT 6



This cross sectional cut is at the level of the flexion crease of the elbow, transecting the distal humerus at the level of the medial epicondyle. Here, the humerus is cancellous in nature and flattened along its frontal border. The ulnar N. is the most critical structure to note at this level. It has migrated dorsal to

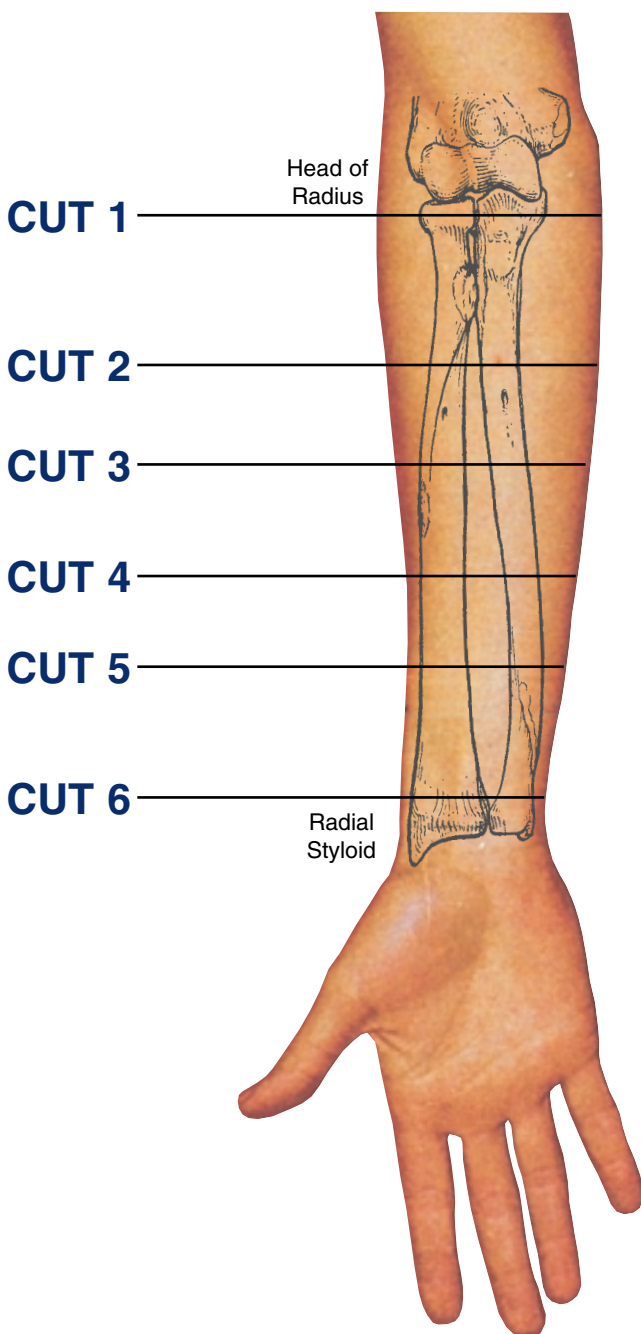
the axis of the humerus, and lies in the ulnar groove posterior to the medial epicondyle. The radial and ulnar A. have joined to form the brachial A. This runs with the median N. anterior to the medial condyle of the humerus. The radial N. rests on top of the brachialis M., anterior to the lateral condyle.



Wire placement at this level is best achieved in the coronal plane. The reasons for this are that the bone is oriented in this axis, and this plane avoids the dorsal and ventral neurovascular structures. Two wires may be inserted at this point. The first wire is inserted via the medial epicondyle. During this insertion, the ulnar N. must be palpated and pushed laterally out of harm's way. This wire should exit as anterior as is possible on the lateral condyle. The second wire is inserted more anteriorly on the medial epicondyle and directed further posteriorly. The crossing angle between these two wires should be between 20° and 30°. For additional fixation, one or two half pins may be placed adjacent to the lateral epicondyle, from posterolateral to anteromedial.

Levels of the anatomical cuts of the upper extremity

RADIUS AND ULNA right



1 Isolated fixation of the radius is difficult at this level because of the anterolateral vessels and the medial ulna. It can be done with a half pin inserted from postero medial to antero lateral. Fixation of the two bones is done with a wire from antero lateral to postero medial. Isolated ulnar fixation is much simpler and can be done with one transverse wire and a second wire from antero medial to postero lateral, posterior to the ulnar nerve. Fixation with half pins can be done posteriorly at an angle of 20° to the sagittal plane.

2 Isolated ulnar fixation can be done with a transverse wire (parallel to the coronal plane) and a half pin from posterior to anterior. Isolated radial fixation can be performed with a wire from anterior to posterior and a half pin from posterolateral to antero medial, angulated 20° to the sagittal plane.

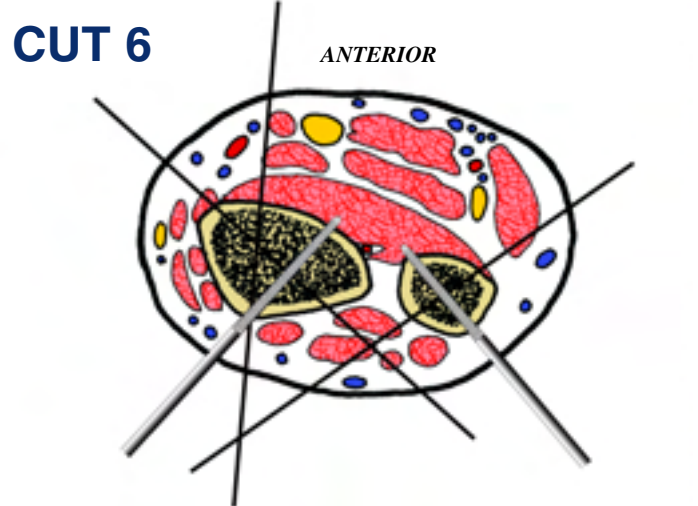
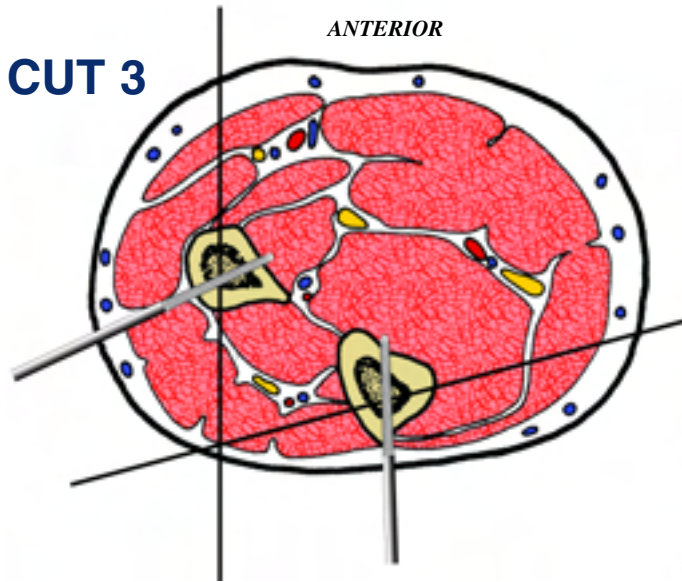
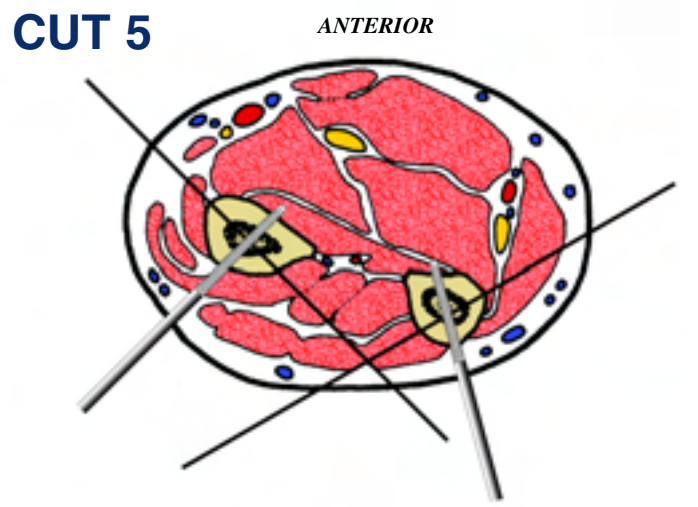
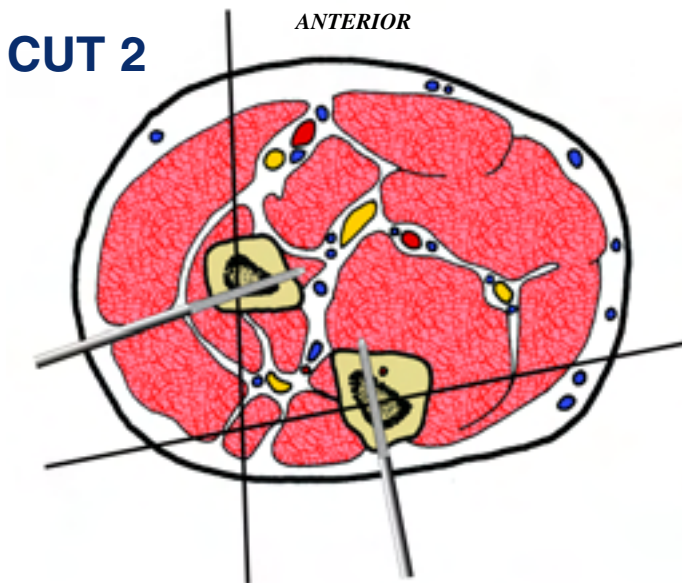
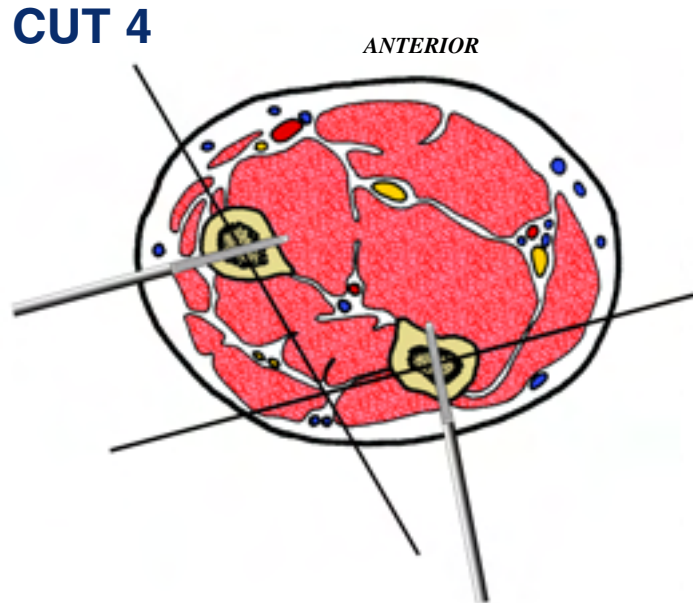
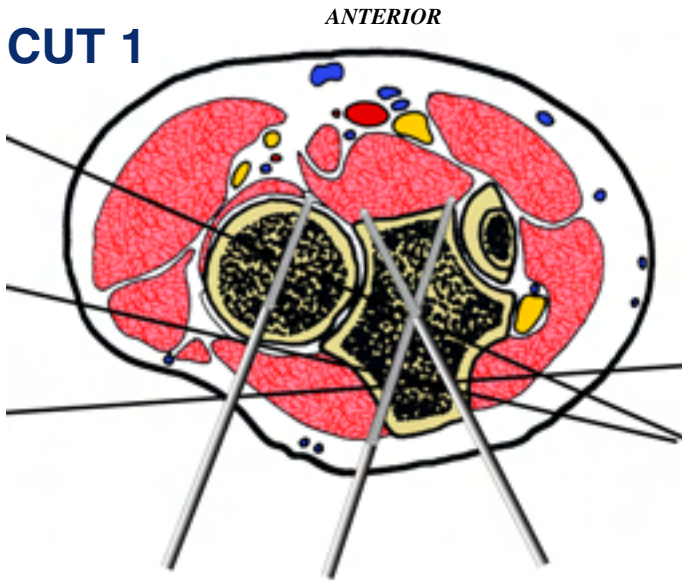
3 Isolated radial fixation can be carried out with a wire directed from anterior to posterior. A half pin can be inserted from posterolateral to anteromedial at an angle approximating 20 degrees to the coronal plane. Fixation of the ulna can be performed with a wire from anteromedial to posterolateral, angulated 20° to the coronal plane, and a half pin from posterior to anterior.

4 Isolated radial fixation can be carried out with a wire directed from anterolateral to posteromedial, angulated 30° to the sagittal plane. A half pin can be fixed in a posterolateral position, perpendicular to the previous wire. Fixation of the ulna can be performed with a wire from anteromedial to posterolateral, angulated 20° to the coronal plane, and a half pin from posteromedial to anterolateral, angulated 10° to the sagittal plane.

5 Isolated radial fixation can be carried out with a wire directed from anterolateral to posteromedial, angulated 40° to the coronal plane. A half pin can be inserted from a posterolateral position, perpendicular to the previous wire. Ulna fixation is performed with a wire from anteromedial to posterolateral angulated 40° to the coronal plane and a half pin from posteromedial to anterolateral, angulated 15° to the sagittal plane.

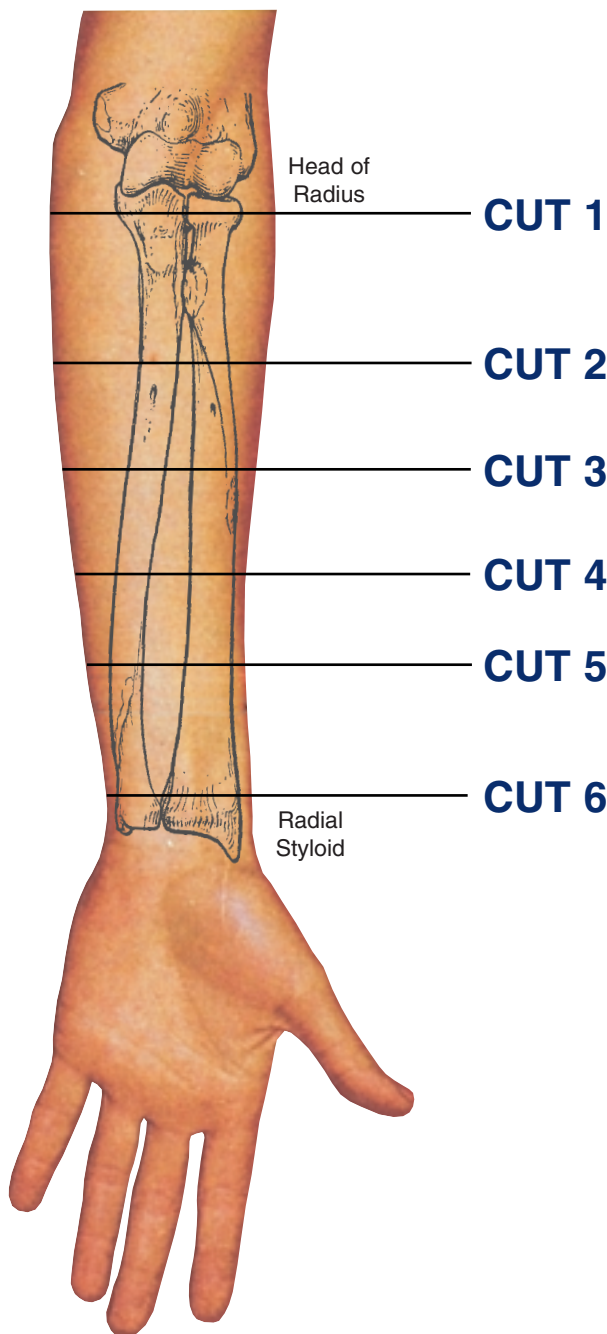
6 Ulnar fixation is performed with a wire directed from antero-medial to posterolateral angulated 45° to the sagittal plane and a half pin directed from posteromedial to anterolateral, perpendicular to the previous wire. The radius can be fixed with one wire directed from anterolateral to posteromedial angulated 45° with the coronal plane and a second wire inserted from anterior to posterior, between the flexor carpi radialis and the median nerve, using the open technique. A half pin is inserted from posterolateral to anteromedial, perpendicular to the first wire.

INSERTION WIRES AND HALF-PINS - RIGHT



Levels of the anatomical cuts of the upper extremity

RADIUS AND ULNA left



1 Isolated fixation of the radius is difficult at this level because of the anterolateral vessels and the medial ulna. It can be done with a half pin inserted from postero medial to antero lateral. Fixation of the two bones is done with a wire from antero lateral to postero medial. Isolated ulnar fixation is much simpler and can be done with one transverse wire and a second wire from antero medial to postero lateral, posterior to the ulnar nerve. Fixation with half pins can be done posteriorly at an angle of 20° to the sagittal plane.

2 Isolated ulnar fixation can be done with a transverse wire (parallel to the coronal plane) and a half pin from posterior to anterior. Isolated radial fixation can be performed with a wire from anterior to posterior and a half pin from posterolateral to antero medial, angulated 20° to the sagittal plane.

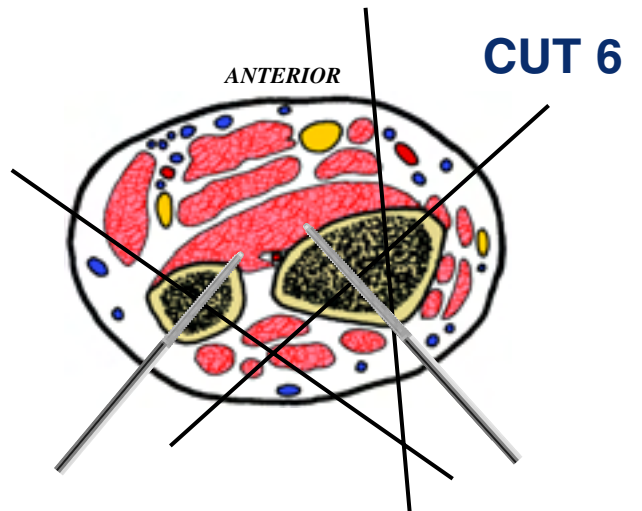
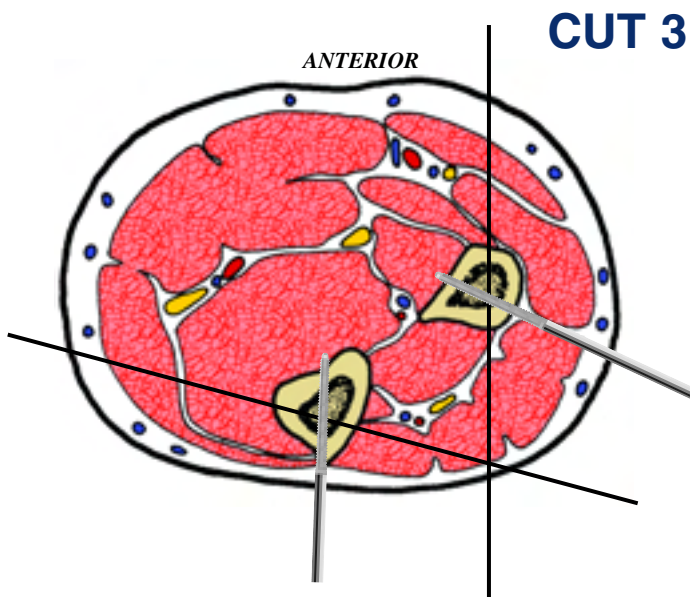
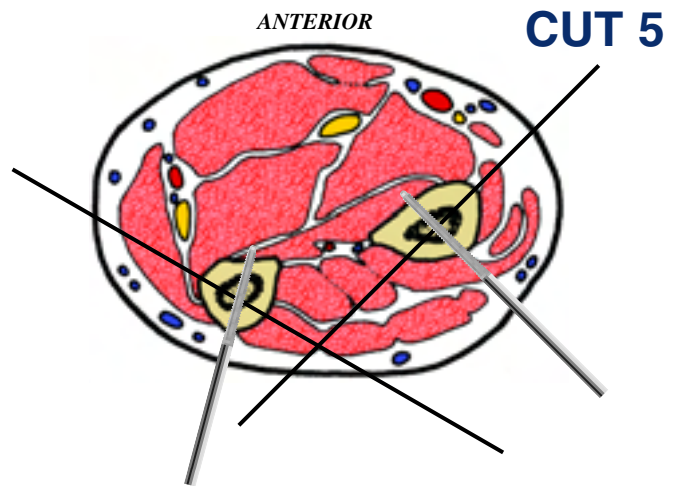
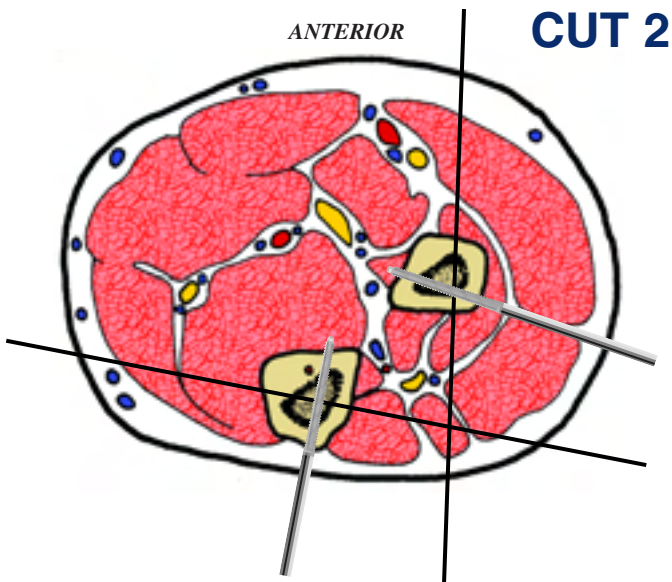
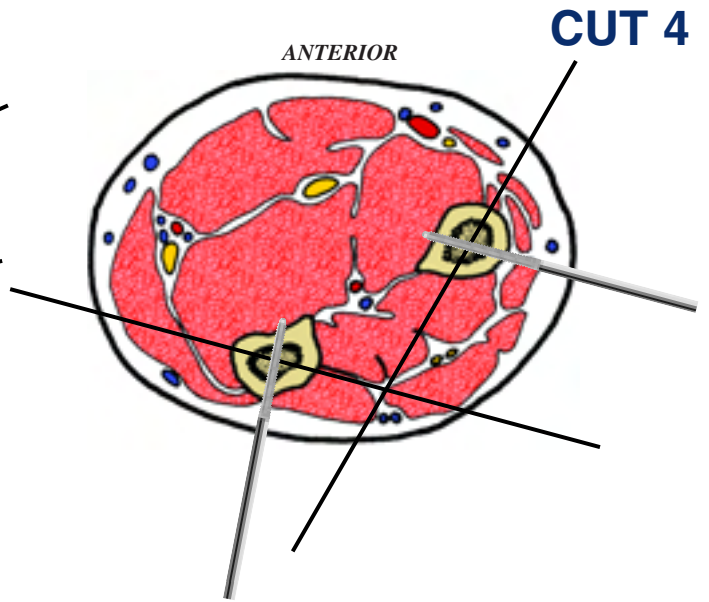
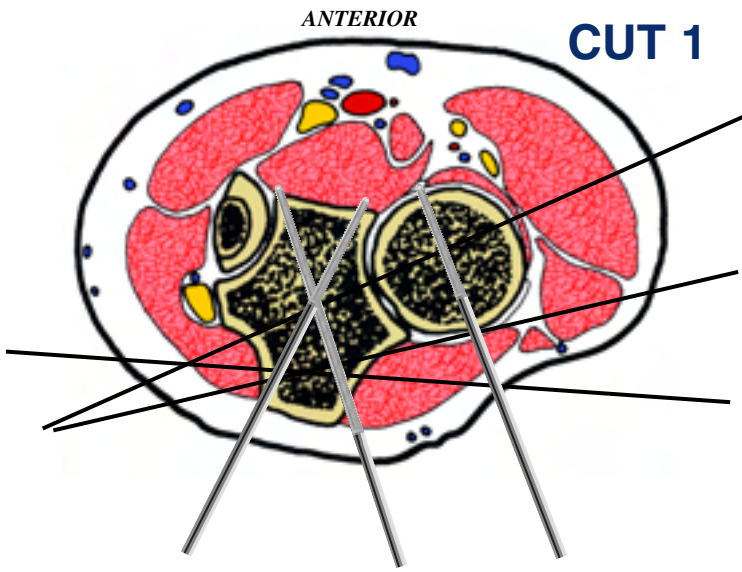
3 Isolated radial fixation can be carried out with a wire directed from anterior to posterior. A half pin can be inserted from posterolateral to anteromedial at an angle approximating 20 degrees to the coronal plane. Fixation of the ulna can be performed with a wire from anteromedial to posterolateral, angulated 20° to the coronal plane, and a half pin from posterior to anterior.

4 Isolated radial fixation can be carried out with a wire directed from anterolateral to posteromedial, angulated 30° to the sagittal plane. A half pin can be fixed in a posterolateral position, perpendicular to the previous wire. Fixation of the ulna can be performed with a wire from anteromedial to posterolateral, angulated 20° to the coronal plane, and a half pin from posteromedial to anterolateral, angulated 10° to the sagittal plane.

5 Isolated radial fixation can be carried out with a wire directed from anterolateral to posteromedial, angulated 40° to the coronal plane. A half pin can be inserted from a posterolateral position, perpendicular to the previous wire. Ulna fixation is performed with a wire from anteromedial to posterolateral angulated 40° to the coronal plane and a half pin from posteromedial to anterolateral, angulated 15° to the sagittal plane.

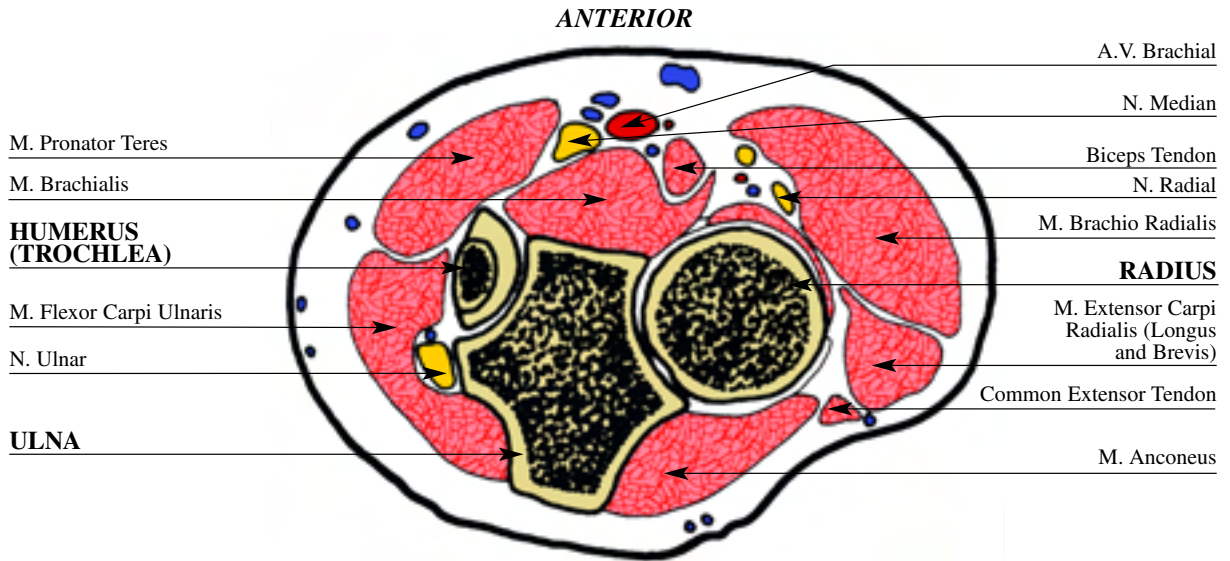
6 Ulnar fixation is performed with a wire directed from antero-medial to posterolateral angulated 45° to the sagittal plane and a half pin directed from posteromedial to anterolateral, perpendicular to the previous wire. The radius can be fixed with one wire directed from anterolateral to posteromedial angulated 45° with the coronal plane and a second wire inserted from anterior to posterior, between the flexor carpi radialis and the median nerve, using the open technique. A half pin is inserted from posterolateral to anteromedial, perpendicular to the first wire.

INSERTION WIRES AND HALF-PINS - LEFT



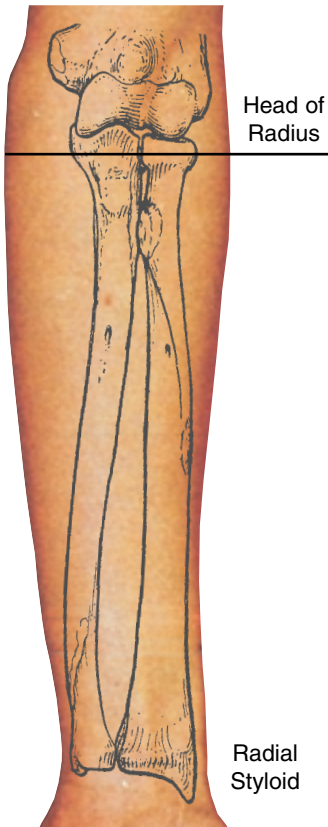RADIUS and ULNA left

CUT 1

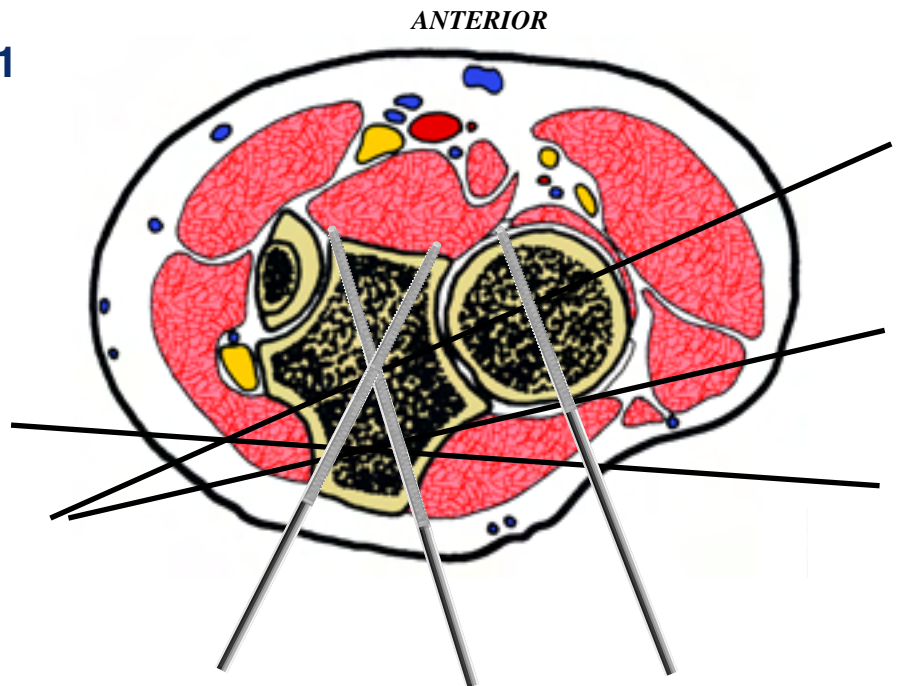


In this cross section the ulnar N. runs medial to the ulna at the point of confluence of the flexor carpi ulnaris, the flexor digi-

torum superficialis and the pronator teres. The brachial A. has moved laterally and now runs along side the median N.



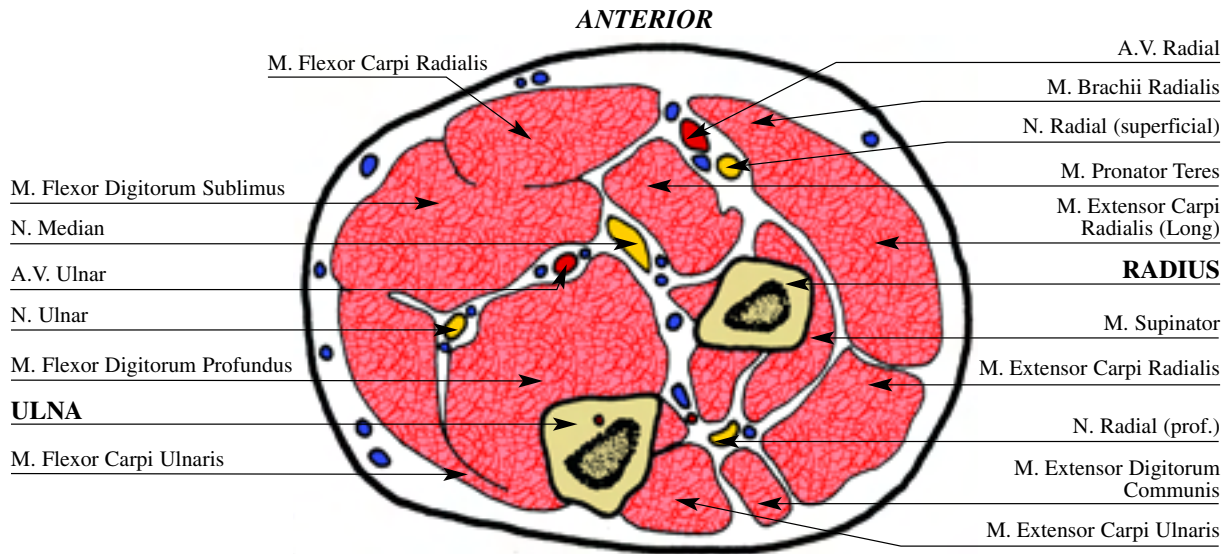
CUT 1



Isolated fixation of the radius is difficult at this level because of the anterolateral vessels and the medial ulna. It can be done with a half pin inserted from postero medial to antero lateral. Fixation of the two bones is done with a wire from antero lateral to postero medial. Isolated ulnar fixation is much simpler and can be done with one transverse wire and a second wire from antero medial to postero lateral, posterior to the ulnar nerve. Fixation with half pins can be done posteriorly at an angle of 20° to the sagittal plane.

RADIUS and ULNA left

CUT 2

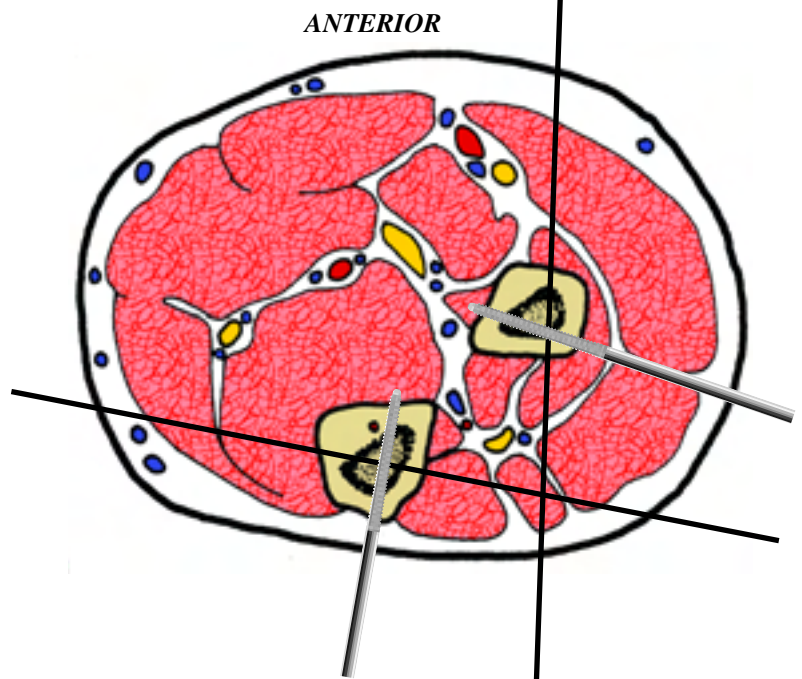
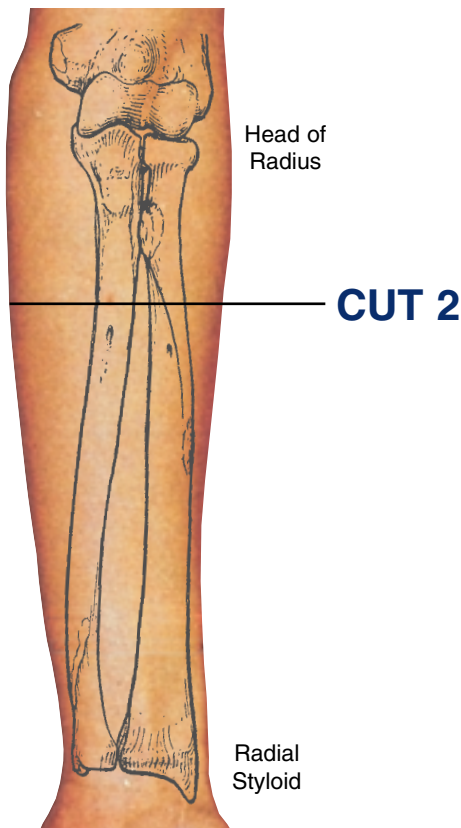


This cross sectional cut is performed distal to the flexor crease of the elbow. Here bony landmarks are restricted to the subcutaneous border of the ulna as the remainder of the forearm is covered with muscle. The ulnar neurovascular bundle is positioned directly volar to the ulna between the flexor carpi ulnaris and the flexor profundus. The median N. is volar to the medial

portion of the radius, and is covered by the flexor digitorum sublimis and flexor pollicis longus.

The radial A. and N. are situated between the flexor carpi radialis and the brachioradialis. The lateral cutaneous nerve of the forearm can be found in the subcutaneous plane along the anterolateral portion of the forearm.

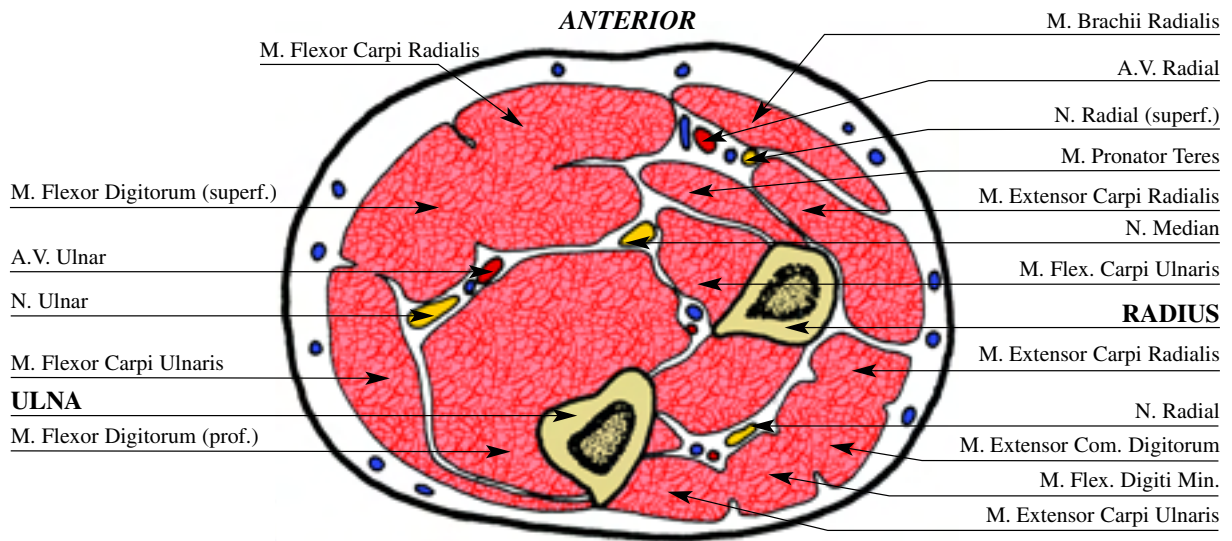
The ulnar N. runs volar to the ulna at the point of confluence of the flexor carpi ulnaris, the superficial flexors and the deep flexors. The posterior interosseous N. and superficial radial N. run together with the radial A.V.



Isolated ulnar fixation can be done with a transverse wire (parallel to the coronal plane) and a half pin from posterior to anterior. Isolated radial fixation can be performed with a wire from anterior to posterior and a half pin from posterolateral to antero medial, angulated 20° to the sagittal plane.

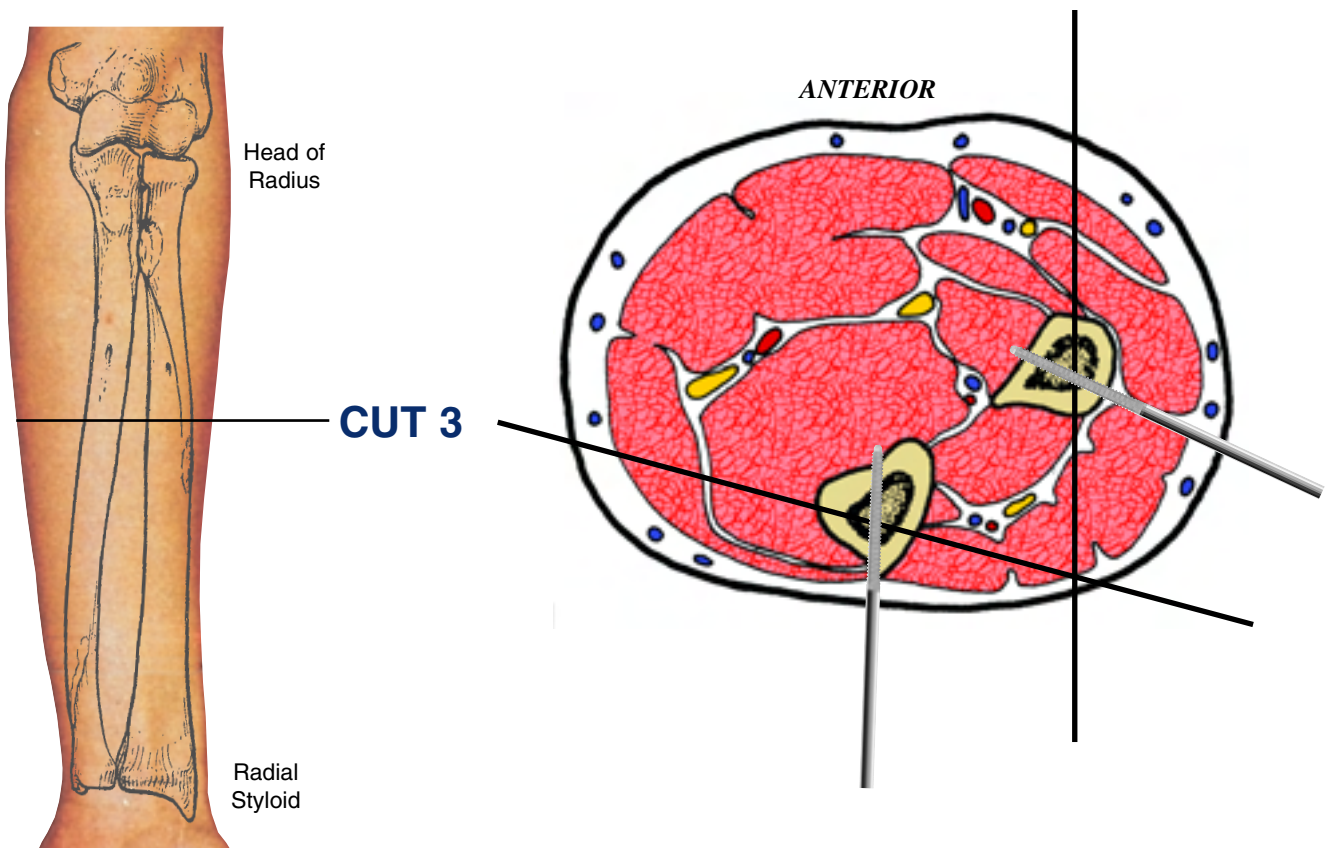
RADIUS and ULNA left

CUT 3



In this cross section each of the three major neurovascular elements have assumed a deep position protected by the overlying muscles. The superficial radial N. and radial A. are volar and lateral beneath the brachioradialis. The median N. is volar and

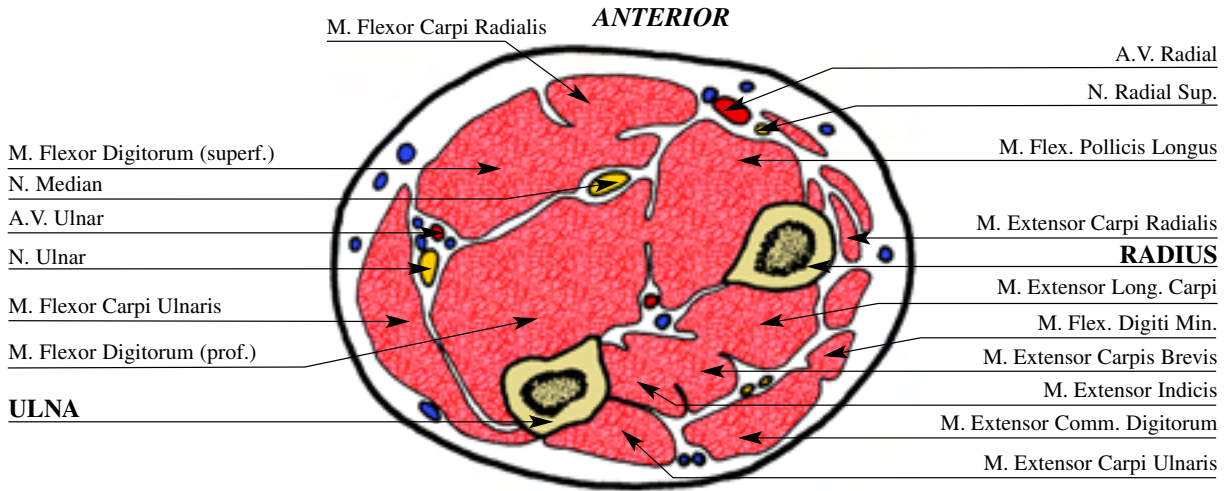
central between the superficial and deep flexors of the fingers. The ulnar A.V. and N. remain covered by the flexor carpi ulnaris. The anterior interosseous artery has maintained its position on the volar surface of the interosseous membrane.



Isolated radial fixation can be carried out with a wire directed from anterior to posterior. A half pin can be inserted from posterolateral to anteromedial at an angle approximating 20 degrees to the coronal plane. Fixation of the ulna can be performed with a wire from anteromedial to posterolateral, angulated 20° to the coronal plane, and a half pin from posterior to anterior.

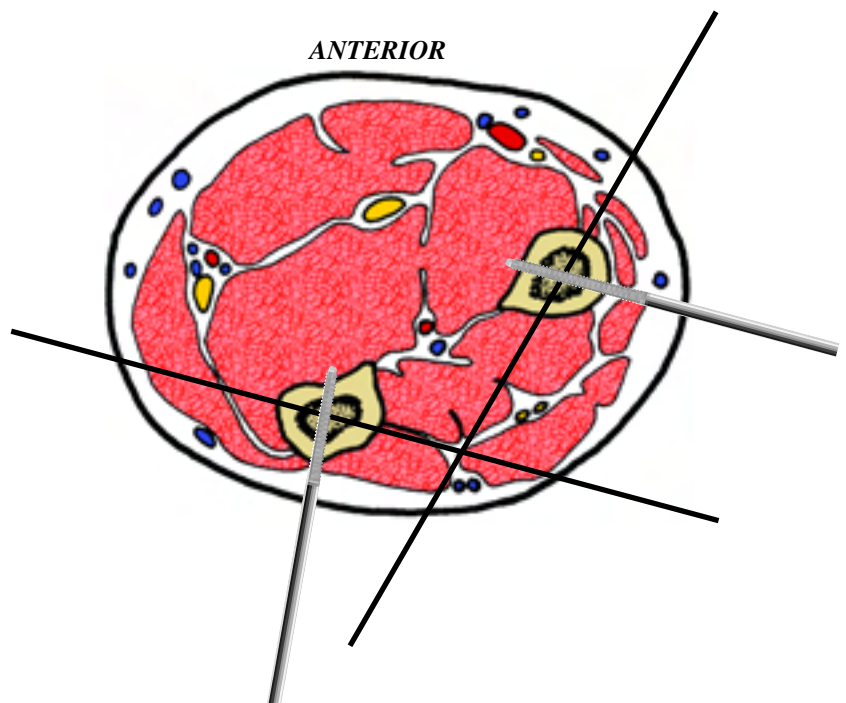
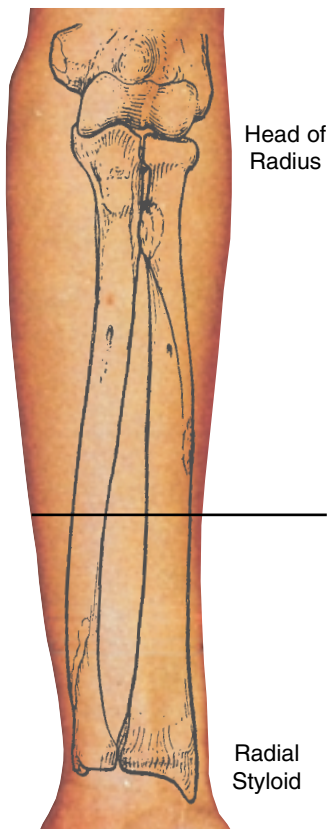
RADIUS and ULNA left

CUT 4



This cross sectional cut is taken at the midpoint between the flexor creases of the elbow and wrist. This level represents the apex of radial bowing. The two bones are maximally separated at this point. The three major neurovascular elements have assumed a deep position protected by overlying muscles. The

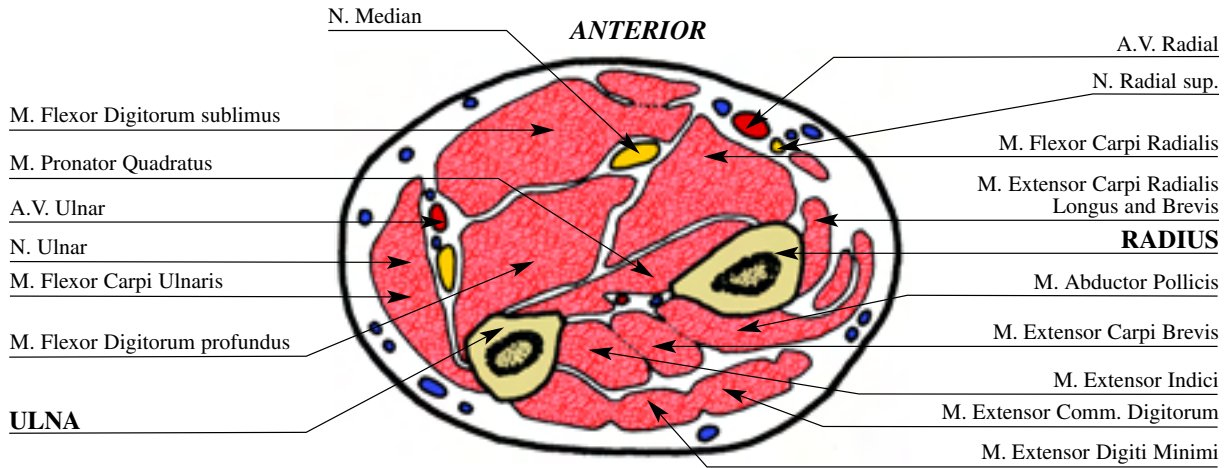
superficial radial N. and radial A. are volar and lateral underneath the brachioradialis. The median N. is volar and central between the superficial and deep flexors of the fingers. The ulnar A.V. and N. remain under the cover of the flexor carpi ulnaris. The anterior interosseous artery has maintained its position on the volar surface of the interosseous membrane.



Isolated radial fixation can be carried out with a wire directed from anterolateral to posteromedial, angulated 30° to the sagittal plane. A half pin can be fixed in a posterolateral position, perpendicular to the previous wire. Fixation of the ulna can be performed with a wire from anteromedial to posterolateral, angulated 20° to the coronal plane, and a half pin from posteromedial to anterolateral, angulated 10° to the sagittal plane.

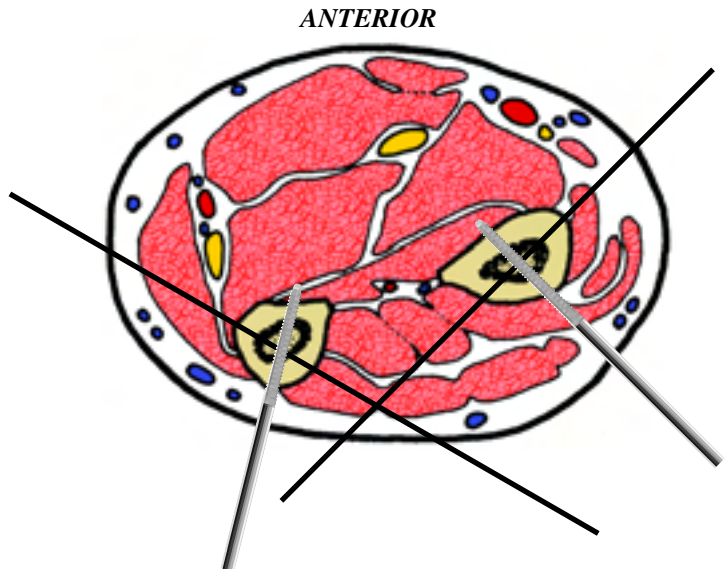
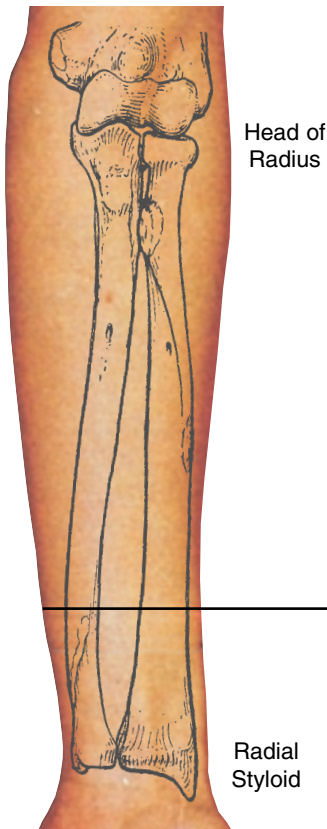RADIUS and ULNA left

CUT 5



In this cross sectional cut the superficial radial N. lies subcutaneously over the abductor pollicis longus. The radial A. lies superficially and can be found slightly lateral to the flexor carpi radialis. The median N. is on the medial side of the radial wrist flexor,

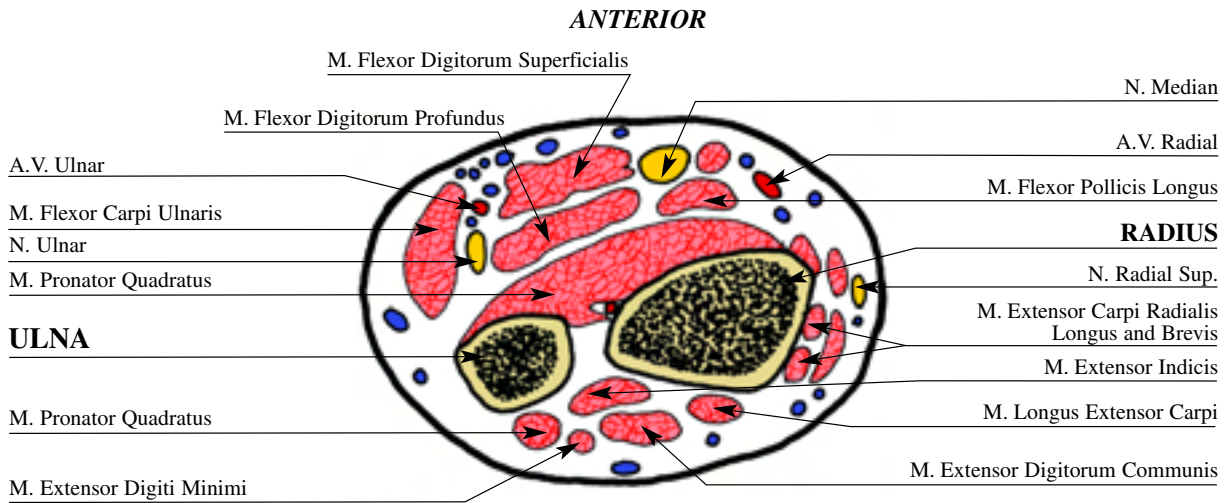
between it and the flexor digitorum sublimus. The ulnar A.V. and N. are volar and medial under the increasing mass of the flexor carpi ulnaris. The terminal branches of the anterior interosseous N. are deeply located on the ulnar border of the radius.



Isolated radial fixation can be carried out with a wire directed from anterolateral to posteromedial, angulated 40° to the coronal plane. A half pin can be inserted from a posterolateral position, perpendicular to the previous wire. Ulna fixation is performed with a wire from anteromedial to posterolateral angulated 40° to the coronal plane and a half pin from posteromedial to anterolateral, angulated 15° to the sagittal plane.

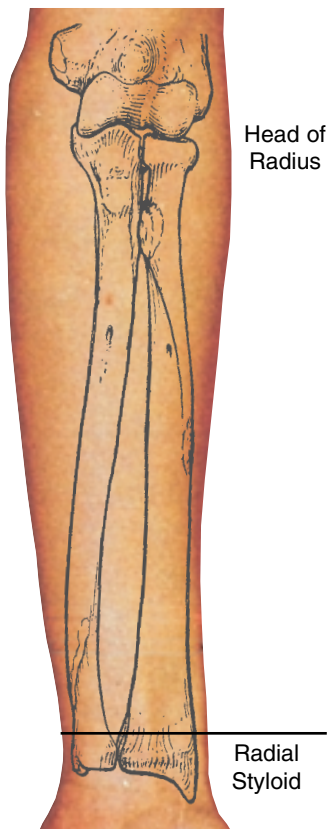RADIUS and ULNA left

CUT 6

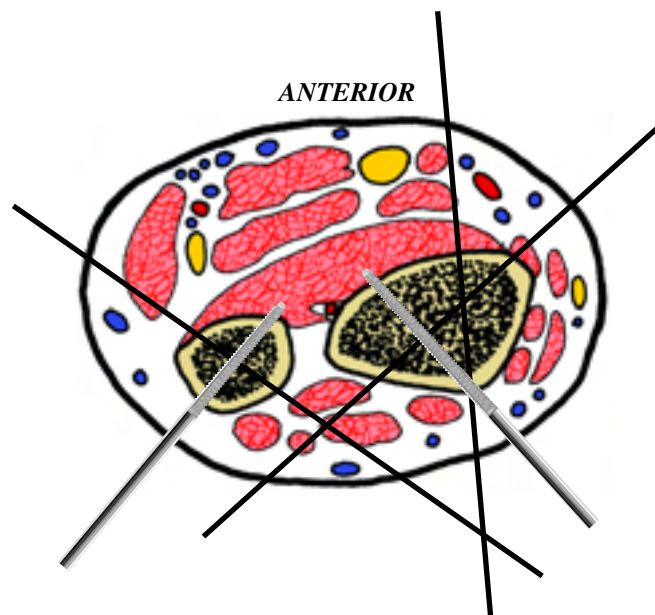


In this cross sectional cut most of the arteries and tendons can be accurately localized by palpation as they lie superficially. The ulnar A.V. lie volar and medial and are protected by the flexor carpi ulnaris T. The median N. is slightly more radial in

position, being situated between the flexor digitorum superficialis and the flexor carpi radialis. As in 30% of the normal population, this diagram shows no palmaris longus T. The radial A. is found between the flexor carpi radialis and the abductor pollicis longus.



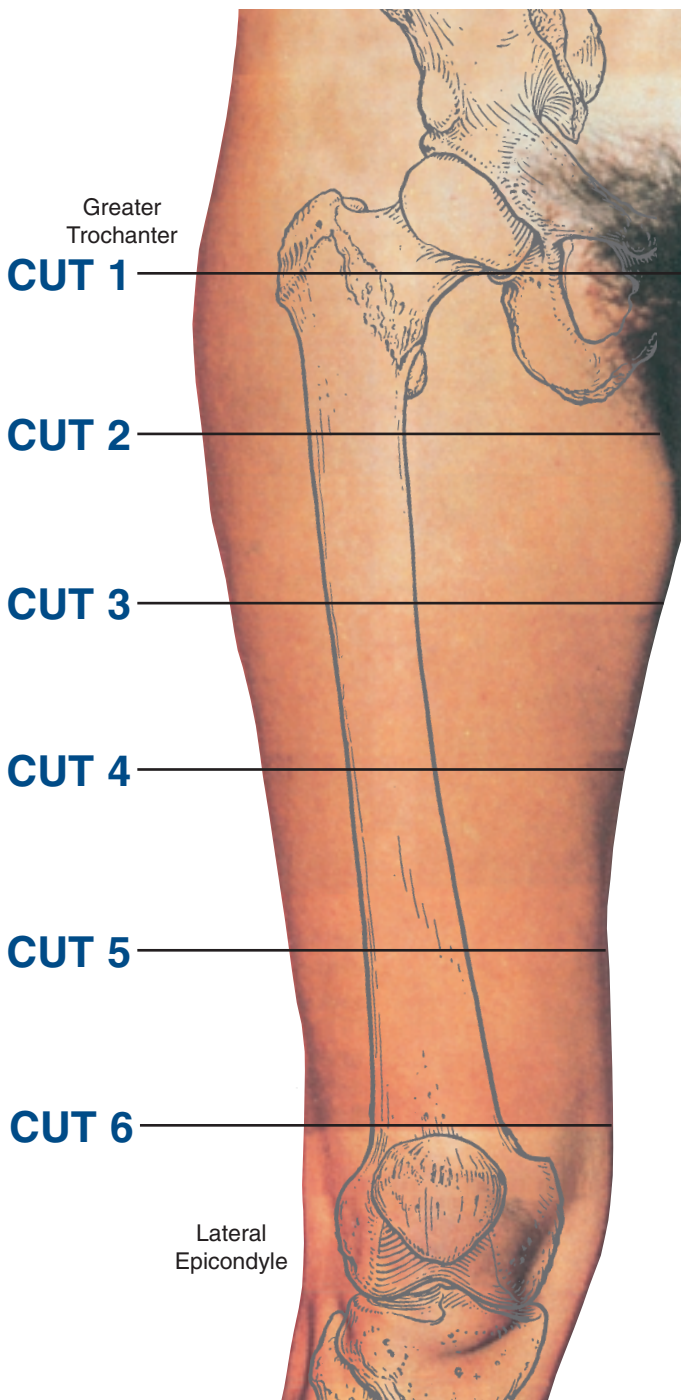
CUT 6



Ulnar fixation is performed with a wire directed from anteromedial to posterolateral angulated 45° to the sagittal plane and a half pin directed from posteromedial to anterolateral, perpendicular to the previous wire. The radius can be fixed with one wire directed from anterolateral to posteromedial angulated 45° with the coronal plane and a second wire inserted from anterior to posterior, between the flexor carpi radialis and the median nerve, using the open technique. A half pin is inserted from posterolateral to anteromedial, perpendicular to the first wire.

Levels of the anatomical cuts of the lower extremity

FEMUR* right



1 At this level the recommended fixation is performed using one half pin (6mm) inserted from anterolateral to postero-medial, and a second one from posterolateral to anteromedial: the two pins are angulated from 30-40°.

2 The insertion of half pins at this level is from lateral to anteromedial, posterior to the vastus lateralis, avoiding the lateral cutaneous N of thigh.

3 The insertion of half pins at this level is from posterolateral to anteromedial, through the vastus lateralis. At the time of insertion the muscle fibres need to be opened with an artery type forceps in line with their fibres, to allow for knee motion. Alternatively two wires can be inserted, the first from posterolateral to anteromedial, one through the lateral intermuscular septum, transfixing the vastus intermedius and the rectus femoris. The second wire is placed in a similar plane to the half pin. However, wires are poorly tolerated at this level, with a higher risk of soft tissue damage. In particular, patients treated with bone transport and lengthening are at risk of injury to the profunda or femoral A. over time. There is a risk of late haemorrhage or pseudoaneurysm formation, therefore the half pin is preferred in this situation.

4 The anterior and lateral quadrants are the safest for pin insertion at this level, the latter being tolerated. One optional transosseous wire can be inserted in an oblique anteromedial to posterolateral direction and a second from postero lateral to anteromedial. The half pin is placed in a more posterolateral position, directed more anteriorly and along the line of the anterior aspect of the lateral intermuscular septum.

5 The placement of the half pin and oblique posterolateral to anteromedial wire is the same as for cut four. An additional fine wire can be placed obliquely in the anterolateral to slightly posteromedial direction, exiting along the anterior portion of sartorius. This is again placed to avoid the medial neurovascular structures.

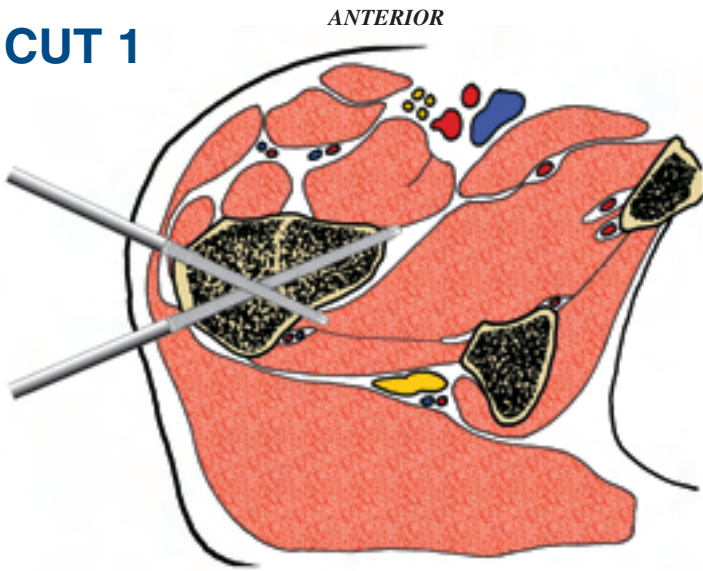
6 A distal reference wire is usually the first one inserted in femoral fixation using a fine wire fixator. This is a transcondylar wire inserted in the transverse line at the level of the superior pole of the patella. Great care must be taken to ensure the wire does not impinge on the soft tissues and limit knee motion. This means the wire is inserted so that there is no movement in the wire as the knee is examined through a 0° to 90° range of motion. If the soft tissues are seen to impinge, evident with movement in the wire, then it is backed off and reinserted. This is necessary to find the isometric point within the iliotibial band and fascia lata. If the skin alone is tenting then the wire is passed through to the opposite side and then driven back through the skin while the knee is in a different position of flexion.

The medial and lateral surfaces of the femur can also be utilised for fixation by means of two half pins inserted in a posteromedial and a posterolateral position respectively. Again additional release of the soft tissues, in particular the iliotibial band, may be necessary to allow adequate knee motion.

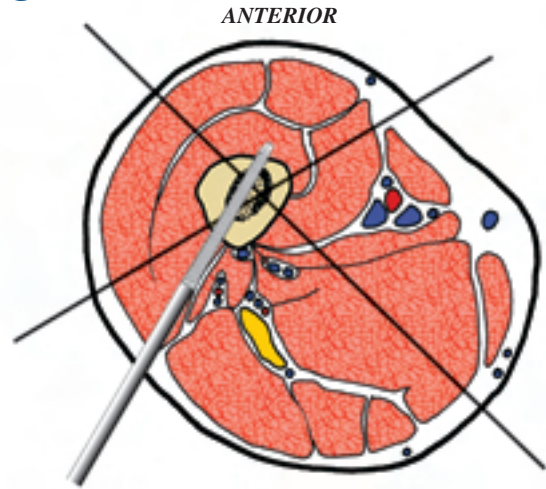
* Chapter contributed by: Dr. Richard S. Page, BMedSci, MB, BS, FRACS (Orth) - Orthopaedic Surgeon - The Geelong Hospital - Geelong, Victoria, Australia.

INSERTION WIRES AND HALF-PINS - RIGHT

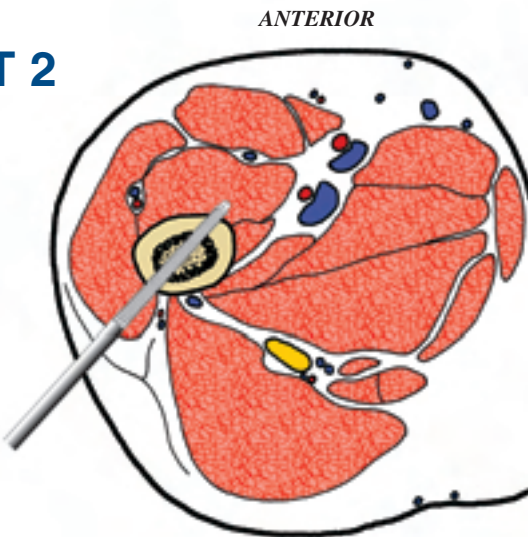
CUT 1



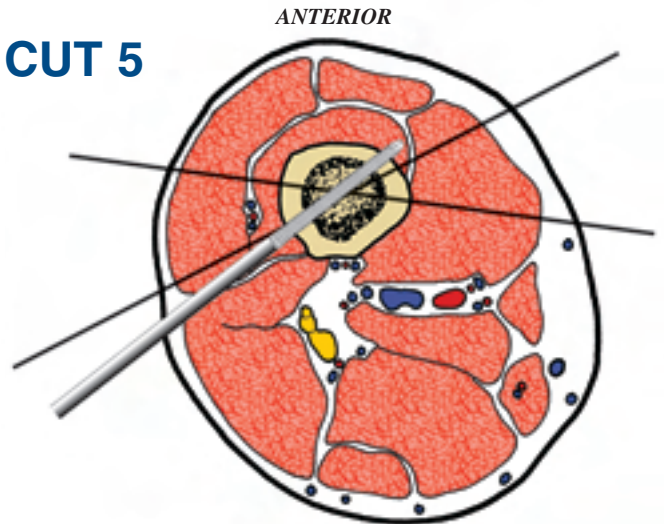
CUT 4



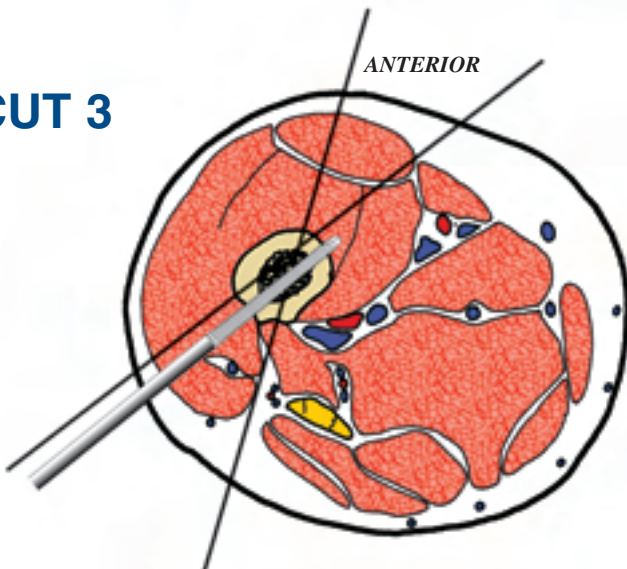
CUT 2



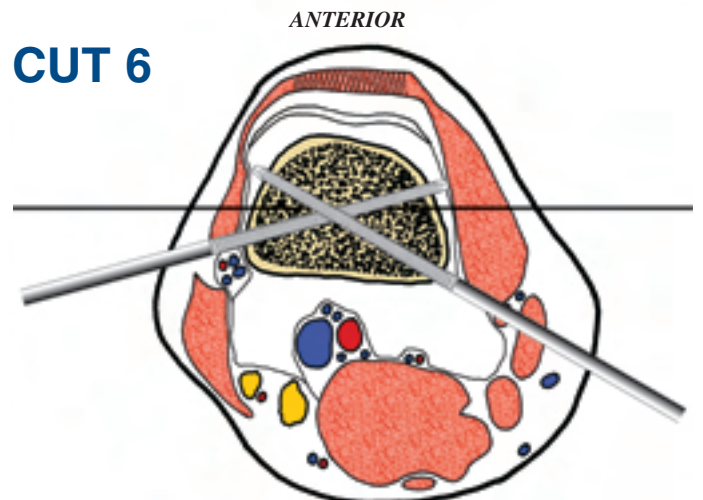
CUT 5



CUT 3

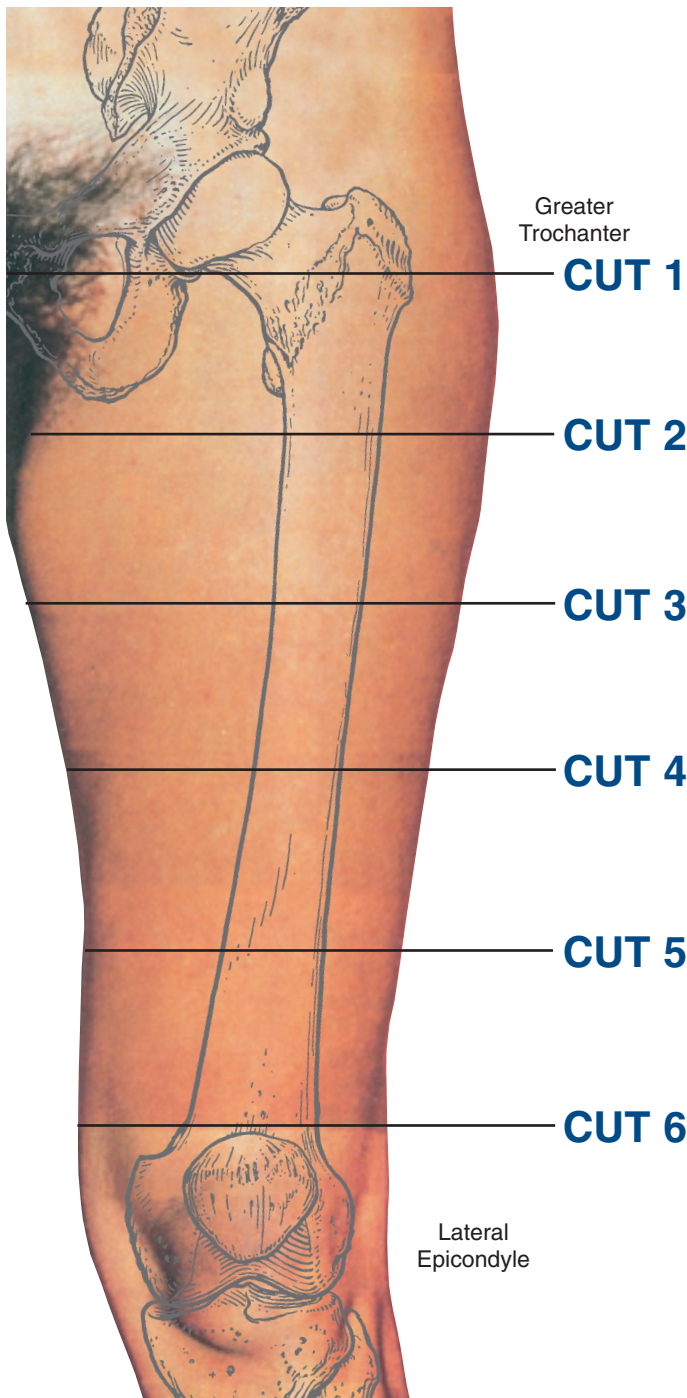


CUT 6



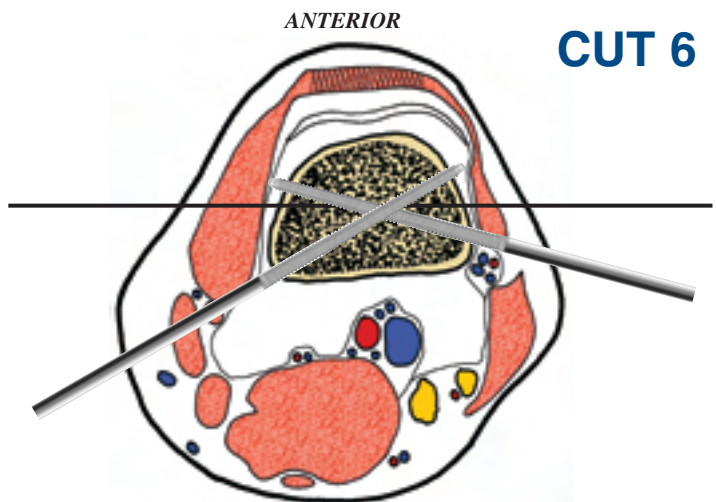
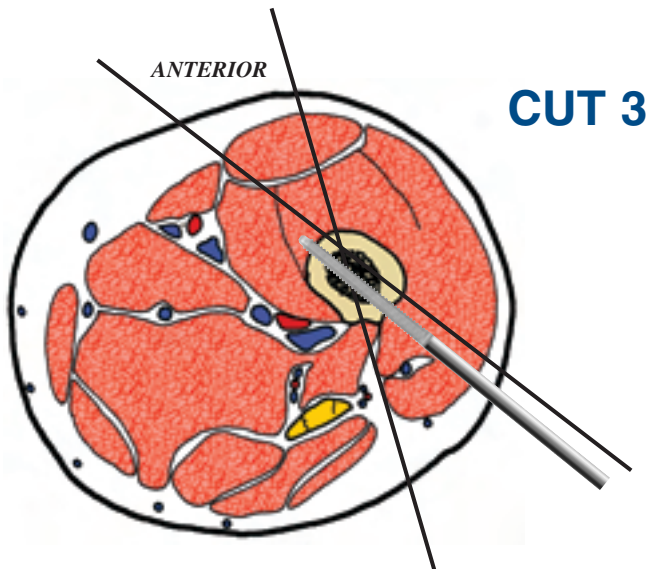
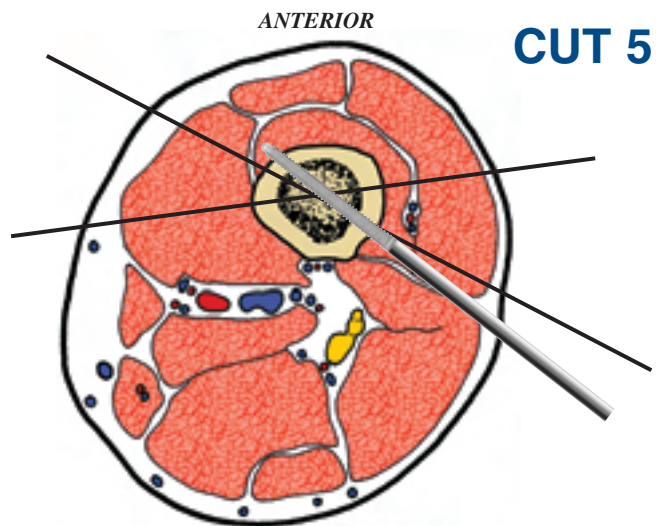
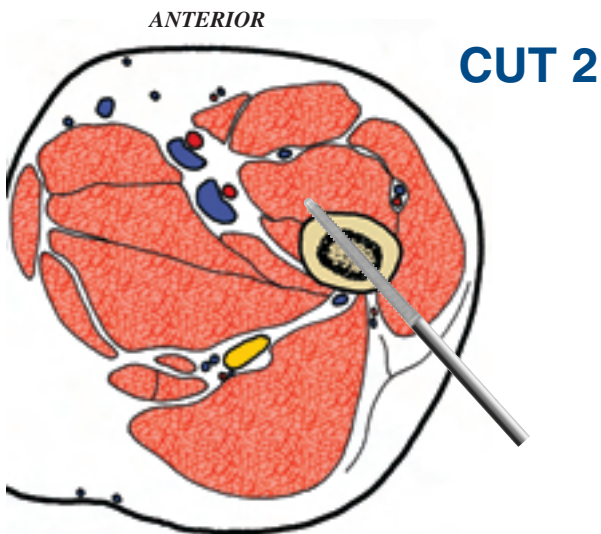
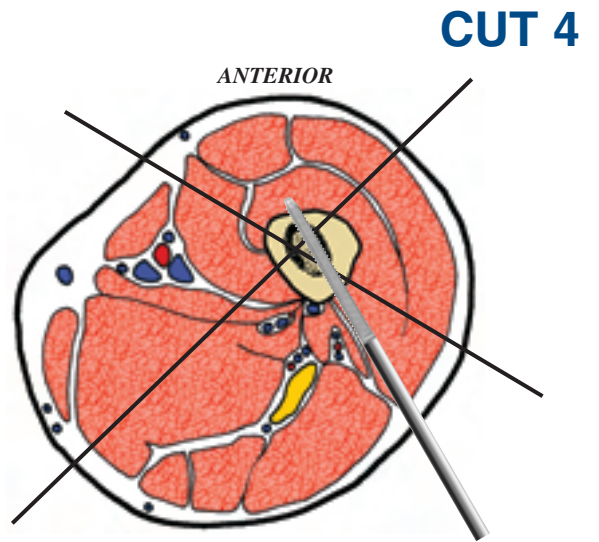
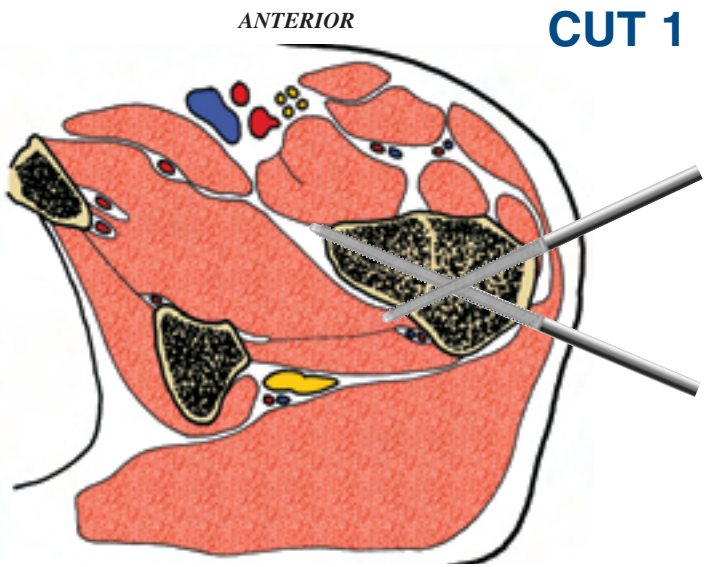
Levels of the anatomical cuts of the lower extremity

FEMUR left



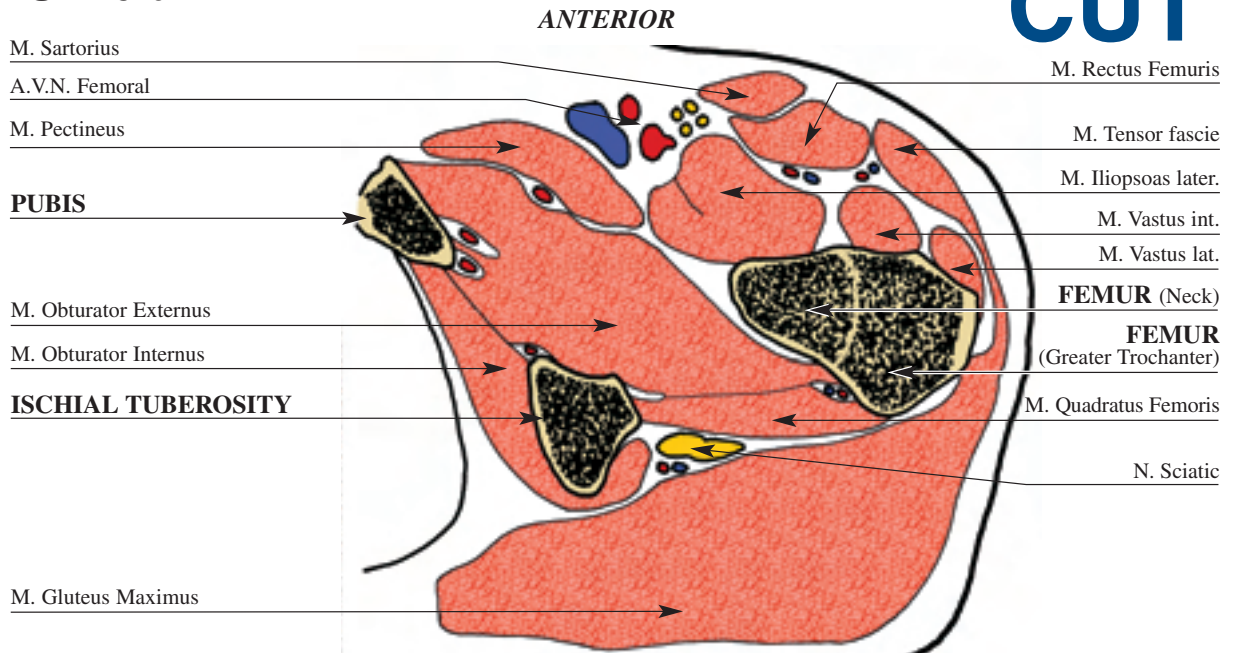
- 1** At this level the recommended fixation is performed using one half pin (6mm) inserted from anterolateral to postero-medial, and a second one from posterolateral to anteromedial: the two pins are angulated from 30-40°.
- 2** The insertion of half pins at this level is from lateral to anteromedial, posterior to the vastus lateralis, avoiding the lateral cutaneous N of thigh.
- 3** The insertion of half pins at this level is from posterolateral to anteromedial, through the vastus lateralis. At the time of insertion the muscle fibres need to be opened with an artery type forceps in line with their fibres, to allow for knee motion. Alternatively two wires can be inserted, the first from posterolateral to anteromedial, one through the lateral intermuscular septum, transfixing the vastus intermedius and the rectus femoris. The second wire is placed in a similar plane to the half pin. However, wires are poorly tolerated at this level, with a higher risk of soft tissue damage. In particular, patients treated with bone transport and lengthening are at risk of injury to the profunda or femoral A. over time. There is a risk of late haemorrhage or pseudoaneurysm formation, therefore the half pin is preferred in this situation.
- 4** The anterior and lateral quadrants are the safest for pin insertion at this level, the latter being tolerated. One optional transosseous wire can be inserted in an oblique anteromedial to posterolateral direction and a second from postero lateral to anteromedial. The half pin is placed in a more posterolateral position, directed more anteriorly and along the line of the anterior aspect of the lateral intermuscular septum.
- 5** The placement of the half pin and oblique posterolateral to anteromedial wire is the same as for cut four. An additional fine wire can be placed obliquely in the anterolateral to slightly posteromedial direction, exiting along the anterior portion of sartorius. This is again placed to avoid the medial neurovascular structures.
- 6** A distal reference wire is usually the first one inserted in femoral fixation using a fine wire fixator. This is a transcondylar wire inserted in the transverse line at the level of the superior pole of the patella. Great care must be taken to ensure the wire does not impinge on the soft tissues and limit knee motion. This means the wire is inserted so that there is no movement in the wire as the knee is examined through a 0° to 90° range of motion. If the soft tissues are seen to impinge, evident with movement in the wire, then it is backed off and reinserted. This is necessary to find the isometric point within the iliotibial band and fascia lata. If the skin alone is tenting then the wire is passed through to the opposite side and then driven back through the skin while the knee is in a different position of flexion. The medial and lateral surfaces of the femur can also be utilised for fixation by means of two half pins inserted in a posteromedial and a posterolateral position respectively. Again additional release of the soft tissues, in particular the iliotibial band, may be necessary to allow adequate knee motion.

INSERTION WIRES AND HALF-PINS - LEFT



FEMUR left

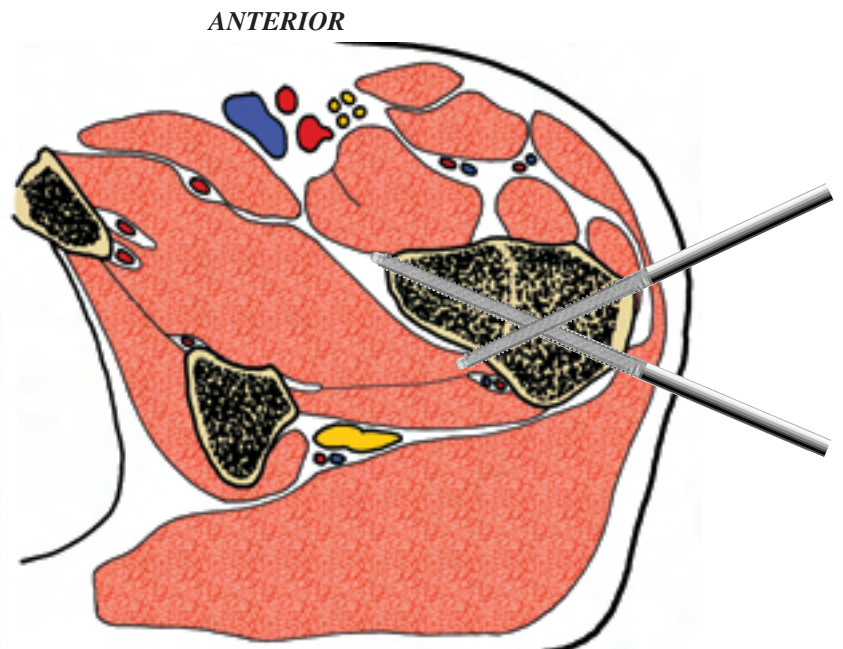
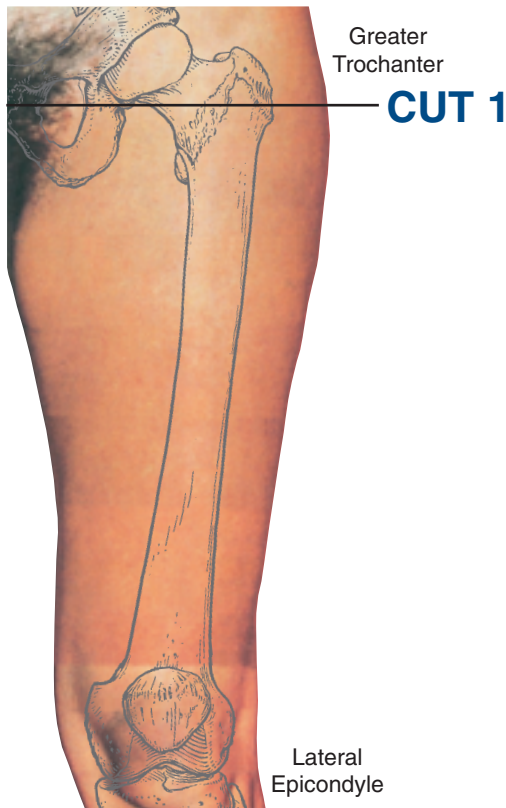CUT 1



This transverse section is at the level of the intertrochanteric line, where the femur is relatively superficial. At this level the femur is triangular in cross section, with the medial apex corresponding to the lesser trochanter.

The ischium is palpable posteromedial and represents an important landmark for the sciatic N. The femoral A. is palpable

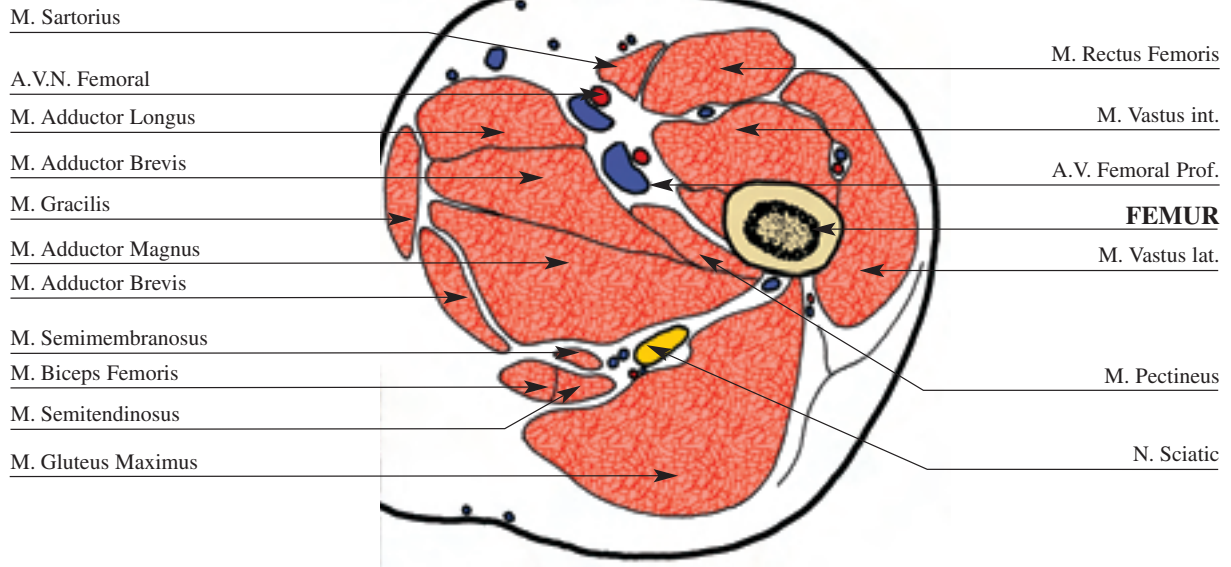
anteromedial where it runs with the femoral N. on its lateral aspect and the femoral V. to its medial side. Other arteries that may be encountered at this level include the ascending branch of the lateral circumflex femoral A. and the medial circumflex A. Posteriorly, the sciatic N. runs down in a line midway between the ischium and the femur, over the obturator internus, gameli, and quadratus femoris. At this level, fibres of the gluteus cover the nerve posteriorly.



At this level the recommended fixation is performed using one half pin (6mm) inserted from anterolateral to posteromedial, and a second one from posterolateral to anteromedial: the two pins are angulated from 30-40°.

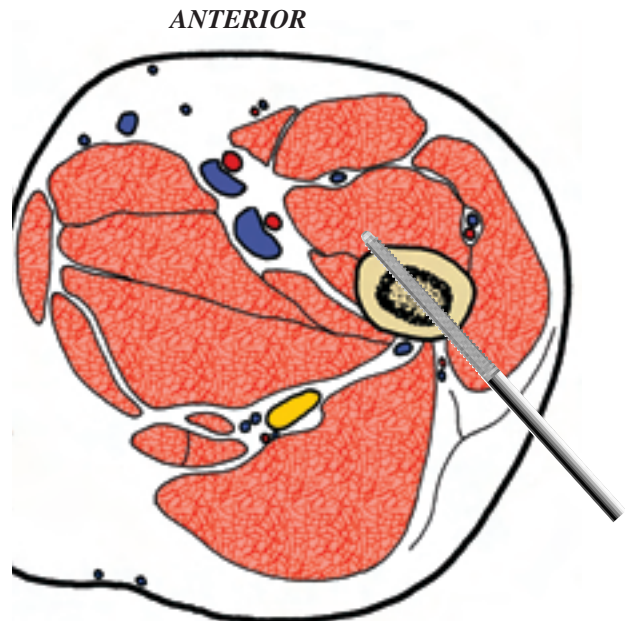
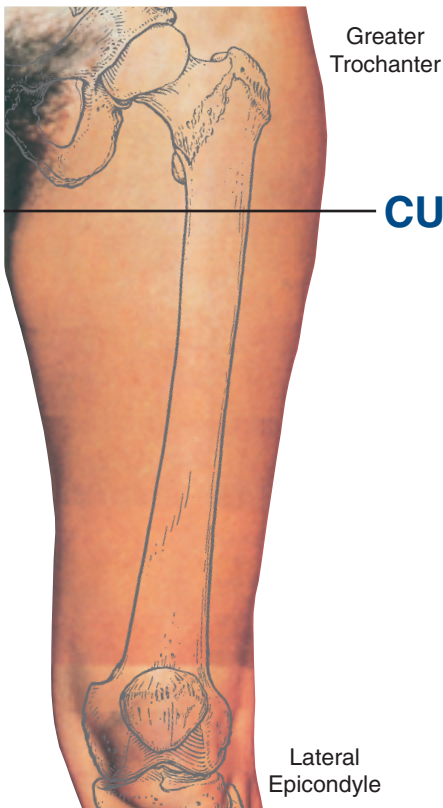
FEMUR left

CUT 2



This section is taken at the level of the gluteal fold, and distal to the intertrochanteric line. The femur is located in the antero-lateral quadrant of the transverse section. The femoral pulse assists in the localization of the femoral N. in addition to the femoral A and V. These structures are located anterior and medial within the femoral triangle formed by the sartorius and

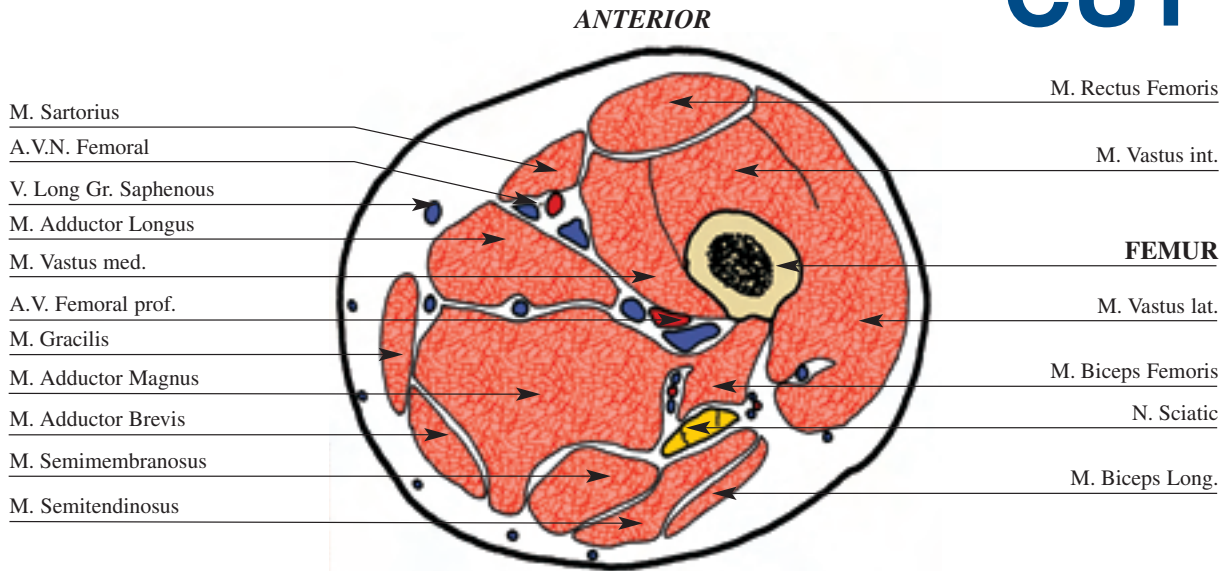
pectineus, and the inguinal ligament superiorly. The adductor muscle group is more medial. In the middle of the cross section at this level lies the profunda femoris A. with its variable perforating branches. The sciatic N. is posterior and medial in respect to the femur. It is contained between the gluteus maximus and the semimembranosus, lying on the upper portion of adductor magnus. Anteriorly, the fascicles of the femoral N. are rapidly diverging in order to innervate the extensor musculature.



The insertion of half pins at this level is from lateral to anteromedial, posterior to the vastus lateralis, avoiding the lateral cutaneous N of thigh.

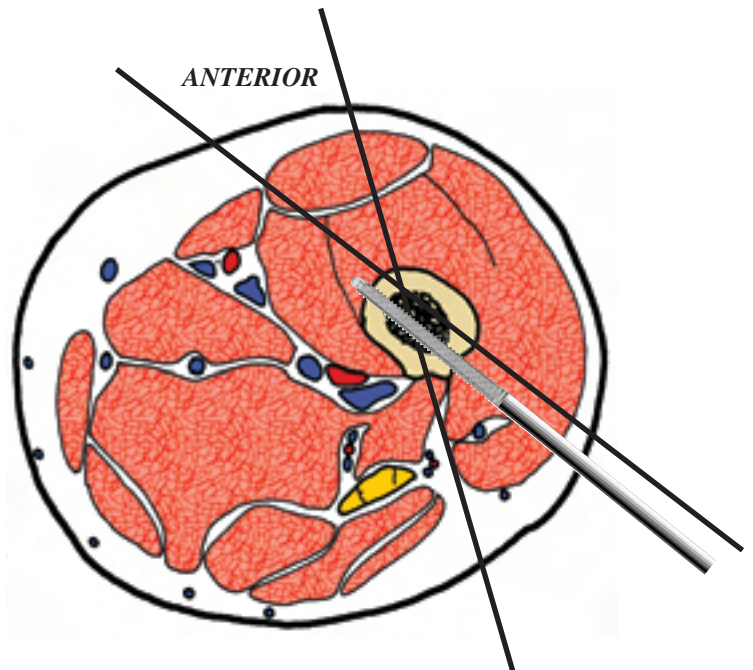
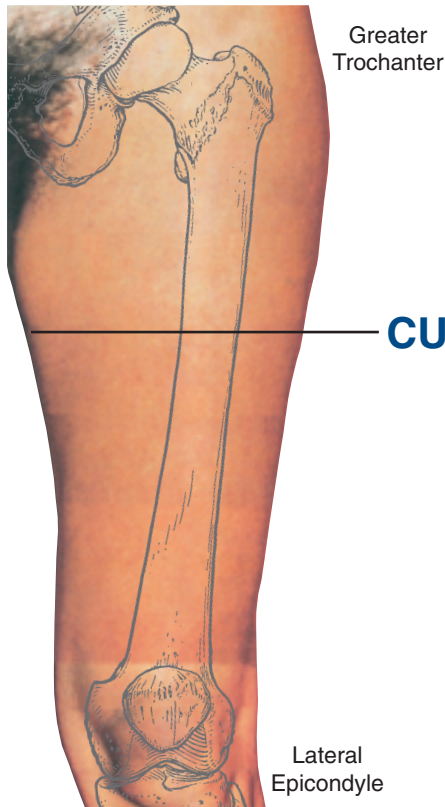
FEMUR left

CUT 3



This section is distal to the gluteal fold, and distal to the intertrochanteric line. The femur is still anterolateral in position, surrounded by quadriceps. It is becoming more circular in cross section, with a thicker cortex. The femoral A. and V.,

along with the femoral N. are more medial to the femur entering the sub-sartorial canal. The profunda femoris A. is a significant structure at this level and it lies between the femoral A. and the femur, posterior to the vastus medialis.

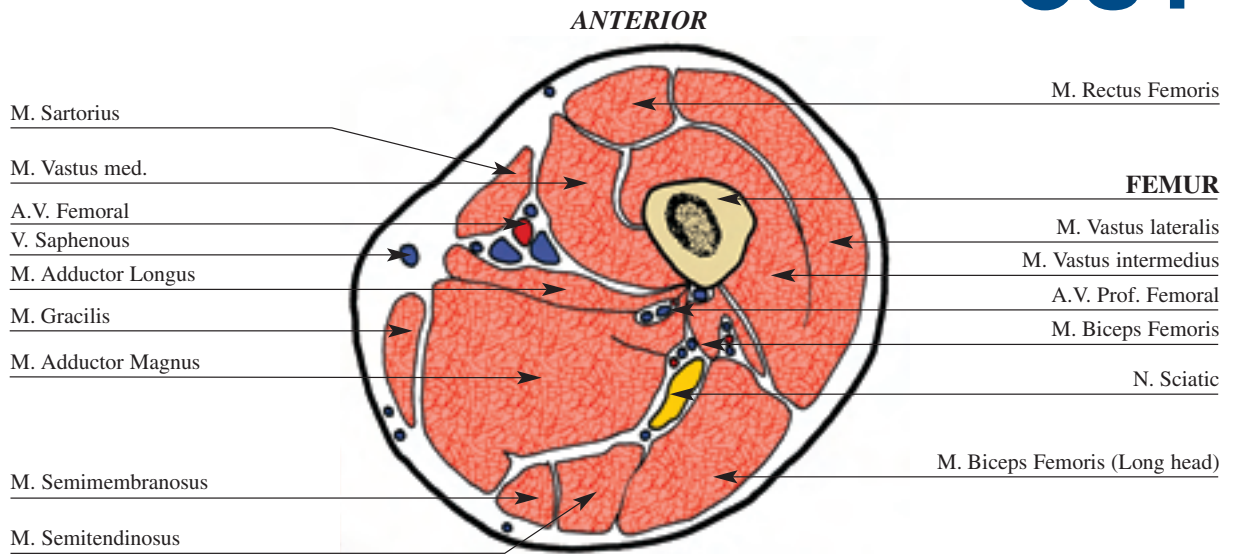


The insertion of half pins at this level is from posterolateral to anteromedial, through the vastus lateralis. At the time of insertion the muscle fibres need to be opened with an artery type forceps in line with their fibres, to allow for knee motion. Alternatively two wires can be inserted, the first from posterolateral to anteromedial, one through the lateral intermuscular septum, transfixing the vastus intermedius and the rectus femoris. The second wire is placed in a similar plane to the half pin. However, wires are poorly tolerated at this level, with a higher risk of soft tissue damage. In particular, patients treated with bone transport and lengthening are at risk of injury to the profunda or femoral A. over time. There is a risk of late haemorrhage or pseudoaneurysm formation, therefore the half pin is preferred in this situation.

Note: in the femoral diaphysis the half pin is better tolerated. The wires are used only in special cases.

FEMUR left

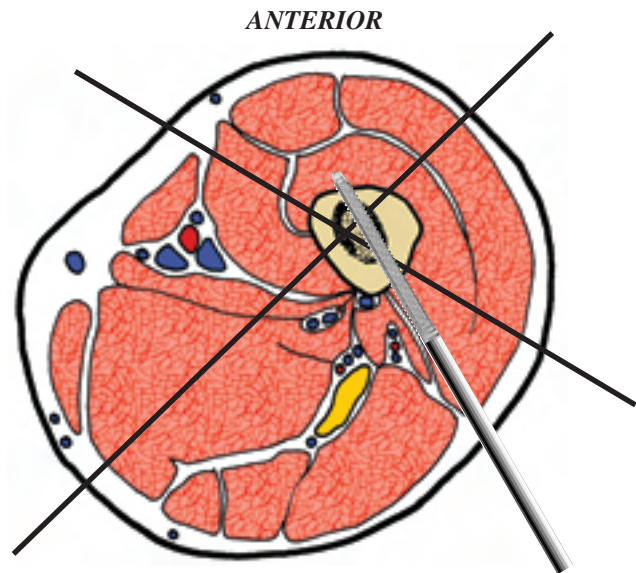
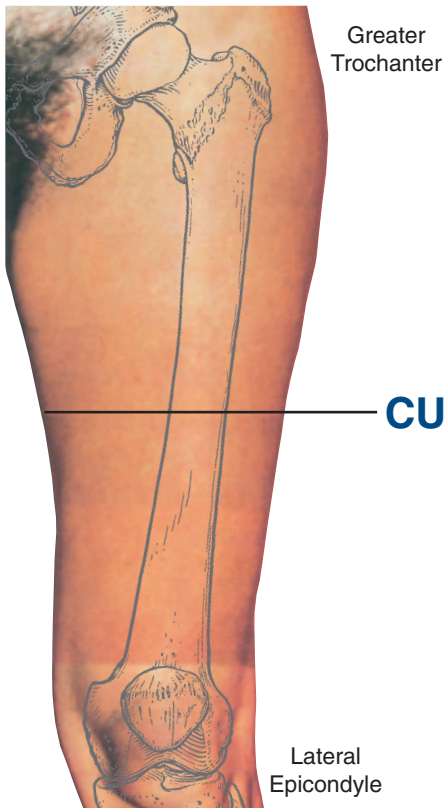
CUT 4



This level is distal to the gluteal fold and the subtrochanteric line. The femur still is circular with thick cortices, and located in the anterolateral quadrant. Here it is almost surrounded by the quadriceps musculature. The femoral A and V. along with what is now becoming the saphenous N. have come to lie directly medial to the femur, still undercover of sartorius with-

in the adductor canal. The canal is bound by the sartorius anteriorly, vastus medialis to the lateral side and the adductor magnus posteriorly, in the medial zone. The profunda femoris A. is again significant at this level and lies between the femoral A., the femur and the sciatic N., which may be dividing into the tibial N. and the common peroneal N.

The sciatic N. and accompanying perforating branches of the profunda femoris A. lie directly posterior to the femur covered by the biceps, with vastus lateralis anterolateral and semimembranosus medially.

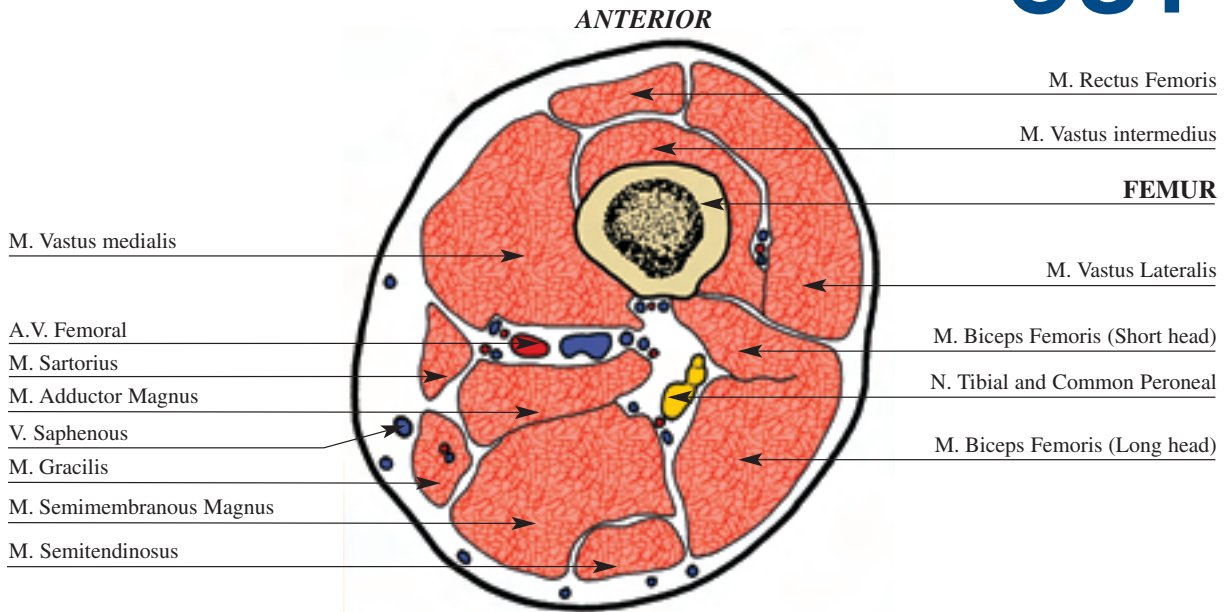


The anterior and lateral quadrants are the safest for pin insertion at this level, the latter being tolerated. One optional transosseous wire can be inserted in an oblique anteromedial to posterolateral direction and a second from postero lateral to anteromedial. The half pin is placed in a more posterolateral position, directed more anteriorly and along the line of the anterior aspect of the lateral intermuscular septum.

Note: in the femoral diaphysis the half pin is better tolerated. The wires are used only in special cases.

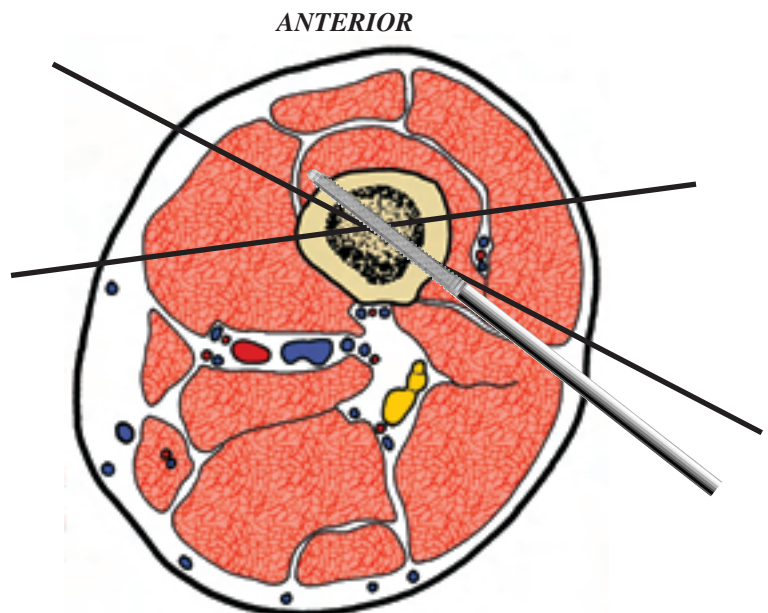
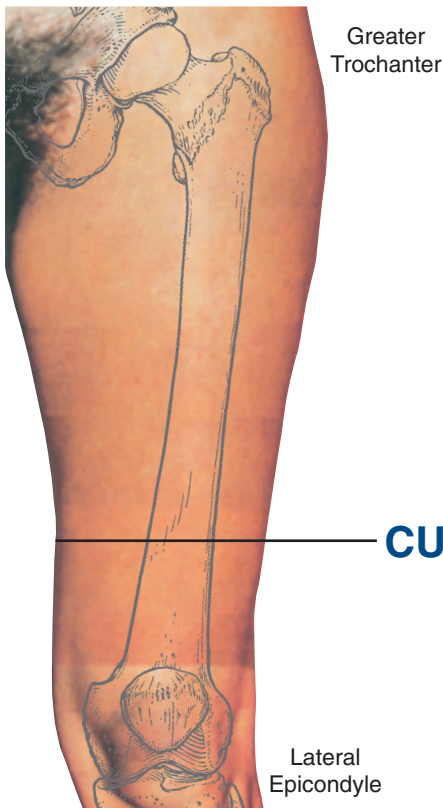
FEMUR left

CUT 5



The femur remains primarily circular and cortical in nature. Posteriorly the linea aspera gives attachment to the intermuscular septi. In muscular individuals identification of the sartorius can be very helpful as the femoral A. and V. lie beneath in the posteromedial zone, as they pass to the posterior aspect of the femur.

The areas to avoid at this level are on either side of adductor magnus. Medially, adjacent to the vastus medialis is the femoral A. and V. and posterolateral to this is the sciatic N as it begins to branch into the tibial N. and the common peroneal N. Because of these structures such zone must be avoided.

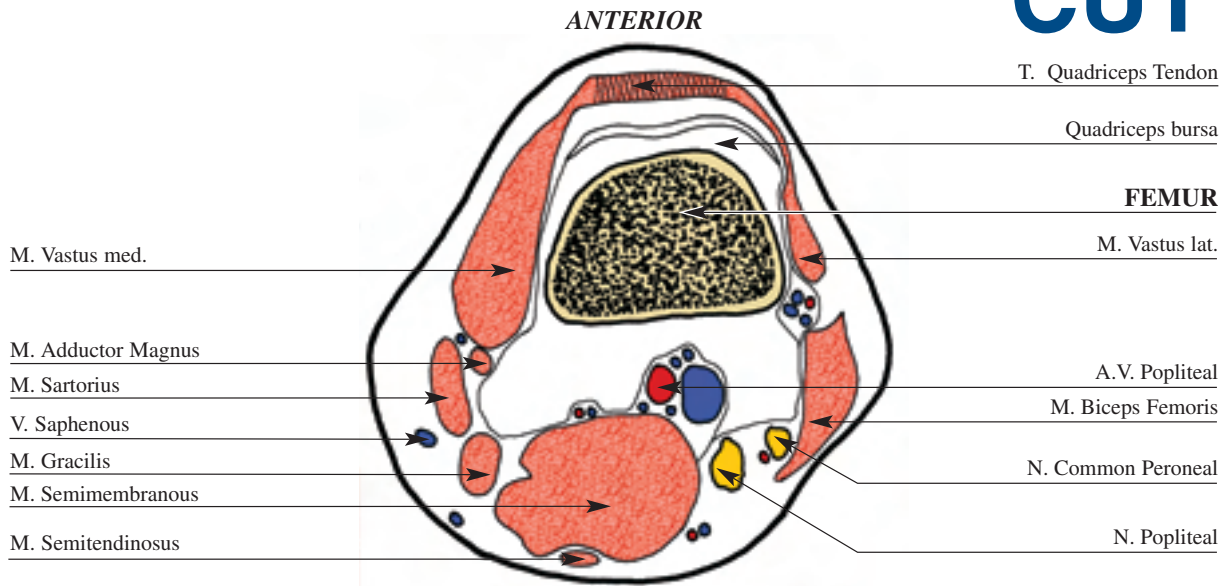


The placement of the half pin and oblique posterolateral to anteromedial wire is the same as for cut four. An additional fine wire can be placed obliquely in the anterolateral to slightly posteromedial direction, exiting along the anterior portion of sartorius. This is again placed to avoid the medial neurovascular structures.

Note: in the femoral diaphysis the half pin is better tolerated. The wires are used only in special cases.

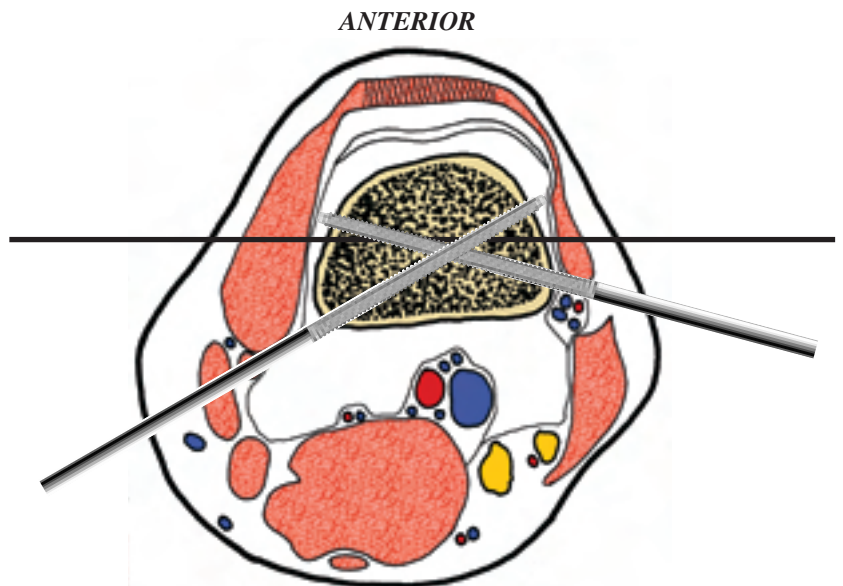
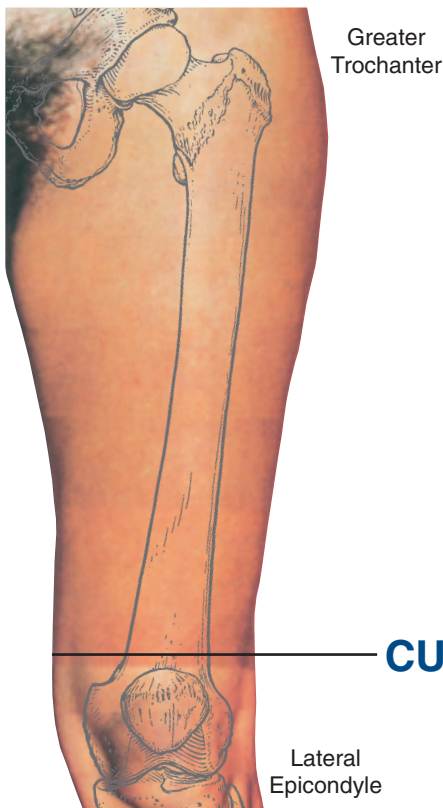FEMUR left

CUT 6



This section is taken about 4 cm proximal to the knee joint, at the level of the superior pole of the patella. The popliteal A. is

usually palpable posteriorly which aids in the artery's localization. At this level the femur is trapezoidal in cross section and is almost entirely cancellous. The articular cartilage of the knee joint is present anteriorly for the patellofemoral joint, and posteriorly for the tibiofemoral articulation. The medial and lateral extensor retinacula extend from either surface of the patella. The major neurovascular structures are located along the posteromedial surface of the lateral femoral condyle. In addition the common peroneal N. lies behind the biceps femoris tendon and the saphenous V. runs along the sartorius muscle.

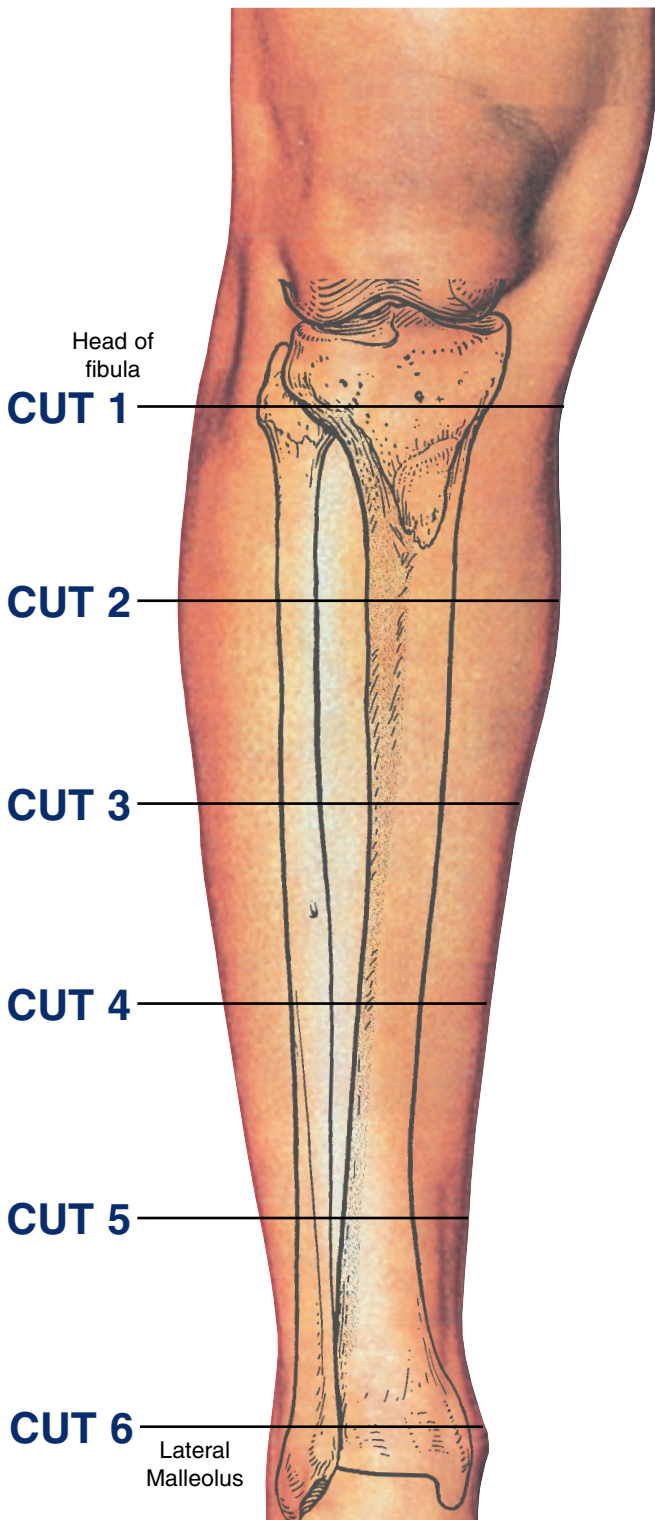


A distal reference wire is usually the first one inserted in femoral fixation using a fine wire fixator. This is a transcondylar wire inserted in the transverse line at the level of the superior pole of the patella. Great care must be taken to ensure the wire does not impinge on the soft tissues and limit knee motion. This means the wire is inserted so that there is no movement in the wire as the knee is examined through a 0° to 90° range of motion. If the soft tissues are seen to impinge, evident with movement in the wire, then it is backed off and reinserted. This is necessary to find the isometric point within the iliotibial band and fascia lata. If the skin alone is tenting then the wire is passed through to the opposite side and then driven back through the skin while the knee is in a different position of flexion. The medial and lateral surfaces of the femur can also be utilised for fixation by means of two half pins inserted in a posteromedial and a posterolateral position respectively. Again additional release of the soft tissues, in particular the iliotibial band, may be necessary to allow adequate knee motion.

Note: avoid placement of the wires or half pins distal to superior pole of the patella to prevent penetration of joint capsule which can lead to a septic joint.

Levels of the anatomical cuts of the lower extremity

TIBIA and FIBULA right



1 The diagram demonstrates the wide medial and lateral access to the tibia that is available for pin insertion. A reference wire is usually first inserted for fine wire fixation. This is inserted in the transcondylar transverse plane anterior to the fibula. Optimum fixation is then obtained using two half pins placed anteriorly. The medial one can be used to also fix the fibula head, if this is the case a drill guide and trochar should be used. Alternatively a 2-3mm smooth pin can be used to transfix the proximal tibio-fibular joint, for example in tibial lengthening. This is inserted by palpating and protecting the common peroneal N. with the thumb and holding the soft tissues posteriorly, while the knee is flexed and the pin is driven through the fibular head. The pin is directed anteriorly, medially and slightly distally toward the closest available ring. The wire is cut off flush with skin, and pulled through to be flush with bone.

2 The half pin is inserted perpendicular to the subcutaneous border of the tibia on the medial aspect. The fine wire is inserted slightly obliquely to the transverse plane of the tibia to engage it in its widest portion.

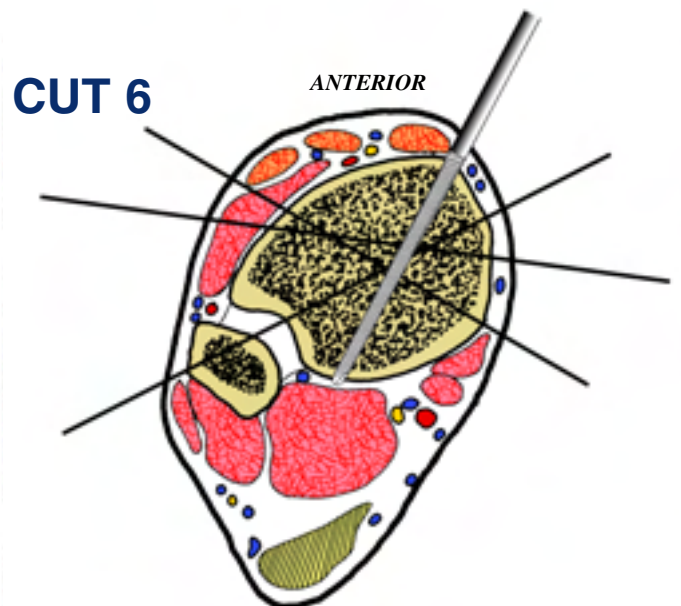
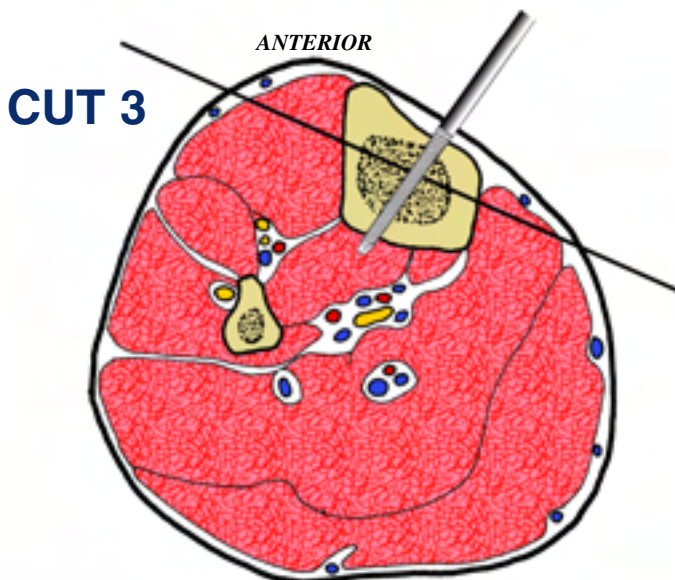
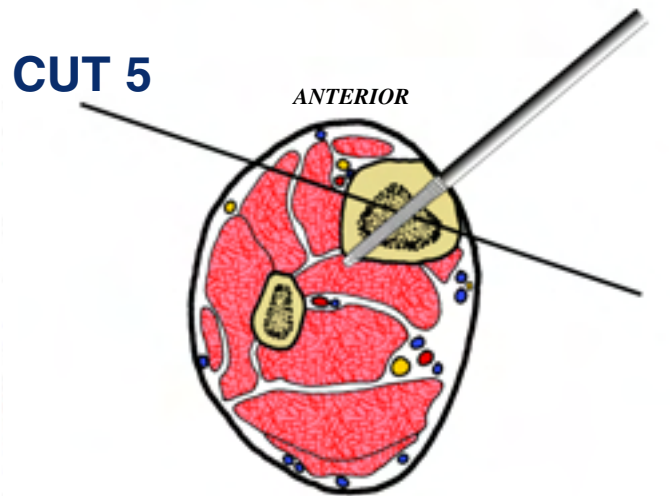
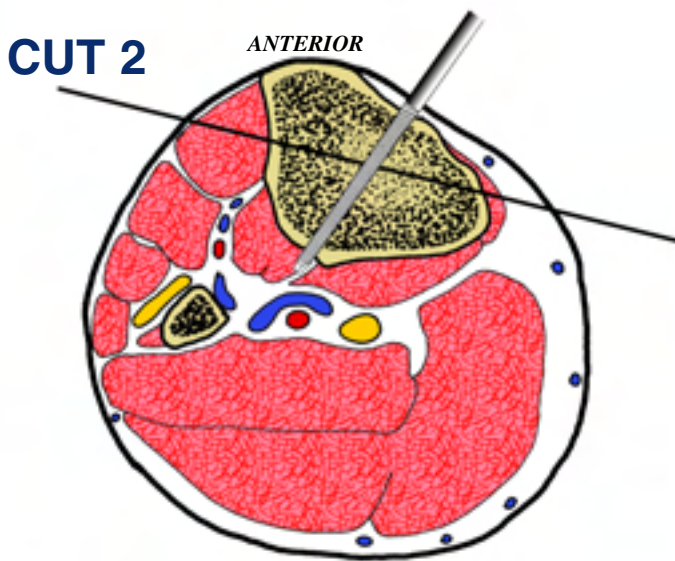
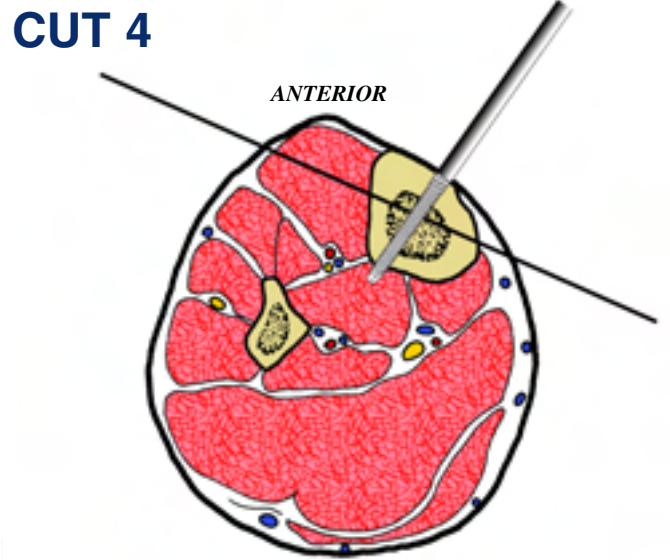
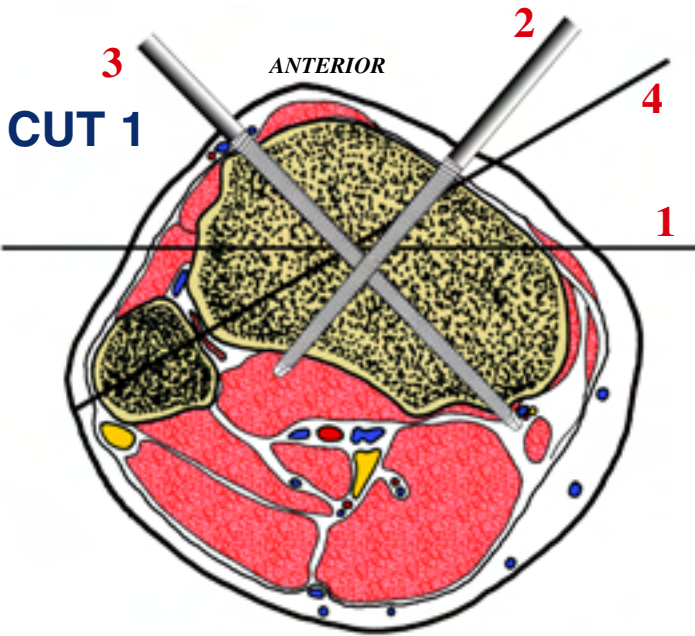
3 Tibial fixation is with a medial-oblique wire and a half pin inserted into the medial aspect of the tibia perpendicular to the medial aspect.

4 The insertion of the wire and half pin at this level is similar to that described for Cut Two and Three.

5 The wire at this level is placed almost parallel to the frontal plane of the tibia. The half pin is inserted again on the medial aspect, slightly obliquely to the wire as shown in the diagram.

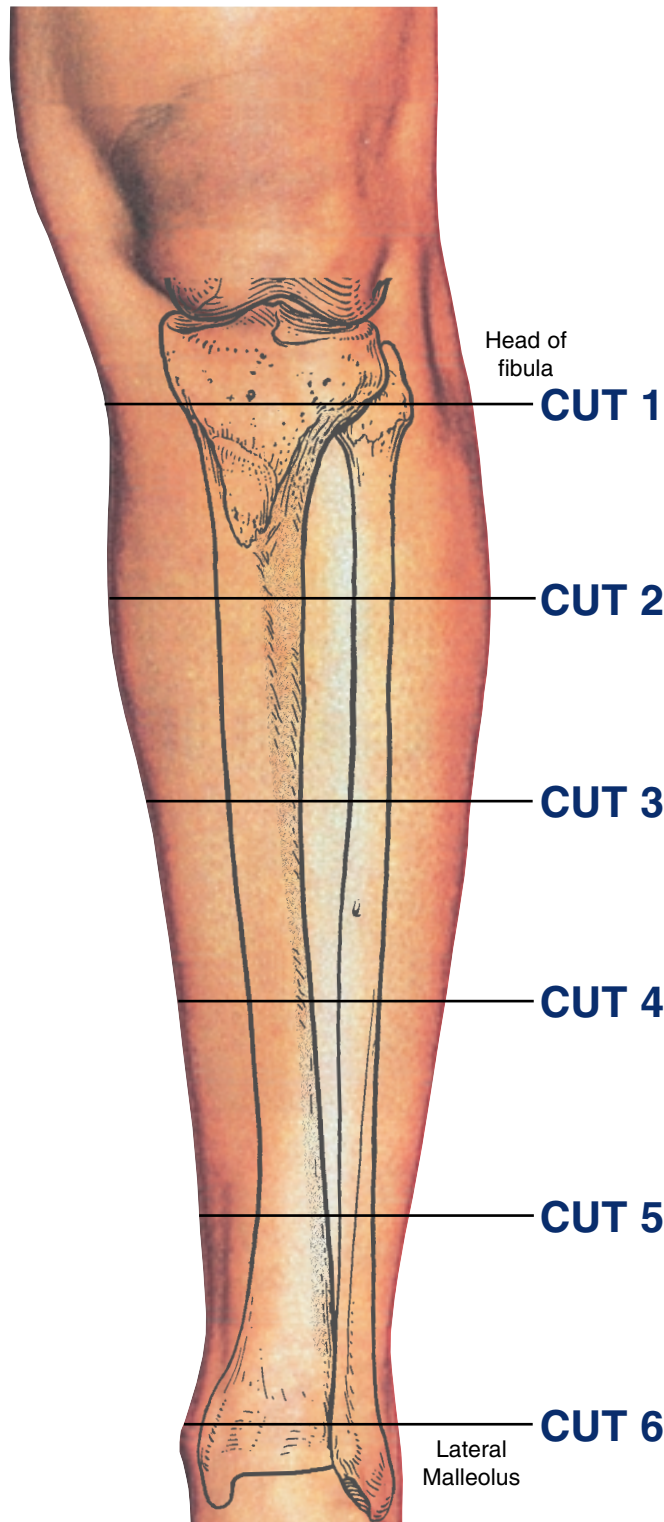
6 A distal tibial reference wire is the initial fixation used, with a direct medial to lateral wire. The fibular stabilization takes place through a lateral oblique wire directed from posterolateral to anteromedial. Additional stabilisation can be achieved with a wire directed from antero lateral to posteromedial, anterior to the neurovascular bundle. Alternatively a stabilizing half pin can be inserted anteriorly, lateral to the tibialis anterior tendon. This should be done with care using a limited open technique through a small incision, which is dilated with an artery forceps. The forceps is used to displace the soft tissues and therefore protect the anterior neurovascular bundle, allowing safe pre-drilling and insertion of a 5 or 6mm half pin.

INSERTION WIRES AND HALF-PINS - RIGHT



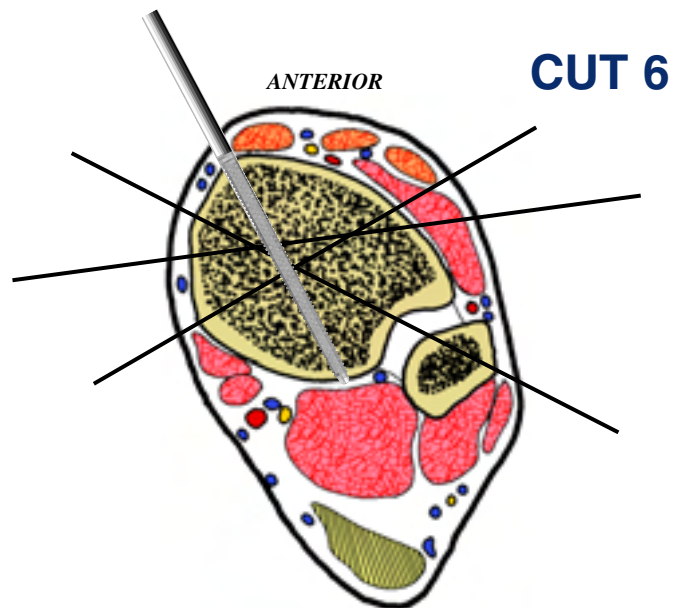
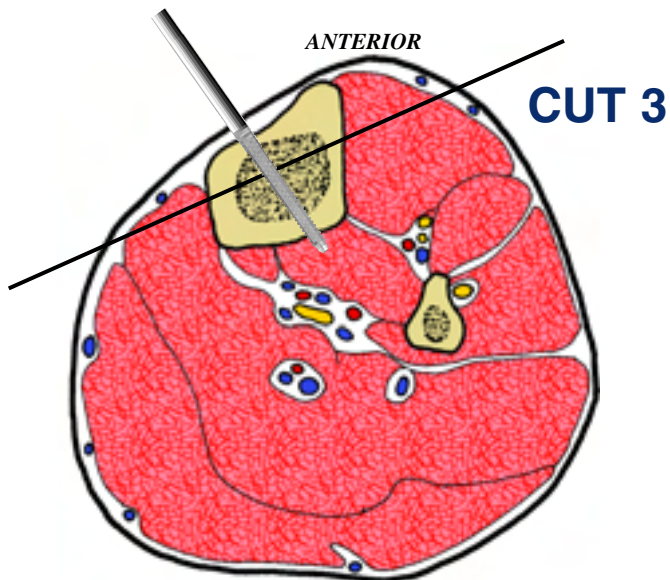
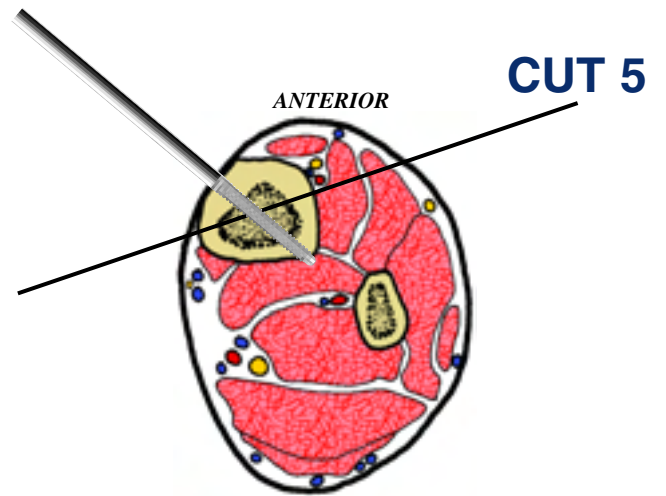
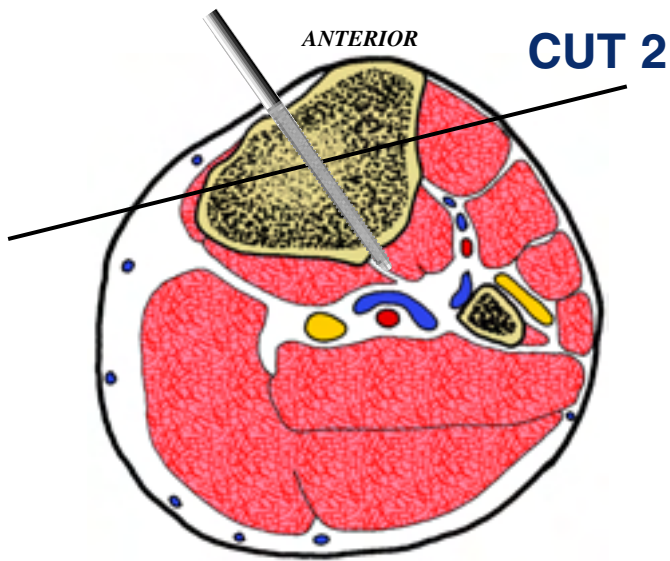
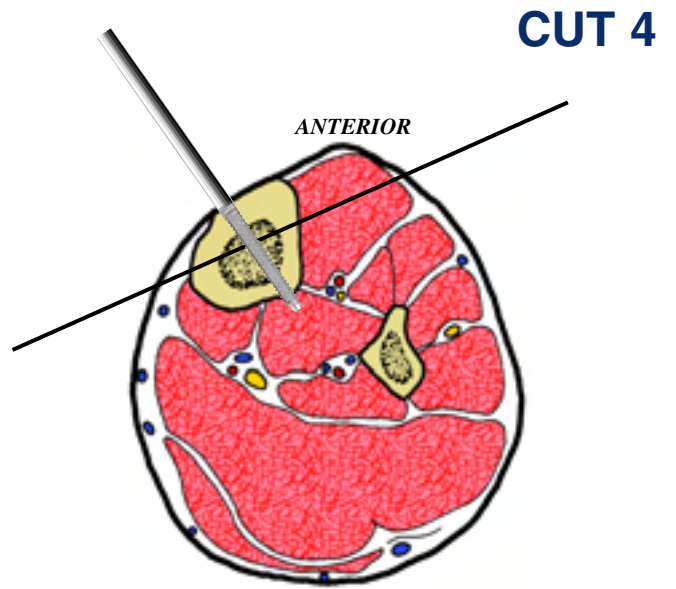
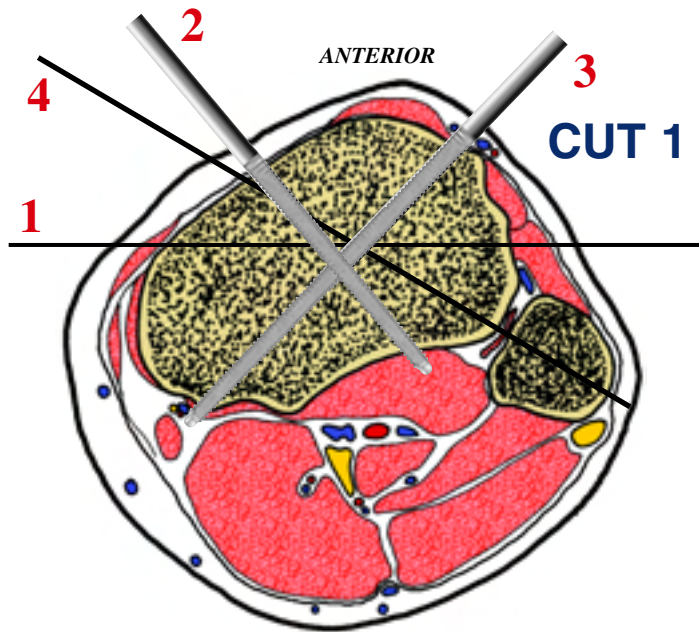
Levels of the anatomical cuts of the lower extremity

TIBIA and FIBULA left



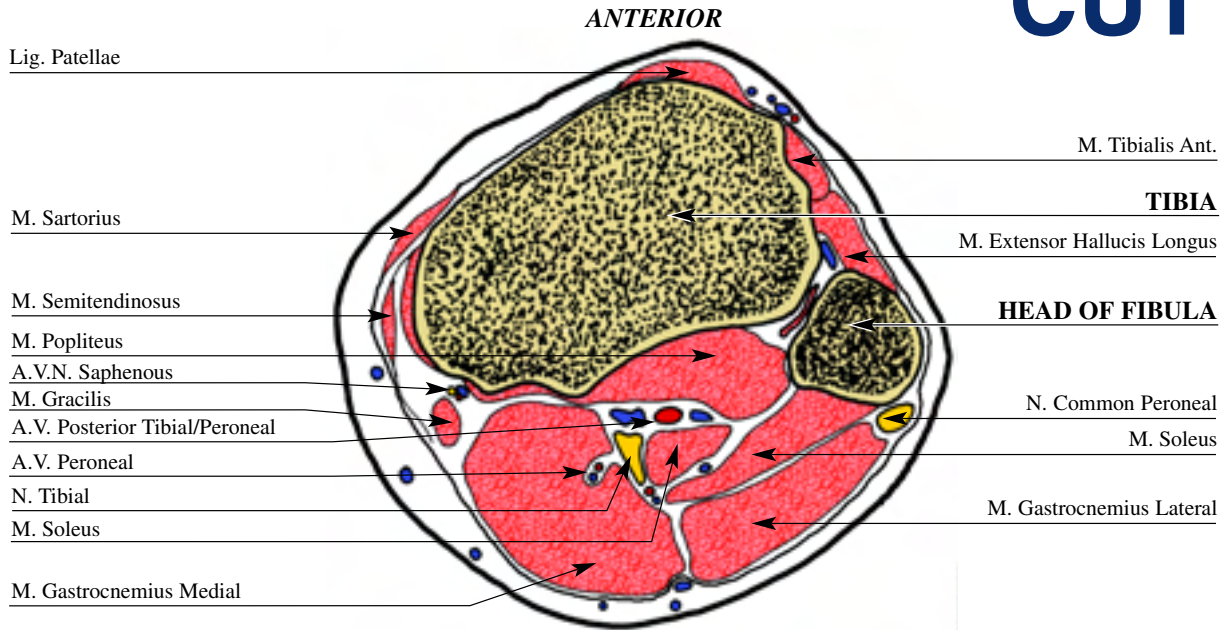
- 1** The diagram demonstrates the wide medial and lateral access to the tibia that is available for pin insertion. A reference wire is usually first inserted for fine wire fixation. This is inserted in the transcondylar transverse plane anterior to the fibula. Optimum fixation is then obtained using two half pins placed anteriorly. The medial one can be used to also fix the fibula head, if this is the case a drill guide and trochar should be used. Alternatively a 2-3mm smooth pin can be used to transfix the proximal tibio-fibular joint, for example in tibial lengthening. This is inserted by palpating and protecting the common peroneal N. with the thumb and holding the soft tissues posteriorly, while the knee is flexed and the pin is driven through the fibular head. The pin is directed anteriorly, medially and slightly distally toward the closest available ring. The wire is cut off flush with skin, and pulled through to be flush with bone.
- 2** The half pin is inserted perpendicular to the subcutaneous border of the tibia on the medial aspect. The fine wire is inserted slightly obliquely to the transverse plane of the tibia to engage it in its widest portion.
- 3** Tibial fixation is with a medial-oblique wire and a half pin inserted into the medial aspect of the tibia perpendicular to the medial aspect.
- 4** The insertion of the wire and half pin at this level is similar to that described for Cut Two and Three.
- 5** The wire at this level is placed almost parallel to the frontal plane of the tibia. The half pin is inserted again on the medial aspect, slightly obliquely to the wire as shown in the diagram.
- 6** A distal tibial reference wire is the initial fixation used, with a direct medial to lateral wire. The fibular stabilization takes place through a lateral oblique wire directed from posterolateral to anteromedial. Additional stabilisation can be achieved with a wire directed from antero lateral to posteromedial, anterior to the neurovascular bundle. Alternatively a stabilizing half pin can be inserted anteriorly, lateral to the tibialis anterior tendon. This should be done with care using a limited open technique through a small incision, which is dilated with an artery forceps. The forceps is used to displace the soft tissues and therefore protect the anterior neurovascular bundle, allowing safe pre-drilling and insertion of a 5 or 6mm half pin.

INSERTION WIRES AND HALF-PINS - LEFT



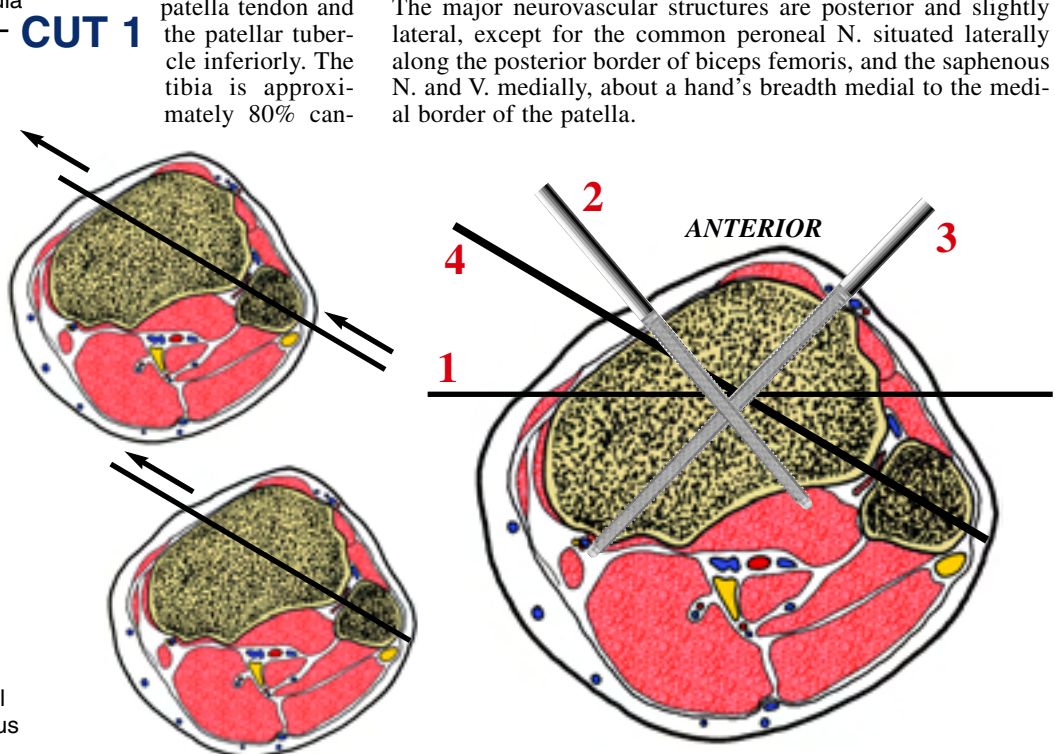
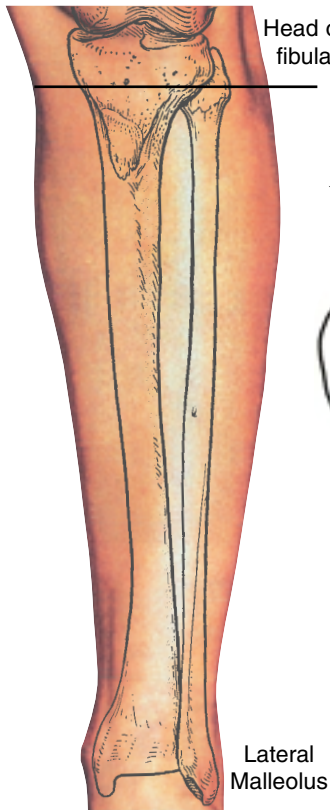
TIBIA and FIBULA left

CUT 1



The first cut crosses the medial and lateral tibial plateau just below the level of the knee joint. The tibia is palpable throughout the anterior two thirds, but not posteriorly. Other superficial landmarks include the lateral collateral ligament attaching to the fibular head, the patella tendon and the patellar tubercle inferiorly. The tibia is approximately 80% cancellous at this level. The fibula is also becoming predominantly cancellous in composition on the posterolateral side. The medial tibial surface provides attachment for the sartorius, gracilis and semitendinosus, making up the pes anserinus. The saphenous N. and V. run between these muscles with the inferior geniculate A., and the infrapatellar N emerges superficially. The major neurovascular structures are posterior and slightly lateral, except for the common peroneal N. situated laterally along the posterior border of biceps femoris, and the saphenous N. and V. medially, about a hand's breadth medial to the medial border of the patella.

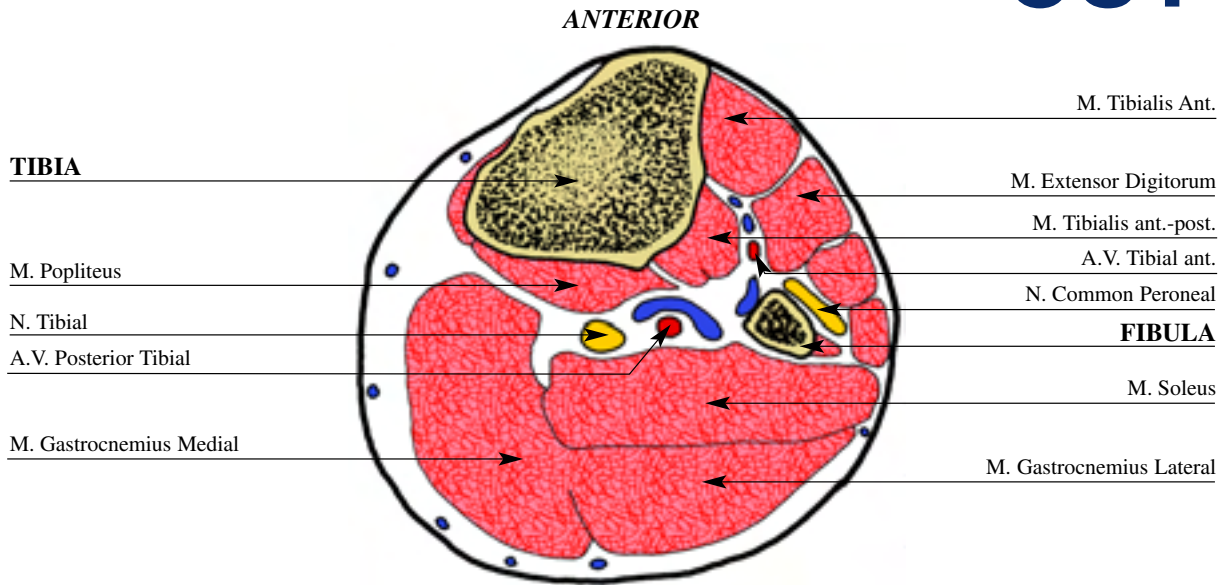
The diagram demonstrates the wide medial and lateral access to the tibia that is available for pin insertion. A reference wire is usually first inserted for fine wire fixation. This is inserted in the transcondylar transverse plane anterior to the fibula. Optimum fixation is then obtained using two half pins placed anteriorly. The medial one can be used to also fix the fibula head, if this is the case a drill guide and trochar should be used. Alternatively a 2-3mm smooth pin can be used to transfix the proximal tibio-fibular joint, for example in tibial lengthening. This is inserted by palpating and protecting the common peroneal N. with the thumb and holding the soft tissues posteriorly, while the knee is flexed and the pin is driven through the fibular head. The pin is directed anteriorly, medially and slightly distally toward the closest available ring. The wire is cut off flush with skin, and pulled through to be flush with bone. Note: do not place the wire through the capsule. Begin 13-15 mm distal to the articular surface.



The diagram demonstrates the wide medial and lateral access to the tibia that is available for pin insertion. A reference wire is usually first inserted for fine wire fixation. This is inserted in the transcondylar transverse plane anterior to the fibula. Optimum fixation is then obtained using two half pins placed anteriorly. The medial one can be used to also fix the fibula head, if this is the case a drill guide and trochar should be used. Alternatively a 2-3mm smooth pin can be used to transfix the proximal tibio-fibular joint, for example in tibial lengthening. This is inserted by palpating and protecting the common peroneal N. with the thumb and holding the soft tissues posteriorly, while the knee is flexed and the pin is driven through the fibular head. The pin is directed anteriorly, medially and slightly distally toward the closest available ring. The wire is cut off flush with skin, and pulled through to be flush with bone. Note: do not place the wire through the capsule. Begin 13-15 mm distal to the articular surface.

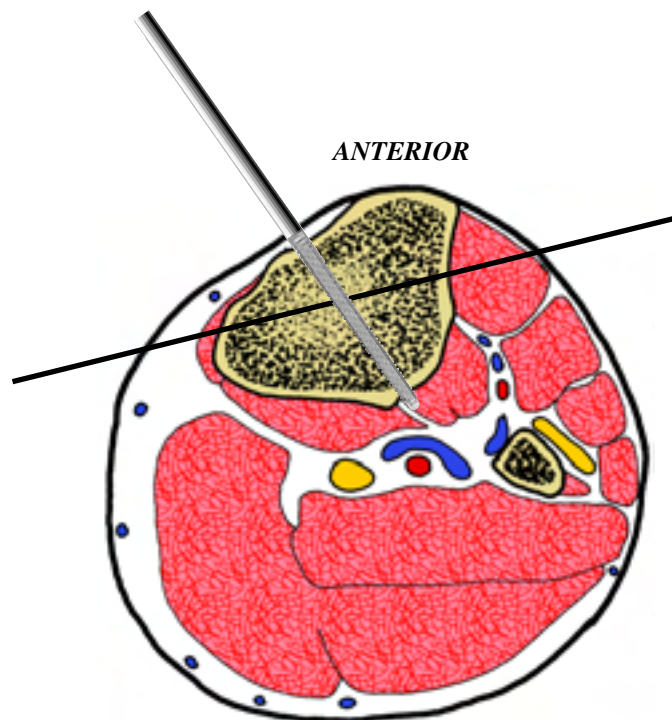
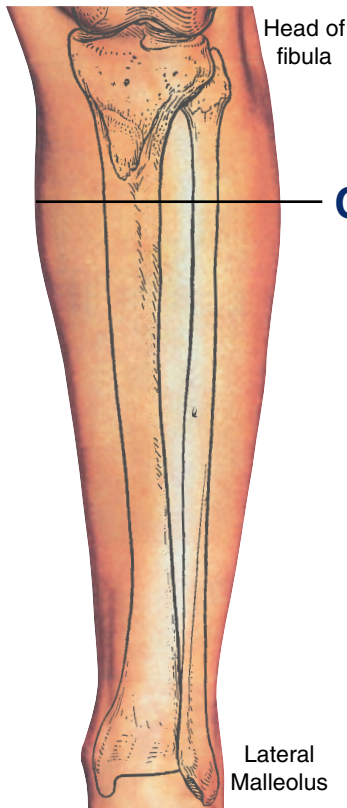
TIBIA and FIBULA left

CUT 2



This section is taken about 7-8 cm distal to the knee joint. At this level the whole of the anteromedial border of the tibia is palpable, which provides a useful guide to the relative cross-sectional diameter of the bone. The cortical component at this level is approximately 40% of the tibial diameter. The neurovascular bundle takes a more central position in the leg here,

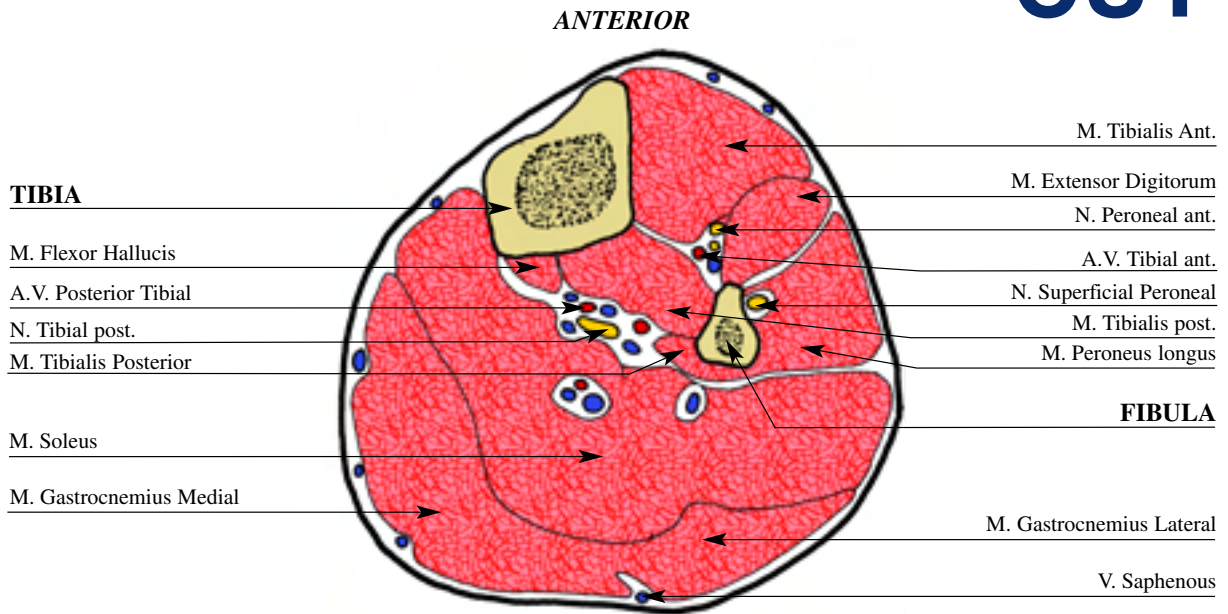
with the anterior bundle lying in close proximity to the interosseous membrane in the sagittal axis. Posteriorly the neurovascular bundle runs just posterior to the tibialis posterior muscle, again in the sagittal axis. The gastrocnemius has divided into its lateral and medial heads in the calf.



The half pin is inserted perpendicular to the subcutaneous border of the tibia on the medial aspect. The fine wire is inserted slightly obliquely to the transverse plane of the tibia to engage it in its widest portion.

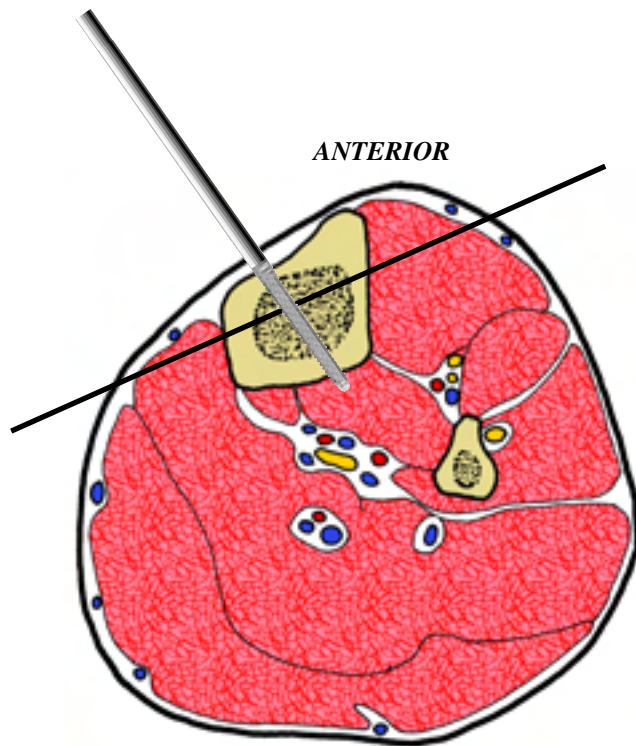
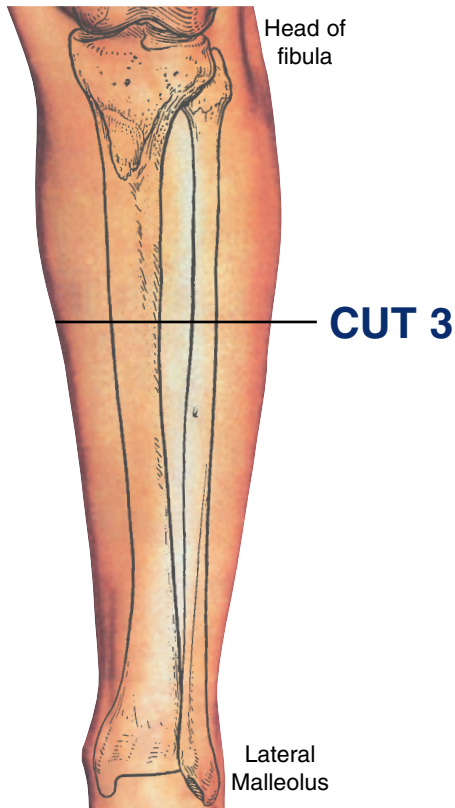
TIBIA and FIBULA left

CUT 3



This section is taken about 12 cm distal to the knee joint. The medial border of the tibia is still located in a subcutaneous position. The cortical component of the bone is gradually increasing. At this level the fibula is more triangular in cross section,

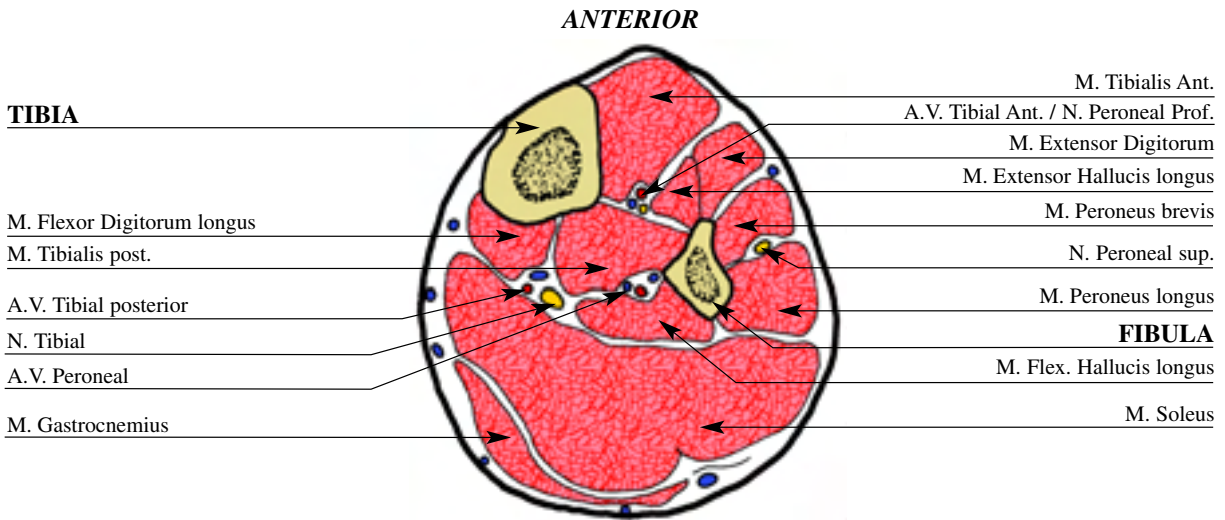
and here has its smallest diameter. Again the neurovascular bundles are relatively central, between the tibia and fibula. The anterior tibial A. and V. and the deep peroneal N. are centred on top of the interosseus membrane, in the sagittal plane.



Tibial fixation is with a medial-oblique wire and a half pin inserted into the medial aspect of the tibia perpendicular to the medial aspect.

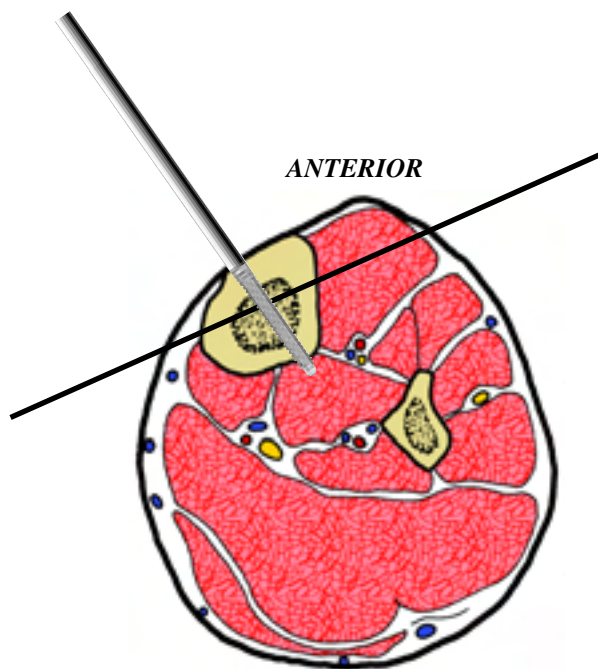
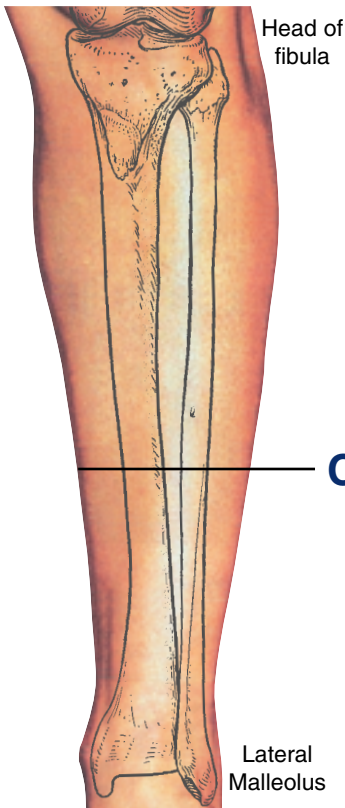
TIBIA and FIBULA left

CUT 4



This section is taken just inferior to the midpoint between the knee and ankle joints. The tibia maintains its dense cortex, now comprising up to 80% of the cross section, with a medial subcutaneous position. The fibular now takes on a more quadrangular cross section. The major neurovascular bundle is very close to the geometric centre of the leg. The anterior bundle is

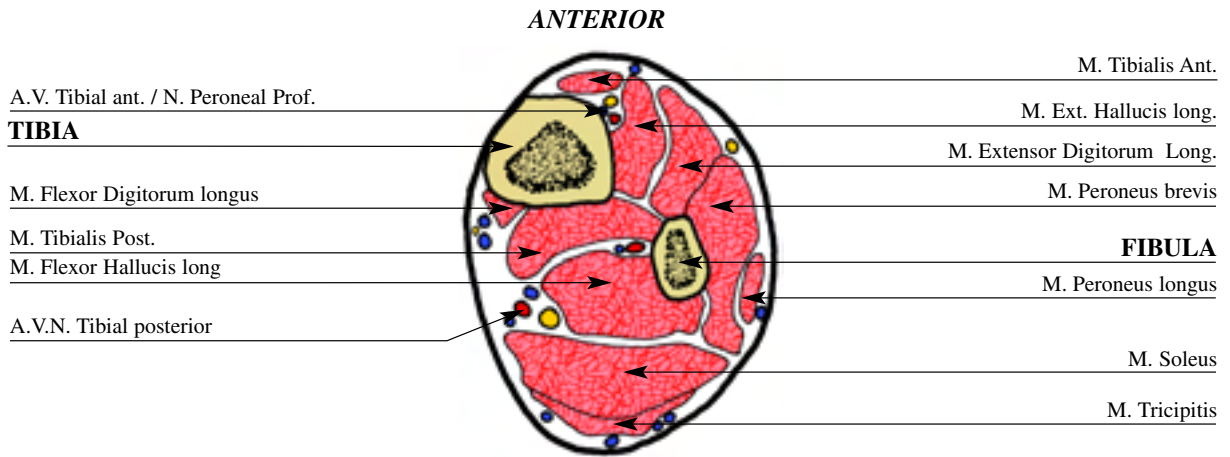
anterior to the interosseous membrane. The posterior tibial A. and V. with the tibial N. runs posterior and lateral to the tibia at the confluence of the soleus, tibialis posterior and flexor digitorum longus muscles. The peroneal vessels remain medial in relation to the fibula. The muscular contributions remain similar with the one significant difference being the increasing mass of gastro-soleus.



The insertion of the wire and half pin at this level is similar to that described for Cut Two and Three.

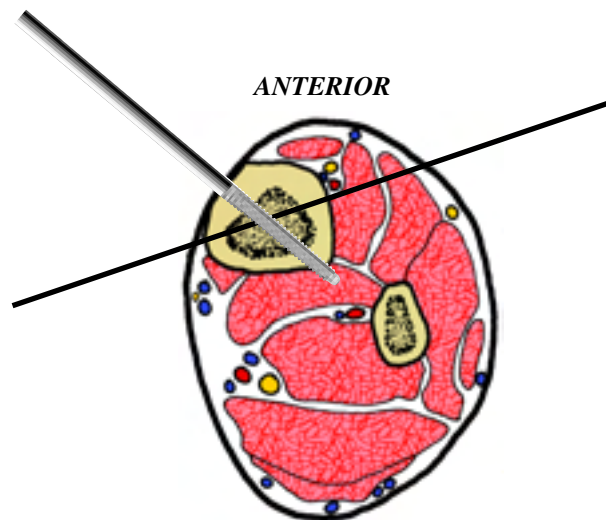
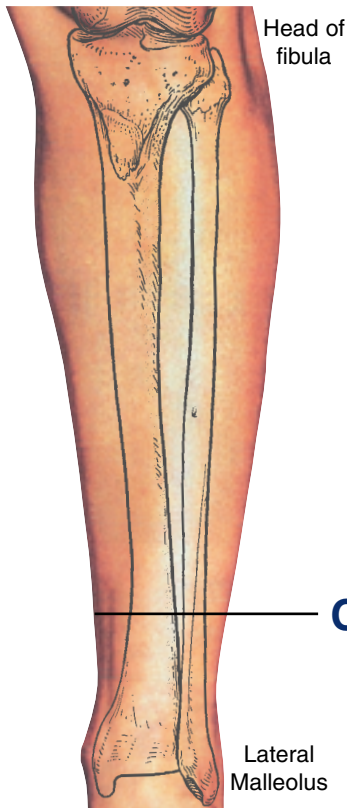
TIBIA and FIBULA left

CUT 5



This section is taken at about 12 cm from the ankle joint, where the tibia remains palpable along its medial surface, but is relatively anterior because of the increasing posterior musculature. The fibula is not usually palpable due to the peroneal muscle mass. Both bones at this level consist primarily of cortical bone. The anterior tibial A. and V. with the deep peroneal N. run in a

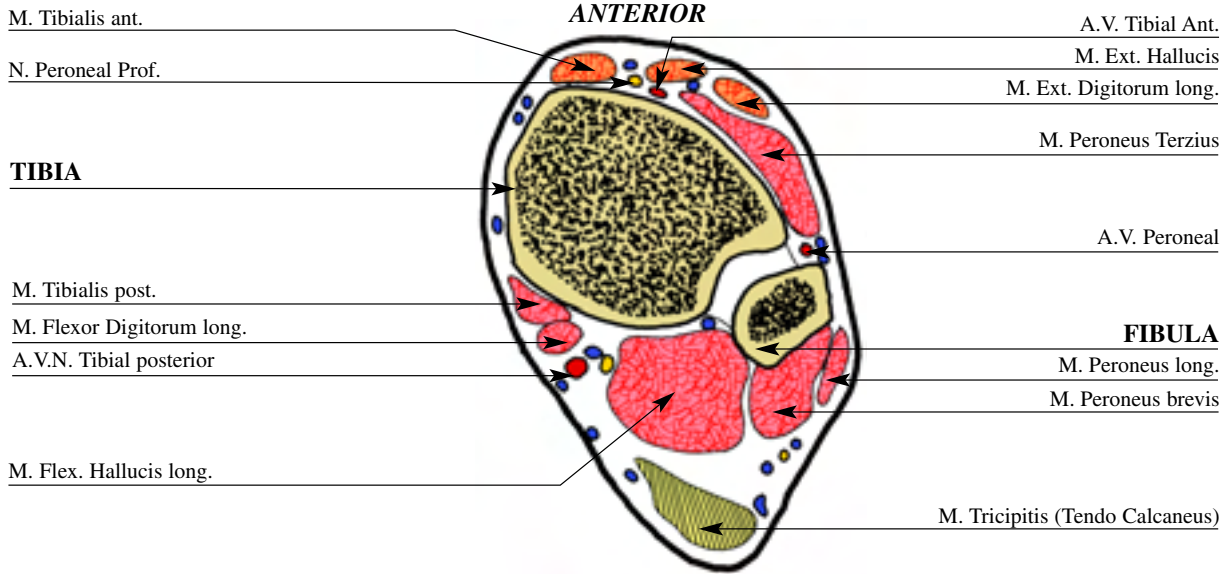
more posterior position, now lying adjacent to the interosseus membrane. The tibialis anterior and the extensor hallucis longus muscles cover these structures. The posterior tibial A. and V. with the tibial N. are located centrally between the soleus muscle and the deep posterior compartment, descending on the tibialis posterior muscle.



The wire at this level is placed almost parallel to the frontal plane of the tibia. The half pin is inserted again on the medial aspect, slightly obliquely to the wire as shown in the diagram.

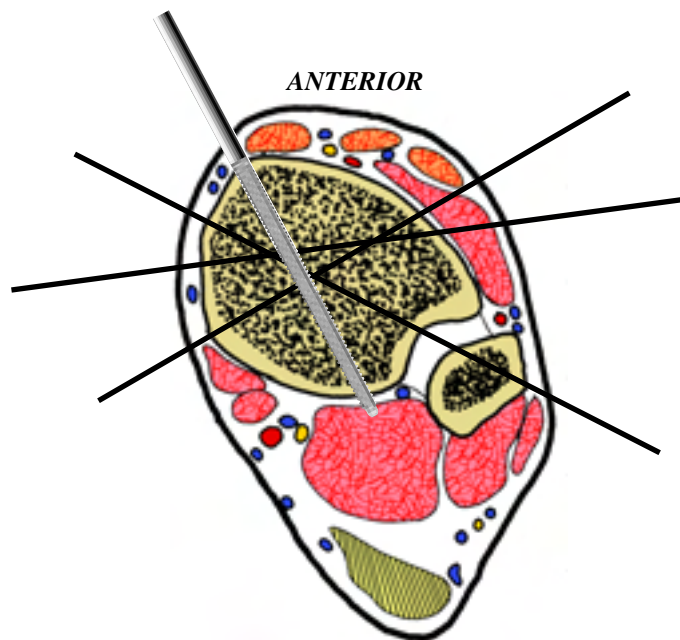
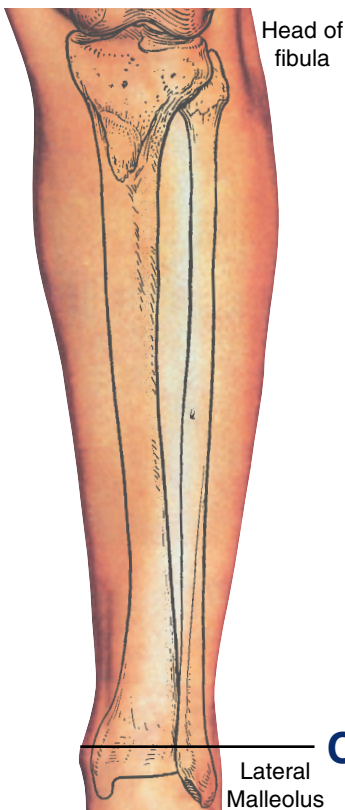
TIBIA and FIBULA left

CUT 6



The last section of the leg is taken just proximal to the ankle joint, 2 cm proximal to joint. At this level both malleoli are well-defined, palpable landmarks. The epiphyses of both the tibia and fibula are quadrangular in cross section at this level. The major tendons are also usually readily palpable in their

subcutaneous positions. The anterior tibial A. and V. with the deep peroneal N. lie between the tendons of tibialis anterior and extensor hallucis longus. The posterior tibial A. and V. with the tibial N. are located in the posteromedial quadrant, between the flexor digitorum longus and the flexor hallucis longus tendons.



A distal tibial reference wire is the initial fixation used, with a direct medial to lateral wire. The fibular stabilization takes place through a lateral oblique wire directed from posterolateral to antero medial. Additional stabilization can be achieved with a wire directed from antero lateral to posteromedial, anterior to the neurovascular bundle. Alternatively a stabilizing half pin can be inserted anteriorly, lateral to the tibialis anterior tendon. This should be done with care using a limited open technique through a small incision, which is dilated with an artery forceps. The forceps is used to displace the soft tissues and therefore protect the anterior neurovascular bundle, allowing safe pre-drilling and insertion of a 5 or 6mm half pin.

APPENDIX

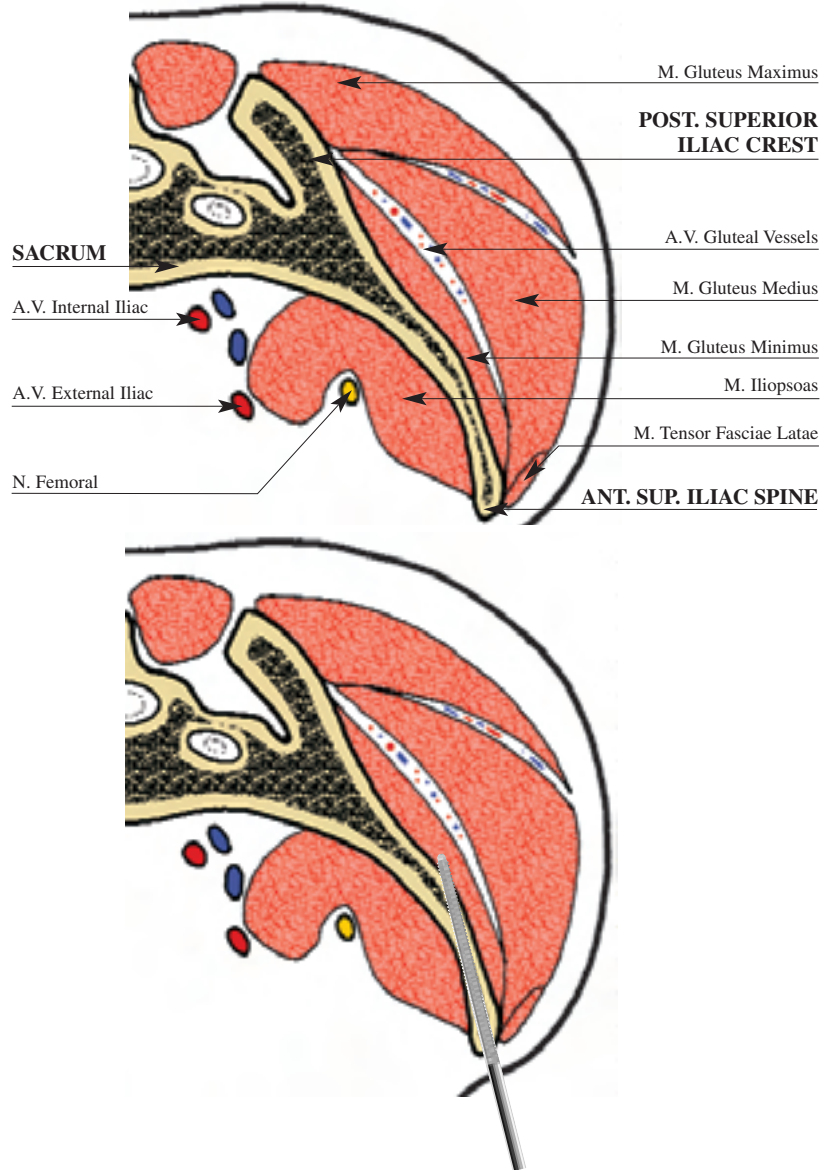
PELVIS* left

This is a transverse section of the pelvis at the level of the anterior superior iliac spine. The ASIS is a superficial structure in most patients in continuity with the iliac crest superiorly, and inferiorly with the anterior inferior iliac spine which is only palpable in thin patients. Posterior the crest becomes the posterior superior iliac spine. The ilium is a trilaminar plate with outer and inner cortices of variable thickness, containing an inner layer of cancellous bone. Inferior to the AIIS is the roof of the acetabulum and the hip joint.

The ilium is contained between two groups of muscles. The inner group comprises iliacus, which overlies the ilium and takes origin from it, and the psoas, as it descends from its origin on the lateral masses of the lumbar spine. These muscles separate the ilium from the major intrapelvic neurovascular structures and viscera. The outer muscle group is made up of the glutei, with the deepest muscle being gluteus minimus, which is closely applied to the central aspect of the ilium. Next is gluteus medius, which overlies this, followed by gluteus maximus taking a more peripheral attachment to the ilium and covering the other glutei, especially the posterior aspect. The musculature of the anterior abdominal wall takes origin from the superior aspect of the ilium. The tensor fascia lata takes origin from the outer aspect of the ilium in its anterior half, with the sartorius further anterior still, up to the ASIS. Below the AIIS is the origin of the straight head of the rectus femoris.

The lateral cutaneous nerve of thigh emerges through the inguinal ligament 1cm medial to the ASIS, which is the point the inguinal ligament attaches. From lateral to medial the femoral nerve, artery and vein, descend from beneath the inguinal ligament into the femoral triangle, the vessels entering the femoral canal within their sheath.

Transverse Section Iliac Crest



Half pins can be inserted obliquely from anterolateral to posteromedial in the line of the iliac crest, which is approximately 30° from the vertical. Care must be taken to stay at least 2 cm superior to the ASIS and to angle the pins away from this region to avoid injury to the lateral cutaneous nerve of thigh. Although a percutaneous method may be adopted, it is more difficult in larger patients. In this situation, small open incisions can be made and blunt retractors used to feel down the inner and outer tables of the ilium. This helps to give an appreciation of the orientation of the ilium. One to three pins can be inserted in this fashion after pre-drilling, spaced for maximal purchase.

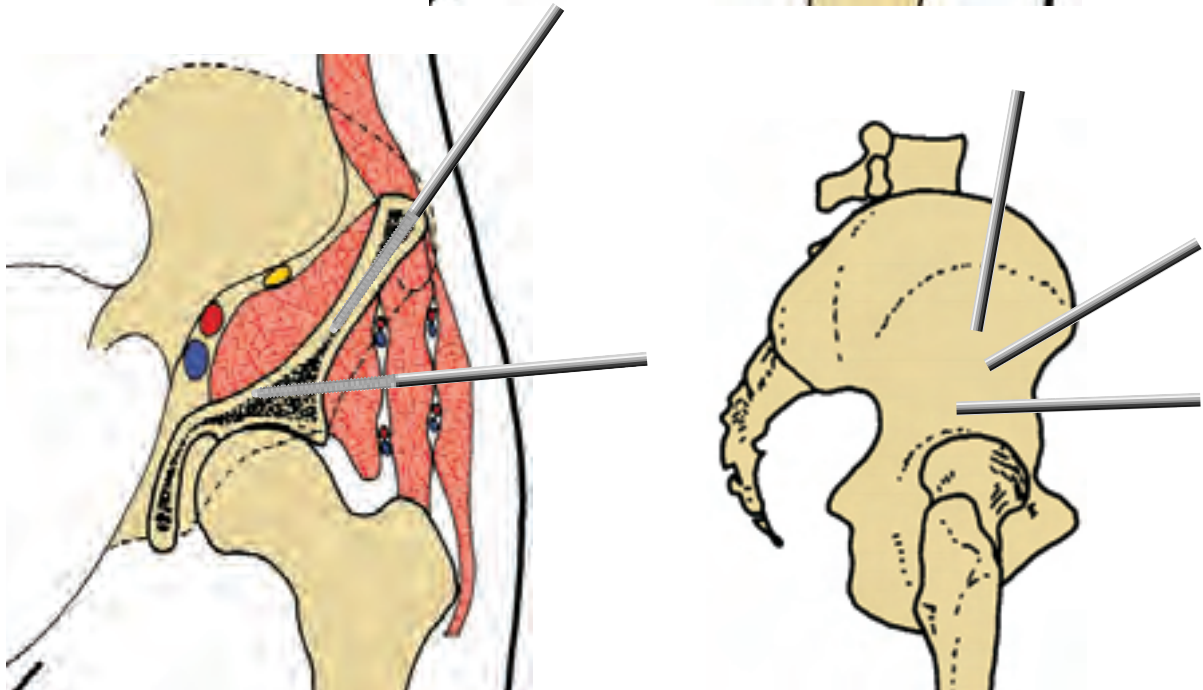
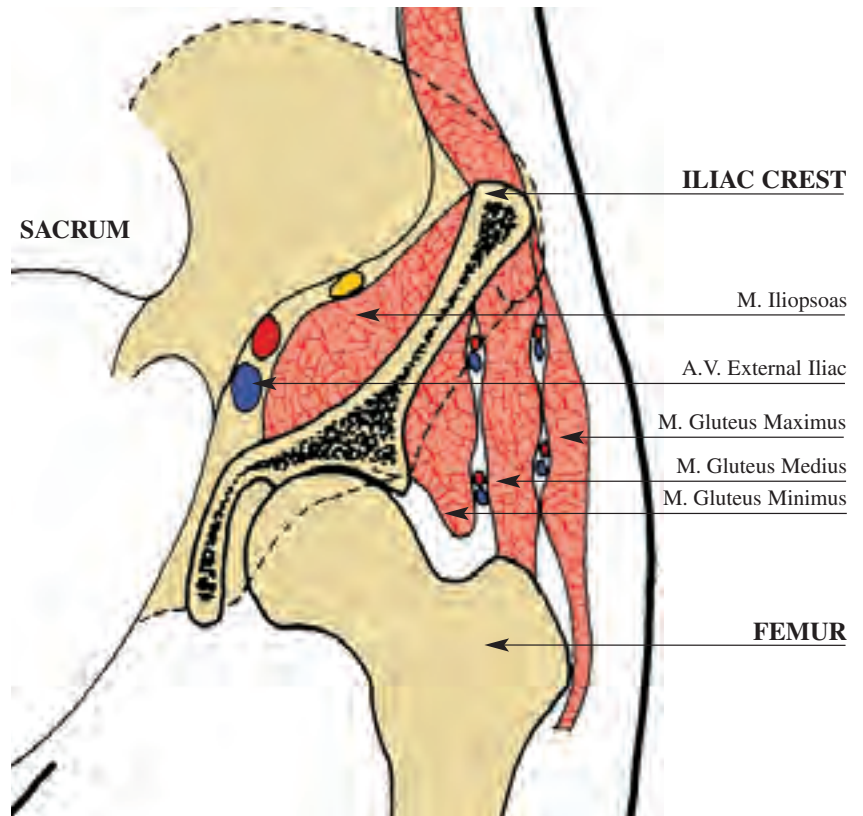
An additional anteroinferior half pin can be inserted at the level of the AIIS. This is particularly good for cross-pelvic fixation. An open technique is employed at the point at which AIIS is palpated, or seen under direct vision using fluoroscopy. A four cm incision is made in line with the iliac crest and blunt dissection is used to expose the AIIS where the straight head of rectus femoris inserts. Care must be taken with retraction to avoid excessive traction on the lateral femoral cutaneous nerve of thigh. An anterior to posterior wire can then be inserted as a guide while a plain XR is taken. Alternatively, direct fluoroscopic vision is used to ensure the line taken is adequately above the hip joint. When this is demonstrated, a straight retractor either side of the ilium can be used to guide for any pelvic obliquity as above. The hole is predrilled and a 5 or 6mm half pin is inserted. At this point the pelvis is deep and the pin can be inserted deep into the ilium heading posterior to the ischium, providing excellent fixation.

* Chapter contributed by: Dr. Richard S. Page, BMedSci, MB, BS, FRACS (Orth) - Orthopaedic Surgeon - The Geelong Hospital - Geelong, Victoria, Australia.

PELVIS left

Coronal Section

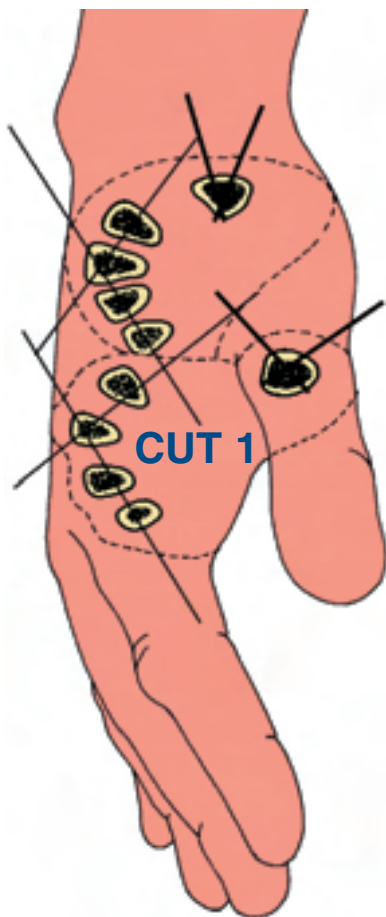
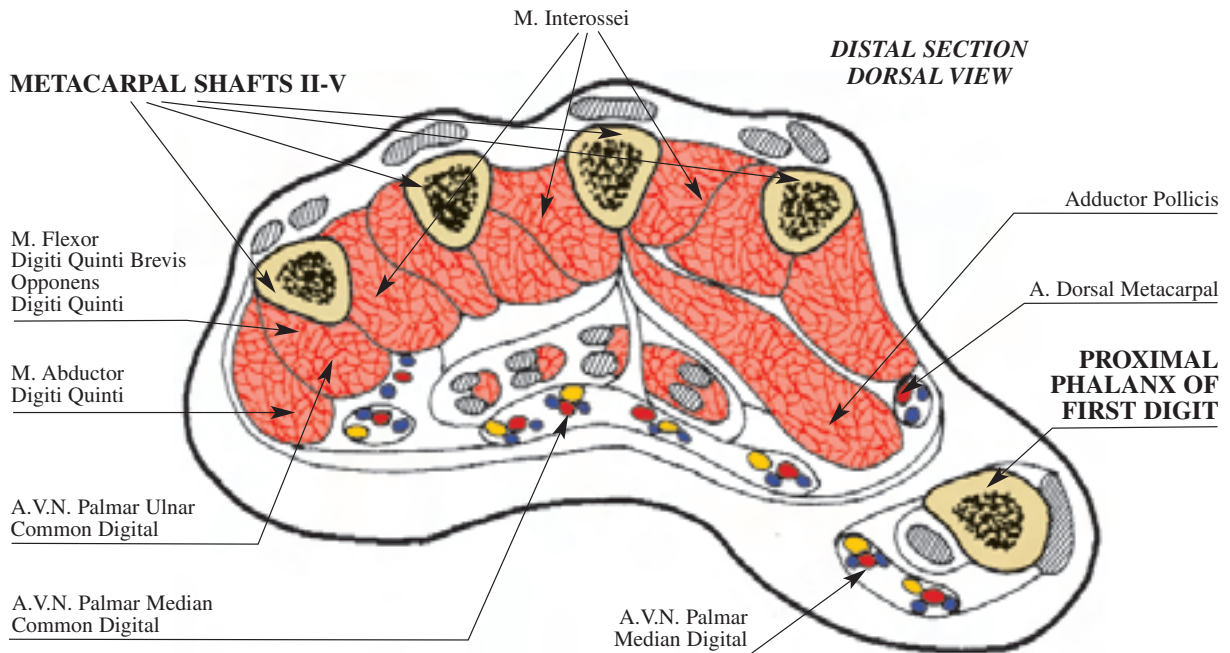
This is a coronal section taken through the hemi-pelvis at the centre of the hip joint. The acetabulum is shown in cross-section, with the thick portion of ilium above the acetabular roof leading to the quadrato plate. The bone here has both thicker cortices and a wider cancellous component. On the inner table lies the iliacus muscle, and on the outer table lie the glutei, which from medial to lateral are, the gluteus minimus, gluteus medius and gluteus maximus. Here the bony landmarks are again the ASIS, the AIIS in thinner patients, and more distally the greater trochanter. The neurovascular structures within the glutei are the superior and inferior gluteal neurovascular bundles respectively. They leave the pelvis via the sciatic foramen, the superior above and the inferior below the piriformis muscle. From here they travel in the plane between the gluteus minimus and medius muscles. The superior gluteal N. (L4-S1) supplies the gluteus minimus, gluteus medius and the tensor fascia lata, while the inferior gluteal N. supplies the gluteus maximus muscle (L5-S2). The surface marking for the superior bundle is 5cm proximal to the tip of the greater trochanter. The internal and external iliac vessels can be seen on the inner aspect of iliacus where the femoral N. and A. come to run between iliacus and psoas.



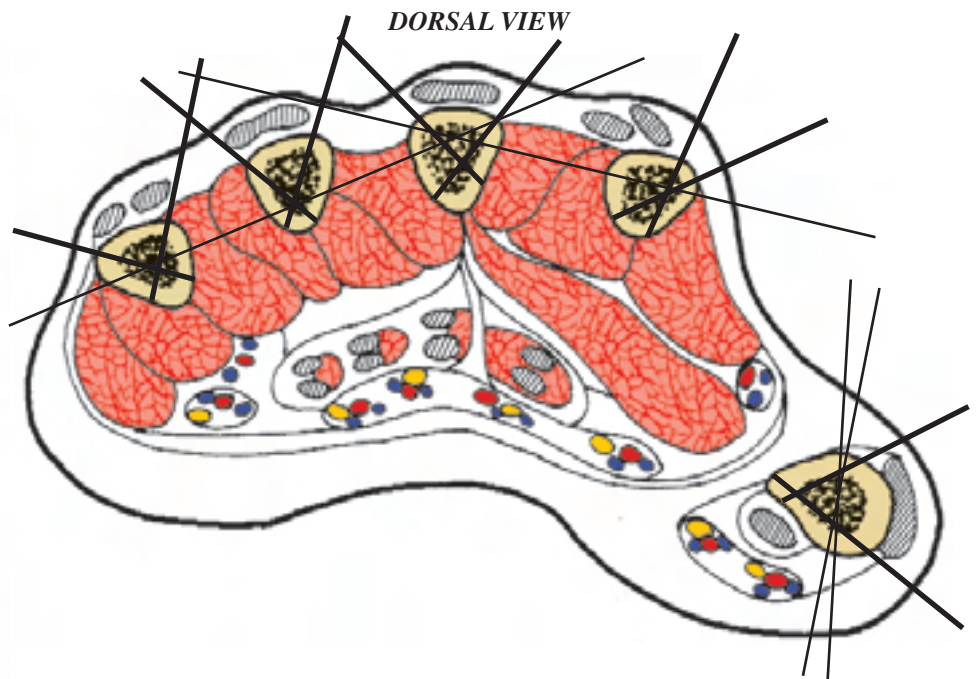
The superior iliac half pin is inserted as described above. An additional lateral half pin can be inserted into the ilium, above the hip joint. The surface point for insertion is the midpoint in a line between the ASIS and the tip of the greater trochanter. An open technique is used for insertion, a small incision is made in the skin and a straight artery forceps used to dilate the opening in line with the glutei down to the ilium. The point of the concavity where the acetabular roof meets the iliac crest is then felt. At this point guidance is either by direct vision under fluoroscopic control, or by inserting a wire at the entry point perpendicular to the lateral mass of the buttock. An XR image can then be taken to confirm the entry point and ensure the line of the pin will be clear of the hip joint. Finally a 5 or 6 mm pin is inserted in a line clear of the hip joint through a pre-drilled hole. The pelvis is wide at this point and good fixation is achieved.

METACARPAL left

CUT 1



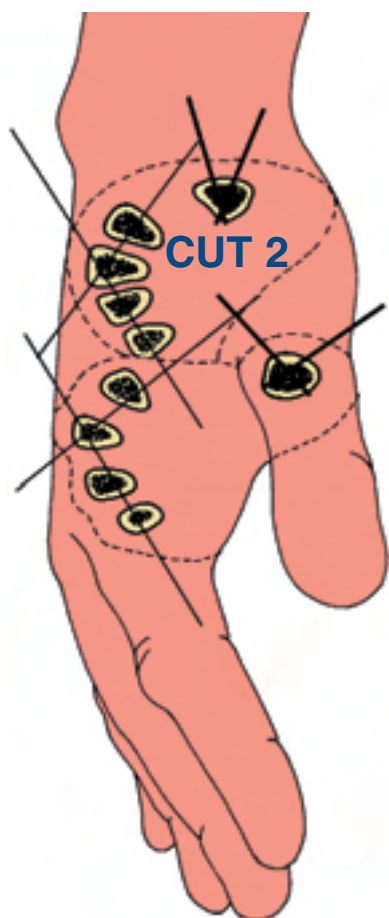
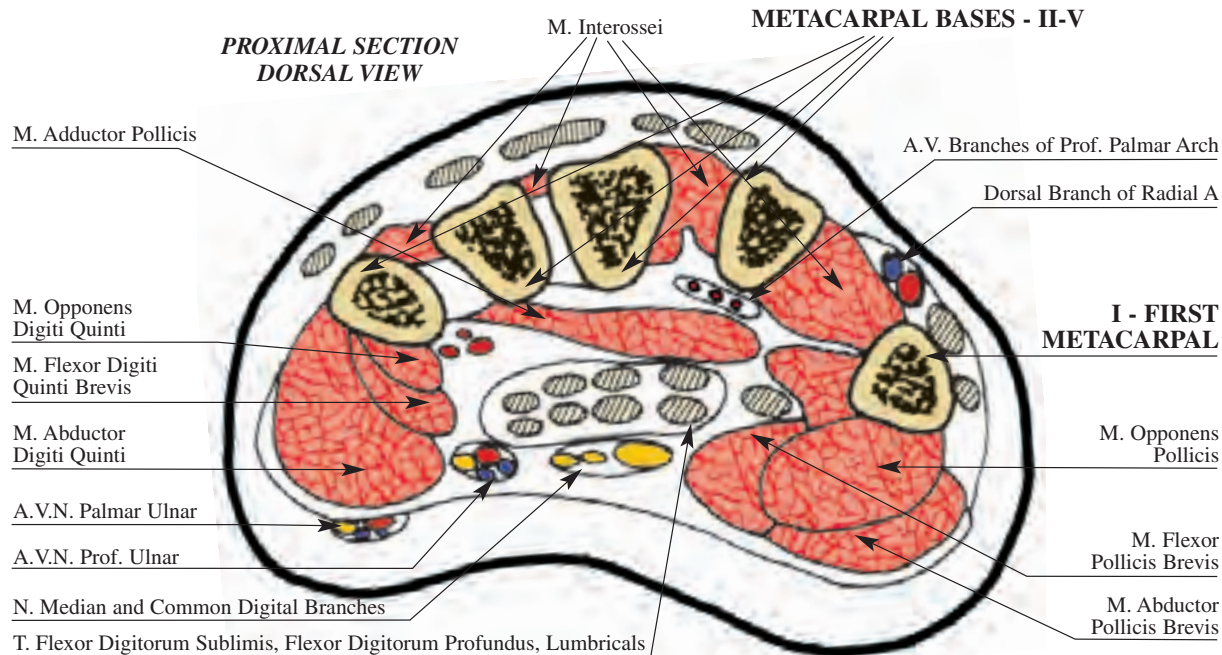
The cut is located at the base of the first metacarpal. The metacarpal 2 through 5 are located dorsally with only the extensor tendons and superficial vein posterior to them. With the exception of the first, these bones are metaphyseal and quadrangular. The flexor tendons and neurovascular structures are located centrally between the tenar and hypotenar muscle masses.



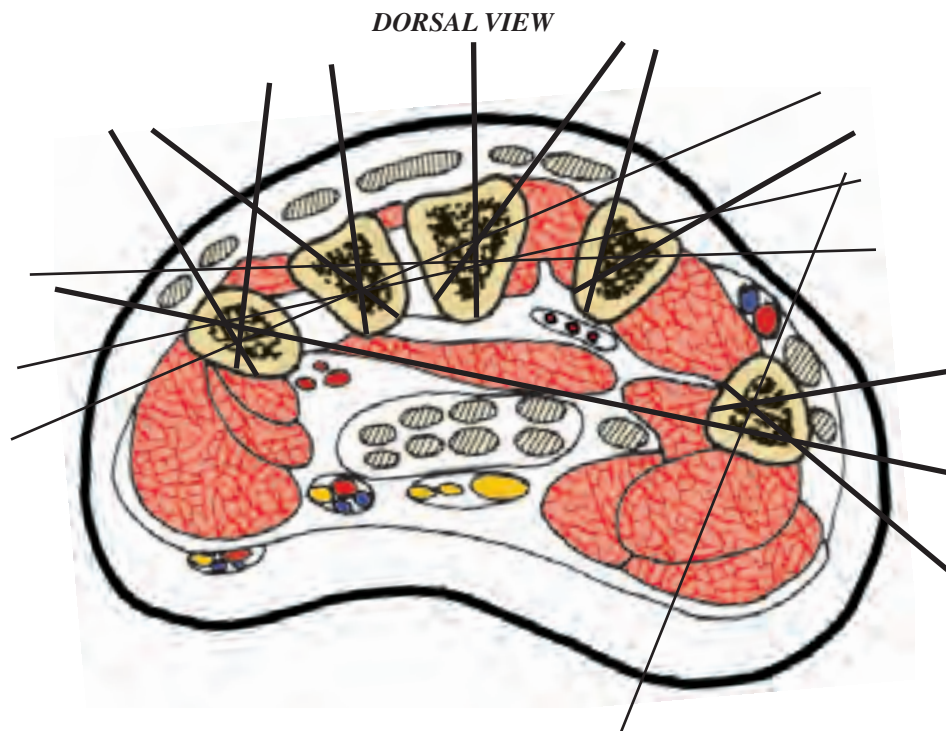
At this level it is possible to insert one wire from the fifth to the second metacarpal, one from the fifth to the third, one from the fourth to the second metacarpal, one wire can transfix the first metacarpal directed from anterior to posterior. For delta fixation a couple of 2-3 mm Steinmann pins are inserted dorsally in every metacarpal of the hand, angulated about 30° to 50°, avoiding the extensor tendons. For the first metacarpal the pins are inserted laterally. Those pins transfix both cortices of the metacarpal.

METACARPAL left

CUT 2



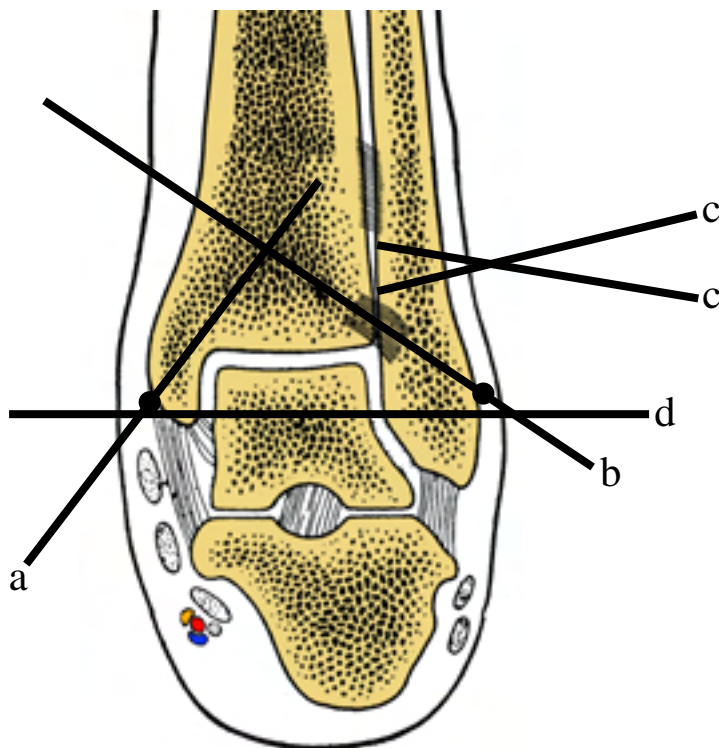
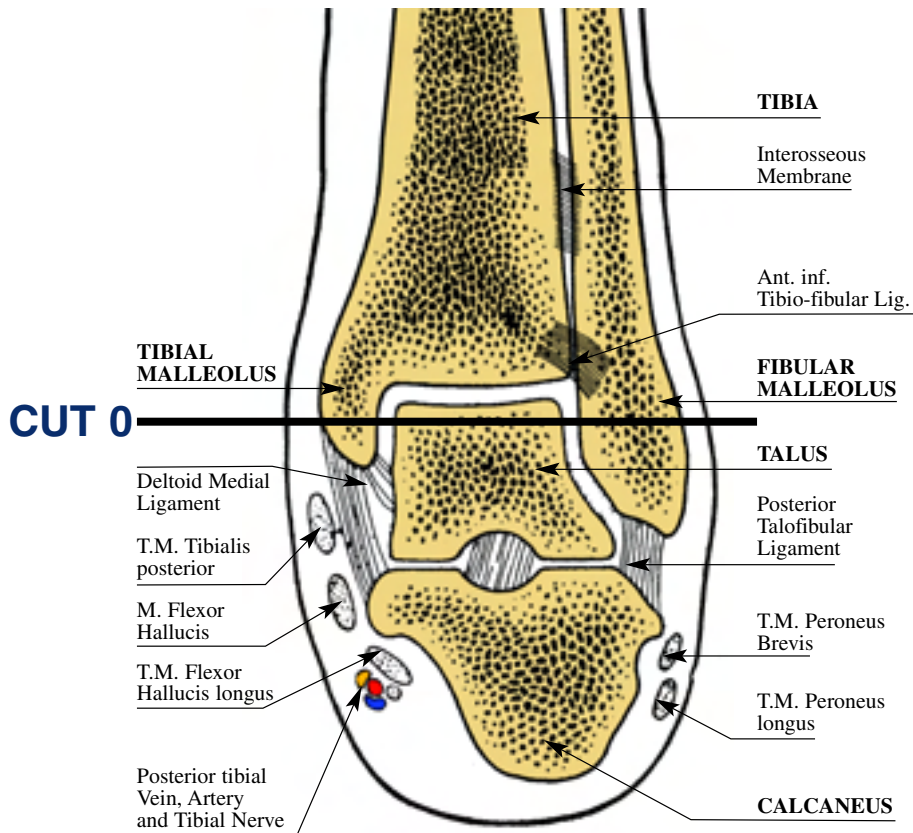
The cut is located at the base of the proximal phalanx of the thumb. The four medial metacarpals are diaphyseal and cortical, while the first is metaphyseal and quadrangular. The flexor and extensor tendons of the medial four rays lie volare and dorsal respectively. The major neurovascular structures are volar between the metacarpals and the palmar aponeurosis.



At this level the possibility of wire insertion are: one from the fifth to the third metacarpal and a second from the third to the second metacarpal. For the first metacarpal it is possible to insert one or two wires from anterior to posterior, angulated about 20°-30°. To avoid the transfixation of palmar soft tissues, it is possible to apply a delta fixation to every metacarpal: we use a 2.5, 3 mm Steinmann pins, angulated between 30° to 90°, in dorsal position for the metacarpal 2, 3, 4, 5, in lateral position for the first metacarpal.

ANKLE JOINT left

FRONTAL VIEW



Wire a: From lateral to medial, from distal to proximal: smooth wire for fixation of medial malleolar fracture; some time olive wire, to compress the fragment. It is not necessary to cross all the tibia; it is enough just to push on the wire. In this way there is not risk to damage the lateral soft tissues and the pressure to the bone is not so strong to allow the olive to penetrate into the soft bone as the malleolar cortex is very soft.

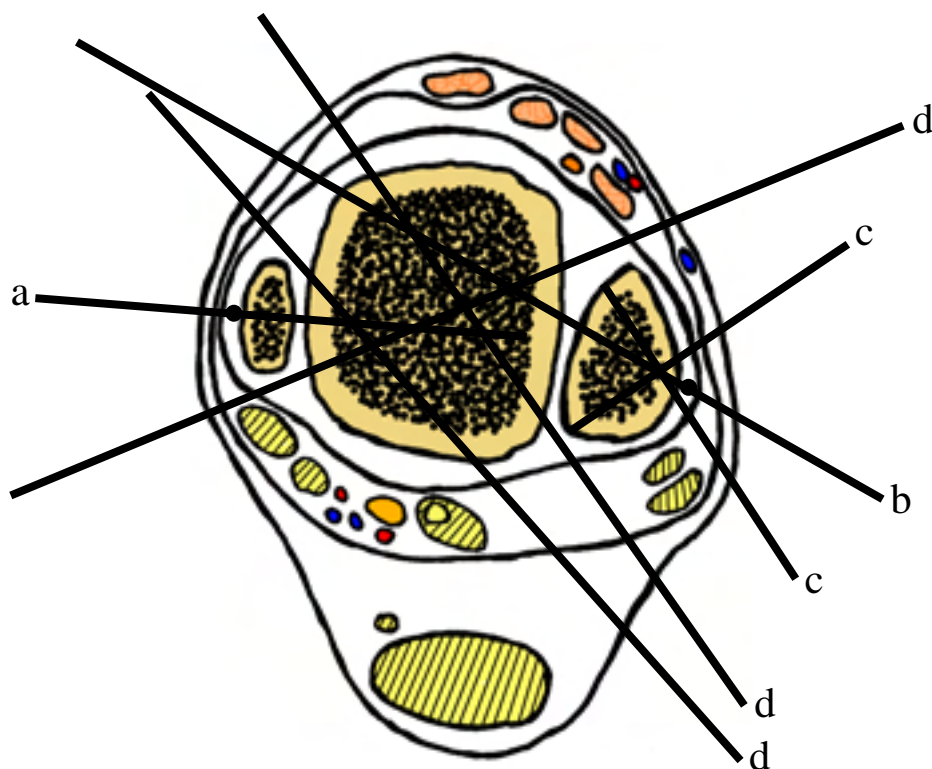
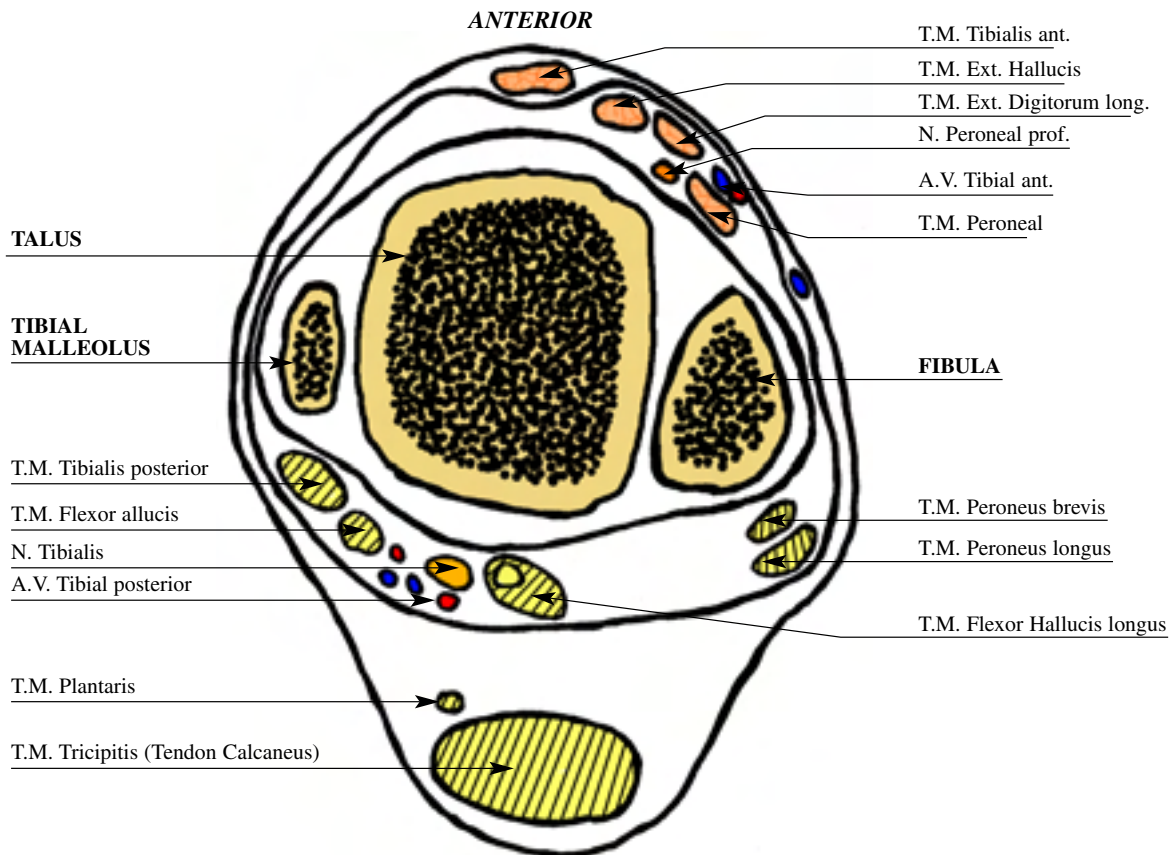
Wire b: From postero lateral to antero medial from distal to proximal for fixation of the lateral malleolus to the tibia in fracture or special case of lengthening: this wire is tensioned with post at the same ring or in different rings.

Wire c: This is half wire on half pin diameter 2 to 5 mm for fibular fixation in the need to move down the fibula or for differential lengthening of the fibula; the AP wire into the fibula has to be avoided not to damage the soft tissues.

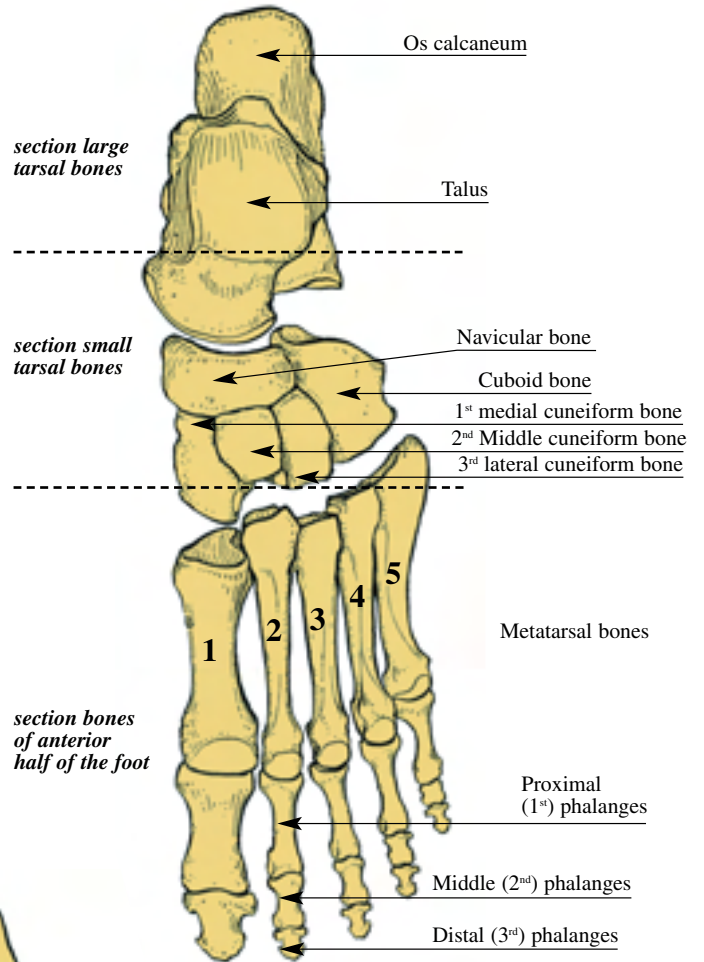
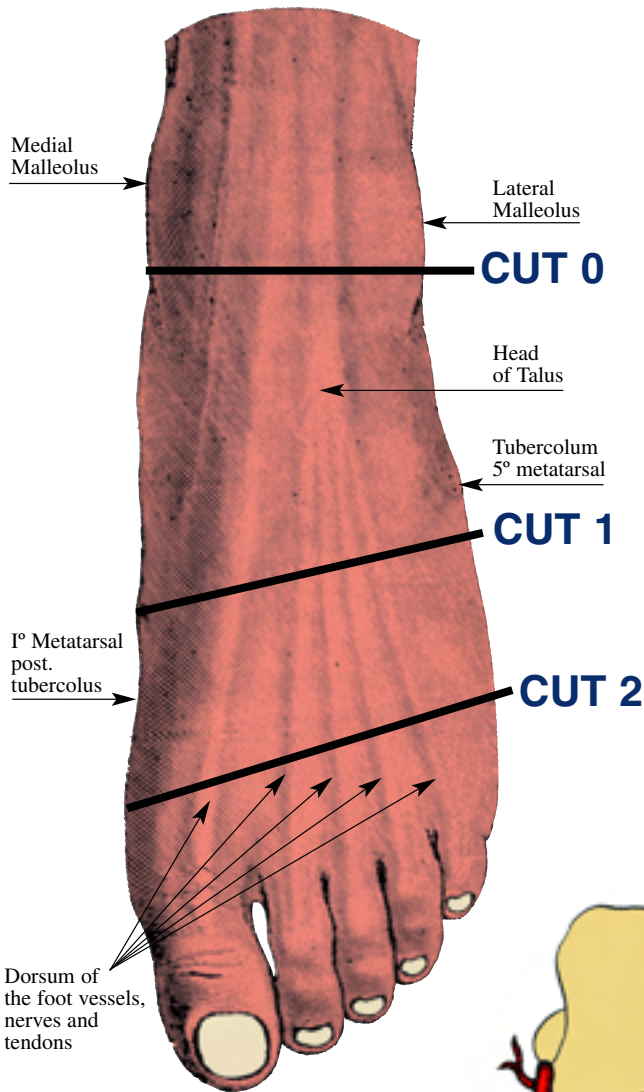
Wires d: For talus fixation in case of ankle fusion on subtalar joint fusion; the direction is from postero lateral to antero medial and from postero medial to antero lateral, tangent to the medial malleolus to avoid the neurovascular bundle.

ANKLE JOINT left

CUT 0

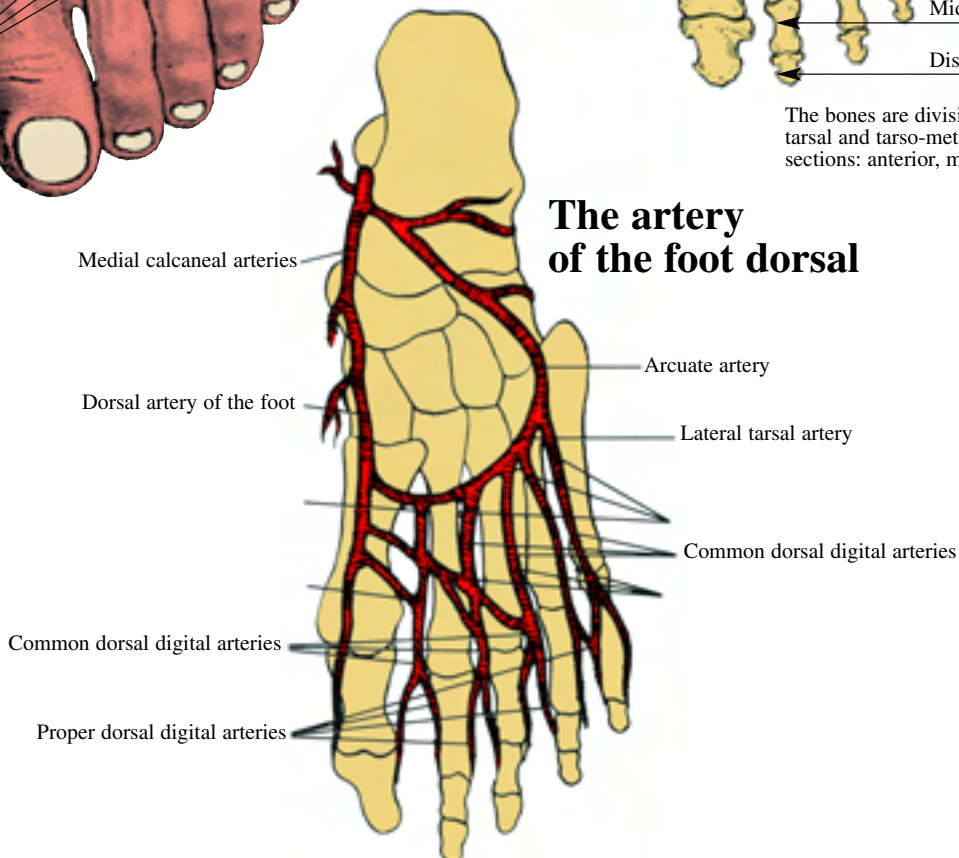


FOOT left



The bones are divisible, at the transverse tarsal and tarso-metatarsal joints, into three sections: anterior, middle, and posterior

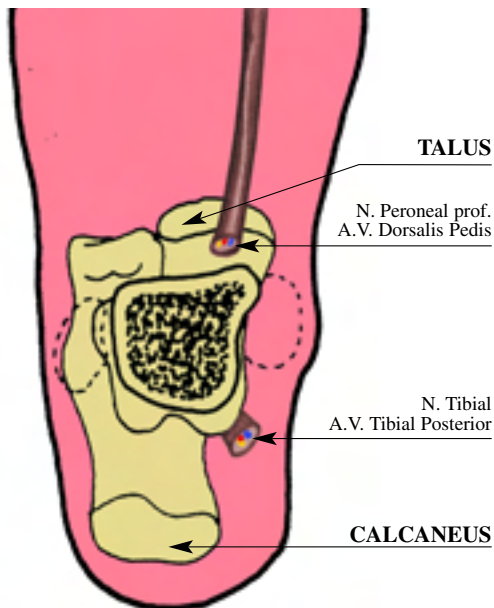
The artery of the foot dorsal



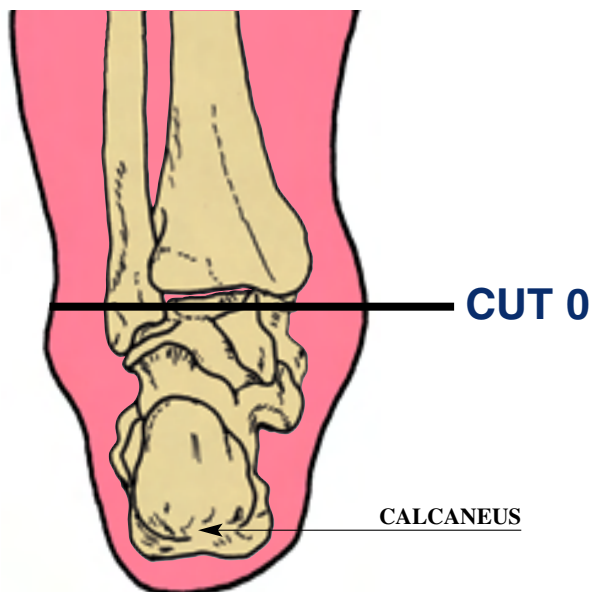
FOOT left

Hindfoot

DORSAL VIEW



POSTERIOR VIEW

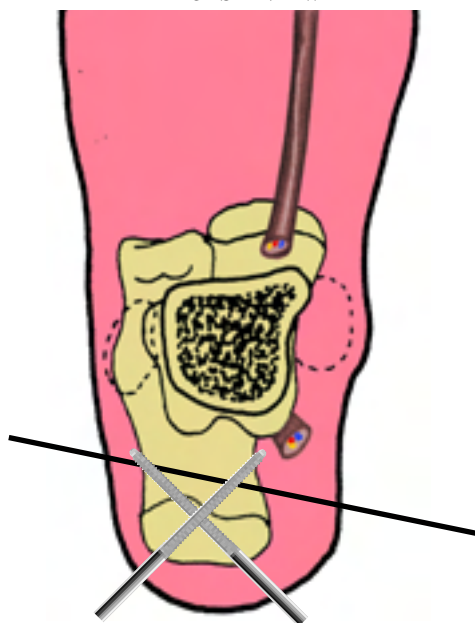


The first section is taken transversely at the level of the distal tibia. The view is from above looking down on the talus and calcaneus. Here both malleoli are readily palpable, as is the posterior tibial A. behind the medial malleolus. The calcaneus is predominantly a cancellous structure, with a thin cortical shell, particularly in older patients.

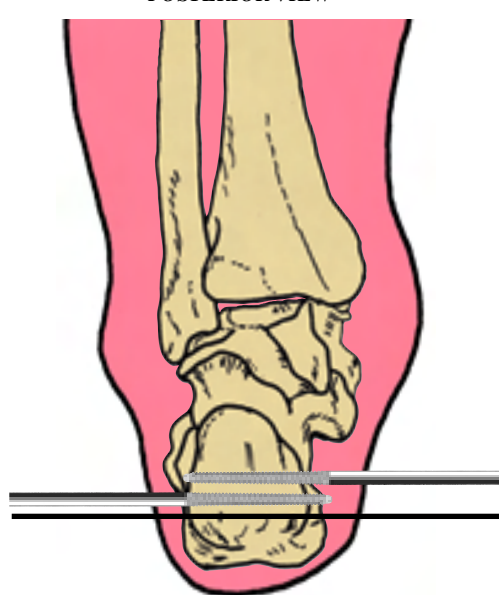
The other bony landmarks palpable at this level are the calcaneal tuberosity for the insertion of the tendo-Achilles, the medial and lateral calcaneal processes leading to the calcaneal body on either side, and on the lateral surface the calcaneo-

cuboid joint distally and anteriorly. On the medial aspect of the hindfoot the sustentaculum tali is palpable anteromedial to the distal tip of the medial malleolus. Here the medial subtalar facet is positioned above, and the plantar vessels and N. pass inferiorly adjacent to the tendon of flexor hallucis longus. Posterior to the medial malleolus runs the tibialis posterior tendon, which is closest to bone. The tendon of the flexor digitorum longus is the next posterior structure, with the posterior tibial A, V, and the posterior tibial N. running between this and the flexor hallucis longus tendon.

DORSAL VIEW



POSTERIOR VIEW

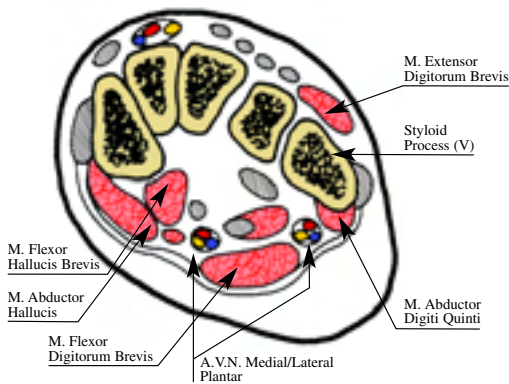


An oblique lateral to medial wire, positioned at the height of the inferior aspect of the calcaneal tuberosity, midway along the calcaneal process, provides the initial hindfoot fixation. This is placed onto a half ring, and two half pins are then inserted from the posterior aspect of the calcaneus. They are placed posterior to anterior at about 60°-90° to each other, to about 5cm from the anterior process of the calcaneus. This combination achieves optimal hindfoot stability. Alternatively crossed wires can be inserted, centred in the posterior aspect of the calcaneus. However, because of the bone structure these do not give fixation that is as good as the wire and half pin combination.

FOOT left

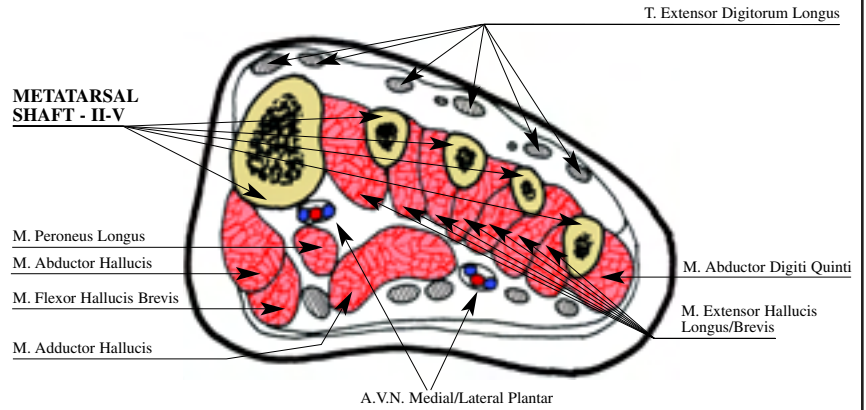
CUT 1

Midfoot (Metatarsal Bases)



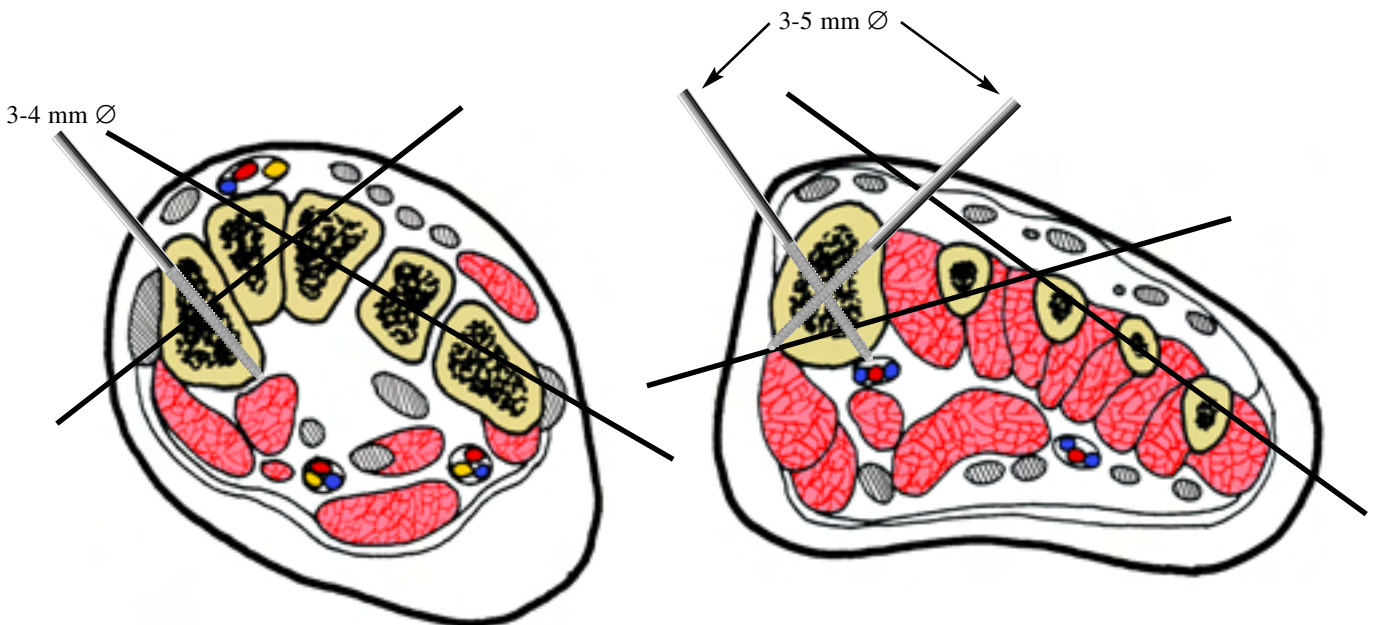
CUT 2

Forefoot



This section is taken through the metatarsal bases, about 1cm distal to the tarsometatarsal joints. At this level the metatarsals have reasonably thick cortices with a medullary core. The first metatarsal in particular has a considerable cancellous centre with thick cortices. The bases of the bones fit together in cross section like keystones in an archway, creating a stable bony arch with the highest point being around the third metatarsal. The dorsal surface is quite superficial, covered only by skin and

fascia, extensor tendons and laterally by extensor digitorum brevis. The extensor retinaculum ends distally at the level of the tarso-metatarsal joints. The tendon of extensor hallucis longus lies over the first metatarsal, the dorsalis pedis A. and deep peroneal N. over the second, the extensor digitorum longus with the brevis tendons over the third and fourth. The extensor digitorum tendon to the little toe, with that of abductor digiti mini lies over the dorsum, base and shaft of the fifth metatarsal.

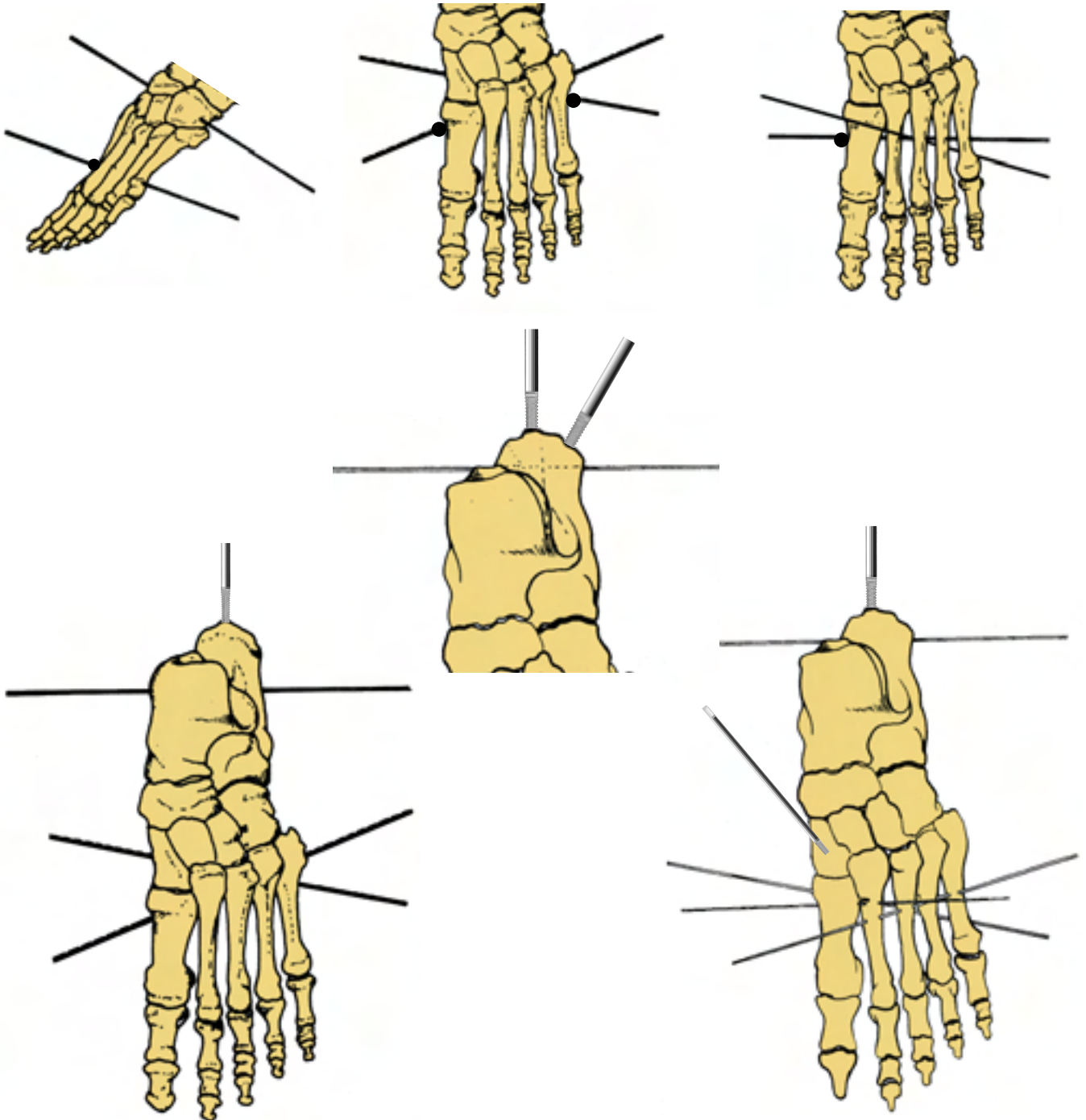


Fixation at this level is initially achieved by crossed wires. The first from the medial side, obliquely and dorsally through the bases of first, second and third metatarsals. The second wire enters from the lateral side, again obliquely and dorsally, but this one fixes the fifth, fourth and third metatarsals as shown. This fixation can be supplemented for stability using 2-3mm Steinmann pins, or in the case of the first metatarsal base using a threaded half pin. These can be inserted into the centre of the metatarsal base from the dorsal aspect of the foot. If a first metatarsal pin is used care must be taken to spread the soft tissues with an artery to protect the dorsal neurovascular structures. Alternatively, especially in the smaller foot, the navicular or cuneiforms can be used as insertion points.

Note: it is possible to use 1st to 5th metatarsal wire.

FOOT left

clinical examples



In the transosseous osteosynthesis the extended device to foot is used to increase the stability in the ankle or in the distal tibial epiphysis pathologies.

The examples can be numerous according to the different pathologies.

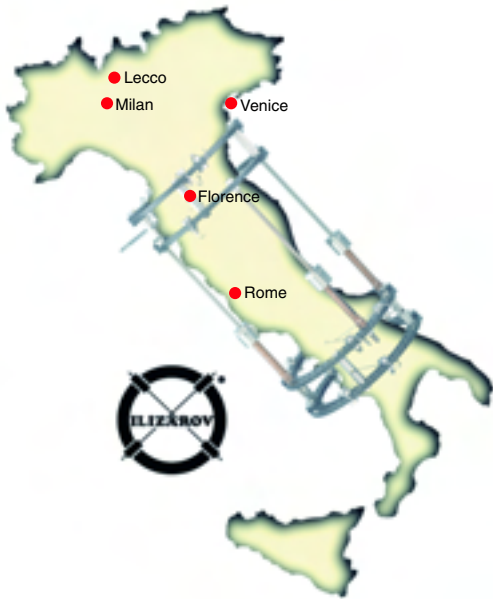The hybrid system suggests the use of 1 or 2 half-pins in the calcaneum according to the following method:

the foot construct consists of a half ring posteriorly with threaded plates extending anteriorly from each end. Another half ring is used to connect the threaded plates anteriorly over the dorsum of the foot. The frame is fixed posteriorly by a transverse wire and a 5 mm half pin. These wires/pins cross at an angle of 30-40 degrees.

Two or three wires are used to fix the midfoot and forefoot. These wires pass transversely through the tarsal bones and the bases of the metatarsals; to improve the stability one half pin is inserted perpendicular to the first metatarsus.

Fellowship opportunities

Smith & Nephew, Inc. is proud to support global Ilizarov medical education programs. Our tradition of Ilizarov is rich in education, and we continue that tradition with our mini-fellowships by working with some of the world's finest Ilizarov surgeons and educators.




Location: Lecco, Italy

Host: Prof. Maurizio Catagni

Hospital: Ospedale Alessandro Manzoni

Duration: 8-week sessions:
 January – February
 March – April
 May – June
 July – August
 September – October
 November – December

Fellows per session: 2 per session
 All lodging and travel expenses paid.
 A modest stipend is also provided.
 Lecco is located in the scenic lake country of northern Italy near Milan, and the Italian Alps.



Location: Kurgan, Russia

Host: Prof. Vladimir Shevtsov

Hospital: Russian Ilizarov Scientific Centre for Restorative Traumatology and Orthopaedics

Duration: 6 week sessions
 April 1 – May 14
 May 15 – June 30
 July 1 – August 15
 August 16 – September 30
 October 1 – November 15

Fellows per session: 4 per session.
 All lodging and travel expenses paid.
 A modest stipend is also provided.
 This program allows a once-in-a-lifetime chance to explore the unique and wonderful Siberian culture.

To apply, please contact Monica Dolbi at (901) 399-5625 or monica.dolbi@smith-nephew.com

Smith+Nephew

Leadership in Worldwide Healthcare

Smith+Nephew

Leadership in Worldwide Healthcare

Smith & Nephew, Inc. • 1450 Brooks Road • Memphis, TN 38116 U.S.A.
(901) 396-2121 • For information: 1-800-821-5700 • For orders and order inquiries: 1-800-238-7538