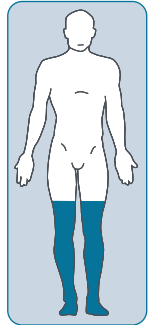


Use of ACTICOAT[◇] FLEX 3 Antimicrobial Barrier Dressing to help prevent infection in bilateral lower limb superficial burns



Presentation

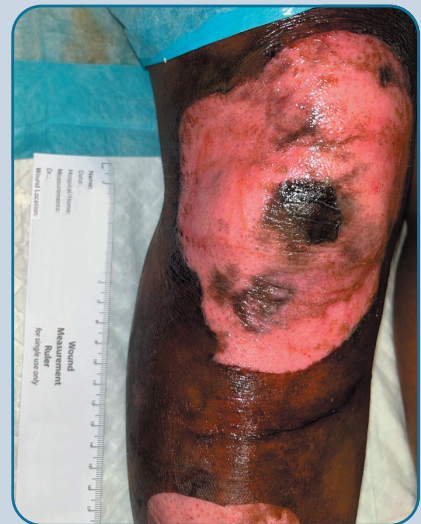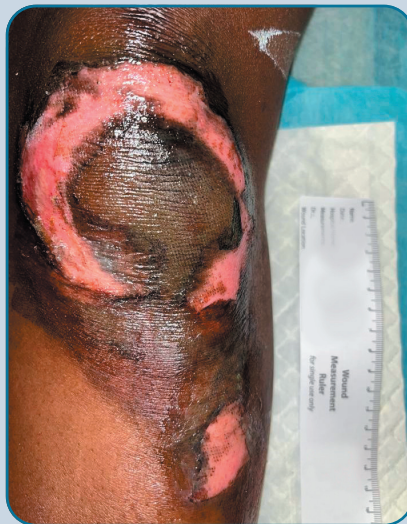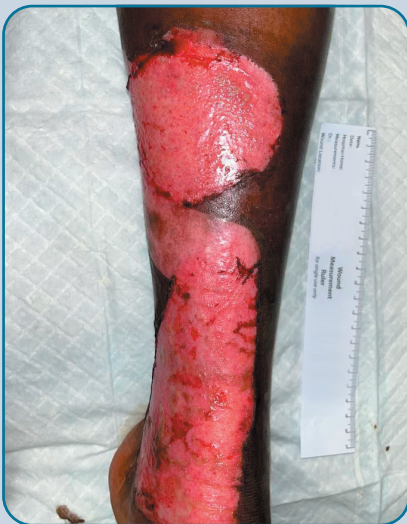At the clinic, a 50-year-old female, with no known comorbidities and whose activities of daily living include full-time care of dependents, presented with one-week old superficial burns on both lower limbs (total area: 75 x 20 x 0.25cm) caused by hot water. The burns were restricting her mobility (bending of the knees) and negatively impacting her self-esteem.

Treatment

When the burn first occurred, the patient was treated with a hydrogel dressing at the emergency room.

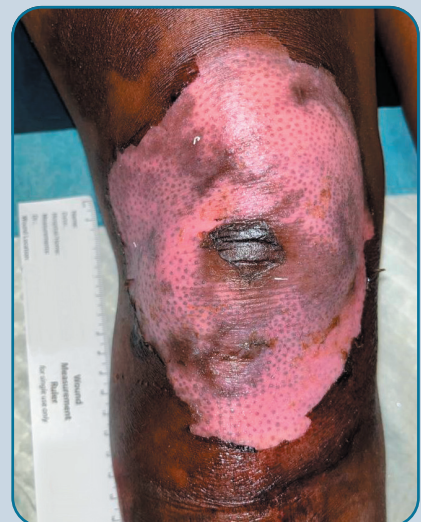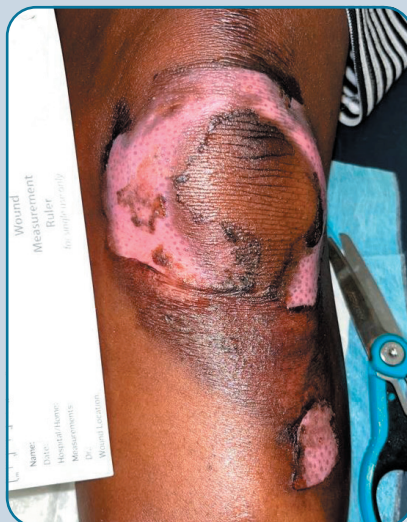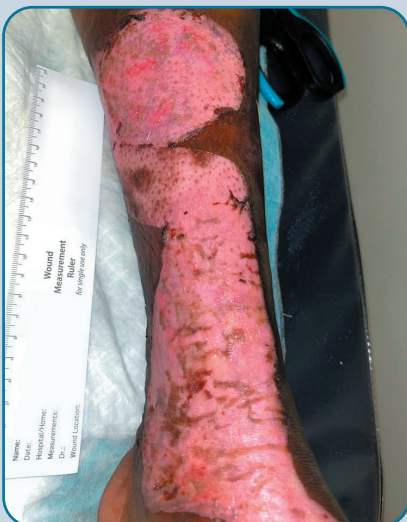Mobility was encouraged at all visits.

Visit 1: Start of treatment



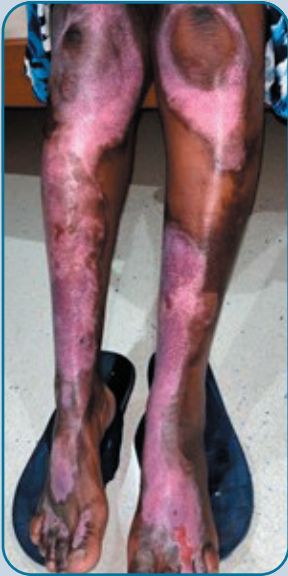The patient was seen by a nurse specialist at the wound clinic one week later who was concerned about the potential for infection and immobility related to scar tissue. ACTICOAT FLEX 3 Dressing was applied with an absorbent dressing held in place using crepe bandaging.

Visit 2: Day 3: Follow-up treatment visit

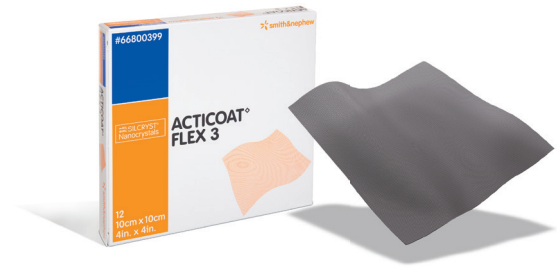

The wounds had reduced in size (total area 60 x 16 x 0cm) and ACTICOAT FLEX 3 Dressings were reapplied.

Visit 3: Day 6: Completion of treatment



The wounds had epithelialised and the patient was advised to apply emollient moisturiser twice daily to the area.



ACTICOAT[®] FLEX 3
Antimicrobial Barrier Dressing

Outcomes



Epithelialisation was achieved after 14 days without hospitalisation, signs and symptoms of infection, or disrupting the patient's family unit



The patient commented on **relief from pain and inflammation** following treatment and she **regained full mobility** allowing her to resume **daily activities within two weeks of occurrence**



Inflammation and oedema were notably reduced after application of ACTICOAT FLEX 3 Dressing which was considered by the specialist nurse to result in **faster healing** than if the product had not been used



The specialist nurse noted ACTICOAT FLEX 3 Dressing is **easy to use and conformable** around joints and digits

Summary

- Following treatment, including ACTICOAT FLEX 3 Dressing:
 - The patient was fully mobile and healed after 2 weeks, without developing signs or symptoms of infection
 - Returned to her usual routine within 2 weeks, preventing disruption of the family unit
- ACTICOAT FLEX 3 Dressing was reported by the specialist nurse to help reduce inflammation and oedema, thereby promoting healing, while being easy to use and conformable

Acknowledgements: With kind permission of M Second, Specialist Nurse, Waterfall City Hospital, Midrand, South Africa.

For detailed product information, including indications for use, contraindications, precautions and warnings, please consult the product's applicable Instructions for Use (IFU) prior to use.