

Anterolateral Stabilization

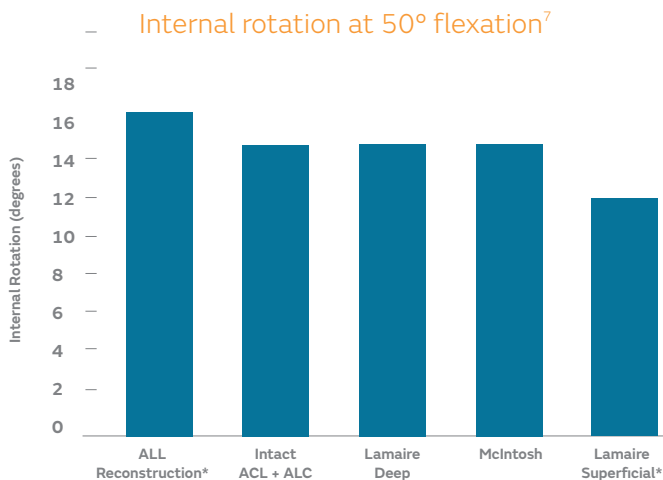
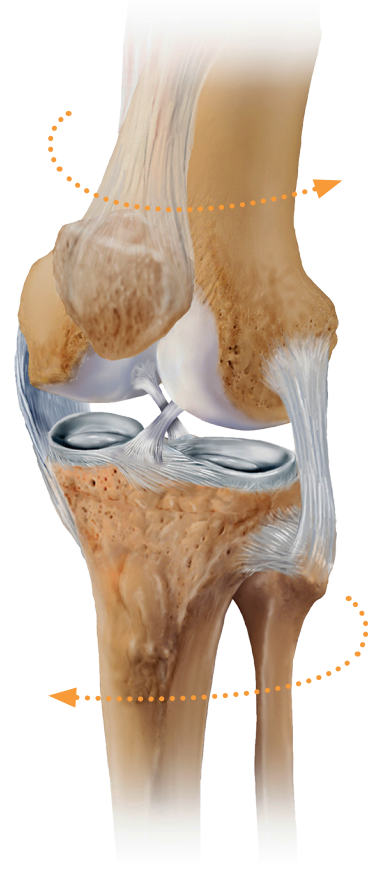Lateral Extra-articular Tenodesis (LET) to control knee rotation

Smith+Nephew

BIOSURE[◇]
REGENESORB[◇]
Interference Screw

Opportunity to improve Anterior Cruciate Ligament (ACL) reconstruction

- ACL re-rupture rates can be as high as 25% in young males¹
- Reviews of ACL reconstruction (ACLR) show that 15% have a residual 'pivot-glide' laxity (anterior translation and internal rotation)²
- Anterolateral complex is injured in up to 90% of ACL injuries³⁻⁶



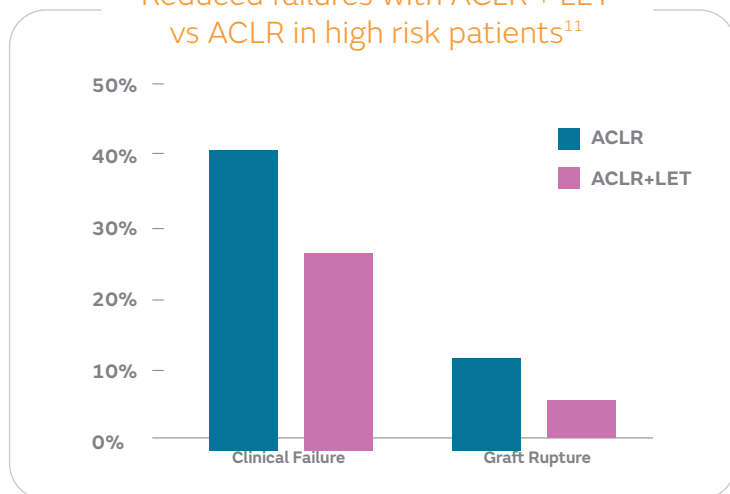
+ LET Procedures restore biomechanics**

- Deep Lemaire and McIntosh procedures restore knee kinematics (internal rotation and anterior translation) after ACL and anterolateral complex injury⁷
- LET procedures reduced rotational and translational laxity better than anterolateral ligament (ALL) reconstruction^{7,8}
- LET procedures should have a graft tension of 20N and be performed in neutral rotation to avoid overconstraint of the knee⁹

* Statistically significant difference from intact state

** Based on laboratory cadaveric studies.

Reduced failures with ACLR + LET vs ACLR in high risk patients¹¹



Patient selection is key

- Consensus groups states possible indications for additional anterolateral stabilization¹⁰:
 - Revision ACL
 - High grade pivot shift
 - Generalized ligamentous laxity
 - Young patients returning to pivoting activities
- LET can significantly reduce pivot shift and failure rates of revision ACL reconstructions from 37% to 20% and 15% to 7% of patients, respectively¹¹
- Adding LET procedures to ACLR in high risk patients significantly reduces clinical and graft failure rates from 40% to 25% and 11% to 4%, respectively¹²

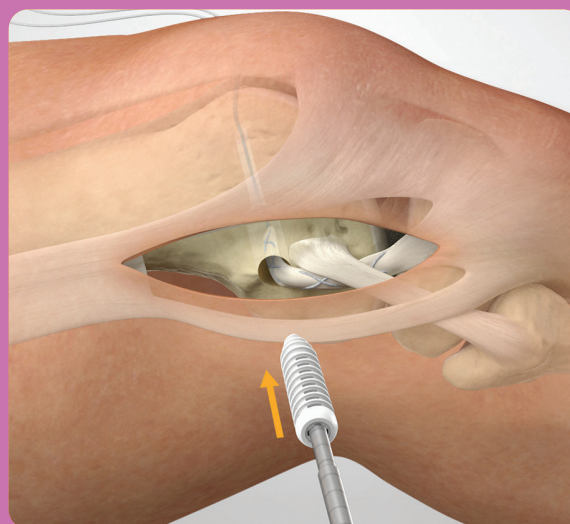
+

Fixation placement and strength with LET and BIOSURE[®] REGENESORB[®] interference screw

- LET requires only a single fixation point with an interference screw and can restore normal knee kinematics when fixed at any flexion angle⁹
- BIOSURE REGENESORB screw features advanced biocomposite material with an open-architecture design to allow for bone ingrowth*, which also provides the kind of fixation strength expected with a solid absorbable interference screw^{**13-15}
- REGENESORB material is absorbed and effectively replaced by bone within 24 months in clinical and pre-clinical studies¹⁶⁻¹⁸

* As demonstrated *in vivo*

** Compared to BIOSURE HA interference screws; as demonstrated in benchtop testing



Learn more at [ReconstructWithConfidence.com](https://www.ReconstructWithConfidence.com)

Smith & Nephew Pty Ltd
Australia
T +61 2 9857 3999
F +61 2 9857 3900
smith-nephew.com/australia

Smith & Nephew Ltd
New Zealand
T +64 9 820 2840
F +64 9 820 2841
smith-nephew.com/new-zealand

◇ Trademark of Smith+Nephew
All Trademarks acknowledged
©2020 Smith+Nephew
19480-anz V1 07/20

For detailed product information, including indications for use, contraindications, precautions and warnings, please consult the product's applicable Instructions for Use (IFU) prior to use

References

1. Feller J, Webster KE. Fate of the Young Patient Undergoing Anterior Cruciate Ligament Reconstruction: Exploring the High Re-Injury Rate. *Orthop. J. Sports Med.* 2019;4(2Suppl).
 2. Freedman KB, D'Amato MJ, Nedeff D, Kaz A, Bach BR. Arthroscopic Anterior Cruciate Ligament Reconstruction: A Metaanalysis Comparing Patellar Tendon and Hamstring Tendon Autografts. *AJSM* 2003;31(1):2-11. 3. Mansour R, Yoong P, McKean D, The JL. The iliotibial band in acute knee trauma: patterns of injury on MR imaging. *Skeletal Radiol* 2014;43:1369-1375. 4. Cavaignac E, Faruch M, Wytrykowski K, et al. Ultrasonographic Evaluation of Anterolateral Ligament Injuries: Correlation With Magnetic Resonance Imaging and Pivot-Shift Testing. *Arth* 2017;33(7):1384-1390. 5. Ferretti A, Monaco E, Fabbri M, et al. Prevalence and Classification of Injuries of Anterolateral Complex in Acute Anterior Cruciate Ligament Tears. *Arth* 2016;33(1):147-154. 6. Healto CP, Helito PVP, Costa HP, et al. Assessment of the Anterolateral Ligament of the Knee by Magnetic Resonance Imaging in Acute Injuries of the Anterior Cruciate Ligament. *Arth* 2016;33(1):140-146. 7. Inderhaug E, Stephen JM, Williams A, Amis AA. Biomechanical Comparison of Anterolateral Procedures Combined With Anterior Cruciate Ligament Reconstruction. *AJSM* 2016;45(2):347-354. 8. Spencer L, Burkhart TA, Tran MT, et al. Biomechanical Analysis of Simulated Clinical Testing and Reconstruction of the Anterolateral Ligament of the Knee. *AJSM* 2015;43(9):2189-2197. 9. Inderhaug E, Stephen JM, Williams A, Amis AA. Anterolateral Tenodesis or Anterolateral Ligament Complex Reconstruction. *AJSM* 2017;45(13):3089-3097. 10. Getgood A, Brown C, Lording T, et al. The anterolateral complex of the knee: results from the International ALC Consensus Group Meeting. *ESSKA* 2019;27:166-176. 11. Trojani C, Beaufils P, Burdin G, et al. Revision ACL reconstruction: influence of a lateral tenodesis. *Knee Surg Sports Traumatol Arthrosc* 2012;20:1565-1570. 12. Getgood AMJ, Bryan DM, Litchfield R, et al. Lateral Extra-articular Tenodesis Reduces Failure of Hamstring Tendon Autograft Anterior Cruciate Ligament Reconstruction. *AJSM* 2020;48(2):285-297. 13. S+N 2015. BIOSURE REGENESORB ovine ACL implantation study NCS250. 14. S+N 2014. Verif, BIOSURE HA Screw Fixation Strength and Insertion 15002832 Revision A. 15. S+N 2017. Verification & Validation, BIOSURE REGENESORB Interference Screws 15004843 Revision F. 16. Vonhoegen J, John D, Hägermann C. Osteoconductive resorption characteristics of a novel biocomposite suture anchor material in rotator cuff repair. *Orthop Traumatol Surg Res.* 2019;14(1):12. 17. S+N 2010. Micro-CT and histological evaluation of specimens from resorbable screw study (RS-II / OM1-08) 24-month post-implantation. Internal Report WRP-TE045-700-08. 18. S+N 2016. Healicoin Regenesorb Suture Anchor – a study to assess implant replacement by bone over a 2 year period. NCS248.