

## + Evidence in focus

Publication summary: Frykberg RG, et al. *Int Wound J* (2017)\*

## GRAFIX<sup>◇</sup> Cryopreserved Placental Membrane helped to achieve 100% wound granulation and complete wound closure in patients with complex, chronic diabetic foot ulcers (DFUs)

### + Plus points:

For the per-protocol (PP) population:

**96.3%** of patients achieved **100% granulation** with GRAFIX Membrane at Week 16

**92.3%**  
Mean DFU area reduction at Week 16 with GRAFIX Membrane

**59.3%**  
Achieved **complete wound closure** with GRAFIX Membrane

### Overview

- Multicenter, open-label, single-arm, 17-week study
- Patients had a complex DFU (longest diameter,  $\leq 15\text{cm}$ ; mean duration, 7.5 months; mean area,  $14.6\text{cm}^2$ ) extending through the dermis and into subcutaneous tissue with evidence of exposed muscle, tendon, fascia, bone and/or joint capsule
  - 68% had failed to close with  $\geq 1$  prior advanced treatment
- Patients received weekly GRAFIX Membrane for up to 16 weeks
  - Standard wound care was off-loading, weekly wound cleansing and debridement prior to GRAFIX Membrane application
- In total, 31 patients were included in the study, forming the intention-to-treat (ITT) population
  - Of these, 27 completed the entire study (PP population)

### Results

- At 16 weeks post-initial GRAFIX Membrane application:
  - 100% granulation of DFUs (primary endpoint) was achieved in 96.3% of the PP population (83.9% ITT; Figure), within a mean of 6.8 weeks (ie, 6.8 GRAFIX Membrane applications)
  - Complete wound closure was achieved in 59.3% of patients in the PP population (51.6% ITT; Figure), within a mean of 9.1 weeks (ie, 9.0 GRAFIX Membrane applications)
- In the PP population, mean percentage wound area reduction was 54.3% at Day 28, 72.8% at Week 8 and 92.3% at the end of the study

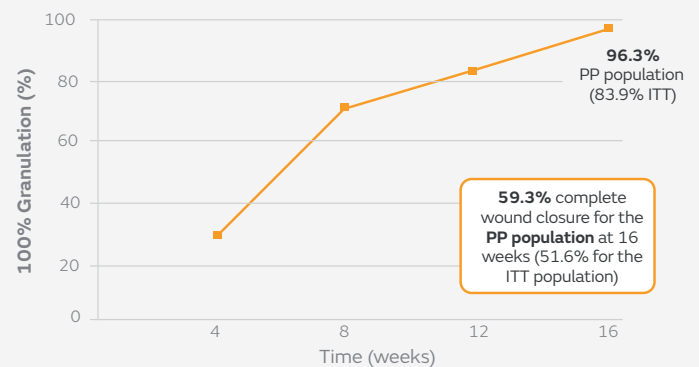


Figure. Patients (%) in the PP (n=27) and ITT populations (n=31) achieving 100% granulation and complete wound closure at 16 weeks post-initial GRAFIX Membrane application

### Conclusions

GRAFIX Membrane helped to achieve 100% granulation and complete wound closure in patients with complex DFUs that extended from the dermis into the subcutaneous tissues.

### Citation

\*Frykberg RG, Gibbons GW, Walters JL, Wukich DK, Milstein FC. A prospective, multicentre, open-label, single-arm clinical trial for treatment of chronic complex diabetic foot wounds with exposed tendon and/or bone: positive clinical outcomes of viable cryopreserved human placental membrane. *Int Wound J*. 2017;14(3):569–577.

Available from: [International Wound Journal](#)

For detailed product information, including indications for use, contraindications, precautions and warnings, please consult the product's applicable Instructions for Use (IFU) prior to use.