



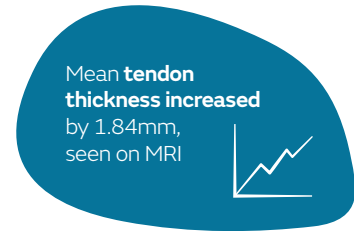
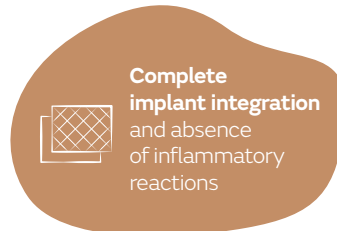
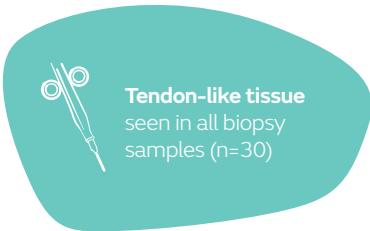
## Impact of REGENETEN<sup>®</sup> Bioinductive Implant on tendon regeneration in partial- and full-thickness rotator cuff tears: results from an independent study

Camacho-Chacon JA, Cuenca-Espierrez J, Roda-Rojo V, et al. Bioinductive collagen implants facilitate tendon regeneration in rotator cuff tears. *J Exp Orthop*. 2022;9(1):53.

Available at: [Journal of Experimental Orthopaedics](#)  

### Key points

In an independent, prospective study, patients who underwent rotator cuff repair with the REGENETEN Implant after 6 months demonstrated:



### Overview

- Independent, prospective study of thirty consecutive patients with rotator cuff tears treated with the REGENETEN Implant:
  - Partial-thickness tears (n=18) received isolated bioinductive repair
  - Full-thickness tears (n=12) received augmented double-row transosseous-equivalent repair
- Percutaneous biopsies of repair tissue were obtained at 6 months post-operatively and examined histologically (n=29)
- Magnetic resonance imaging (MRI) was performed pre-operatively and at 6 and 12 months post-operatively
- Clinical outcomes assessed pre-operatively and at 6 and 12 months post-operatively included:
  - Visual analogue scale (VAS) score (pain)
  - Standardised American Shoulder and Elbow Surgeons (ASES) score (pain, activities of daily living [ADL])
  - Constant-Murley score (pain, ADL, range of motion, strength)

### Results

- Histological appearance of a tendon in all samples obtained, with absence of inflammatory, scarring or ischaemic changes (Figure)
  - No evidence of any remaining REGENETEN Implant
- MRI demonstrated complete healing in 27 patients after 6 months; mean tendon thickness increased by 1.84mm (from 4.18mm pre-operative thickness to 6.02mm at 6 months post-operatively; p=0.001)
  - All patients showed filling of the defect at 6 months with 90% completely filled and 10% had greater than 50% of the defect filled
  - No evidence of tear propagation at 12 months
  - Neotendon was indistinguishable from native tendon on MRI in all samples at 6 and 12 months
- Patients experienced statistically significant improvements versus pre-operative values in VAS (p=0.003), ASES (p=0.001) and Constant-Murley scores (p=0.001) at 6 months post-operatively, which were sustained at 12 months

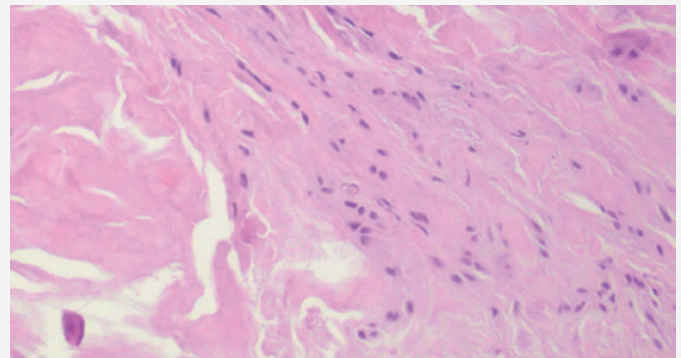


Figure. Light photomicrograph of newly regenerated host tissue at 6 months post-operatively

Figure adapted from Camacho-Chacon JA, et al. *J Exp Orthop*. 2022;9(1):53. Article licensed under a Creative Commons Attribution 4.0 International License (<https://creativecommons.org/licenses/by/4.0/>).

### Conclusions

In an independent, prospective study, rotator cuff repair with the REGENETEN Implant was shown to result in tendon-like tissue in all biopsy samples, which was indistinguishable by MRI from the native tendon, with complete implant integration into tendon and an absence of inflammatory reaction at 6 months. Complete healing was seen in 27 patients after 6 months, with a considerable reduction in defect size seen in the remaining 3 patients.